

# MIGRATORY FISH BONE IN THE THYROID GLAND

T H Foo

## ABSTRACT

*Ingested fish bone in the upper aerodigestive tract is a common emergency condition encountered in our local otolaryngologic departments. Diagnosis is usually readily made from the clinical findings and radiology. Two cases of ingested fish bone causing acute, unilateral thyroidal swelling are reported here.*

**Keywords:** *Ingested foreign body, acute inflammatory neck swelling*

SINGAPORE MED J 1993; Vol 34: 142-144

## INTRODUCTION

The most common complication following ingestion of a fish bone is its entrapment in the upper aerodigestive tract. This problem is usually easily recognised and treated promptly without much difficulty by the otolaryngologist<sup>(1)</sup>. However, the spontaneous penetration of a fish bone through the upper oesophagus and migrating through the soft tissue compartments of the neck is very uncommon<sup>(2,3)</sup>.

The consequences from such migratory bone in the neck can be serious and potentially fatal. They include deep neck suppuration with resultant abscess formation, puncturing of the carotid artery<sup>(4,5)</sup>, internal jugular venous thrombophlebitis, brachial plexus injury and embedding in the thyroid gland<sup>(6,7)</sup>.

As with the latter sequelae, an astute physician will be able to recognise that an acute, unilateral inflammatory thyroidal swelling could have been caused by a migratory ingested foreign body.

## CASE A

A 72-year-old Chinese lady swallowed a fish bone a week ago. She was referred to the otolaryngologic clinic because of persistent throat discomfort and a left neck swelling.

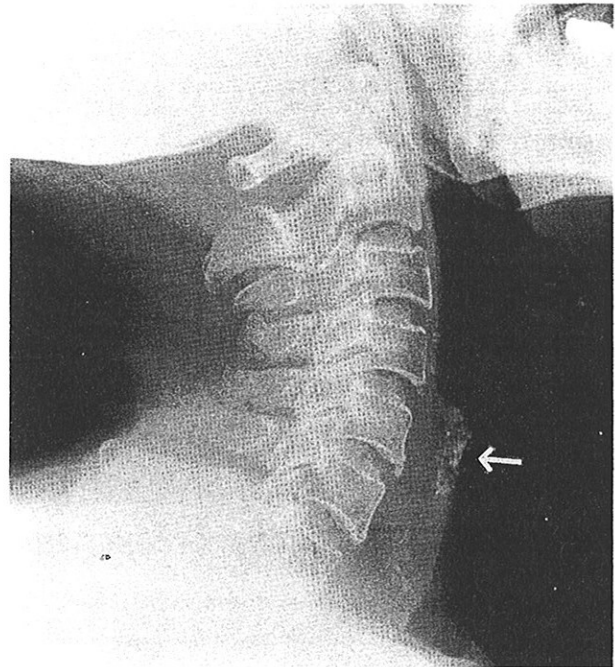
She was afebrile on examination. A left thyroid enlargement 3 x 2 cm was easily noticeable. The swelling was firm and non tender on palpation. It did not move upwards very well with swallowing. A complete examination of the oral cavity, oropharynx and hypopharynx to locate any foreign body and traumatic ulcer was negative.

Plain lateral neck radiography (Fig 1) showed a linear opacity of a fish bone located at cervical spine, C7 level lying across the upper oesophagus and upper trachea.

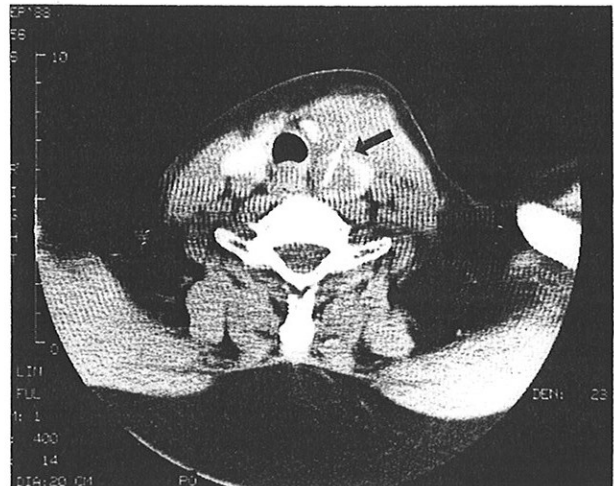
As a migratory foreign body was suspected, computerised tomograms (CT scans) of the neck and the thyroid swelling were performed. The CT scans (Fig 2) showed a straight, sharp fish bone embedded in the left thyroid lobe surrounded by soft tissue swelling suggestive of an intralobal abscess.

Oesophagoscopy was done to assess the upper aerodigestive tract and exploration of the left neck swelling followed. The intrathyroidal lobal abscess was drained and the embedded fish bone removed. Post-operatively she was treated with parenteral antibiotics (Flagyl, 500 mg 8-hourly and Rocephin, 1 gm 12-hourly) intravenously for 3 days and then orally for a week with Flagyl (400 mg 8-hourly) and Ampicillin (500 mg 6-hourly). The bacteriological study of the pus from the intrathyroidal abscess was negative for bacterial growth. No anaerobic study was done. The patient was discharged on the

**Fig 1- The plain lateral neck radiograph showing a linear opacity of a foreign body at the C6 - C7 level that appears outside the upper oesophagus.**



**Fig 2 - Axial CT scan of the neck showing a fish bone embedded in the left thyroid gland surrounded by soft tissue swelling suggestive of an intralobal abscess.**



Department of Otolaryngology  
Singapore General Hospital  
Outram Road  
Singapore 0316

T H Foo, MBBS, FRCS  
Senior Registrar

5th post-operative day.

### CASE B

A 66-year-old Chinese lady gave a history of swallowing a fish bone 3 days before. She consulted her doctor because of persistent left sided throat discomfort. The attending otolaryngologist thought the ingested foreign body had been dislodged and passed down the oesophagus as the clinical and radiological examinations were negative. However, she was given another review date but she defaulted.

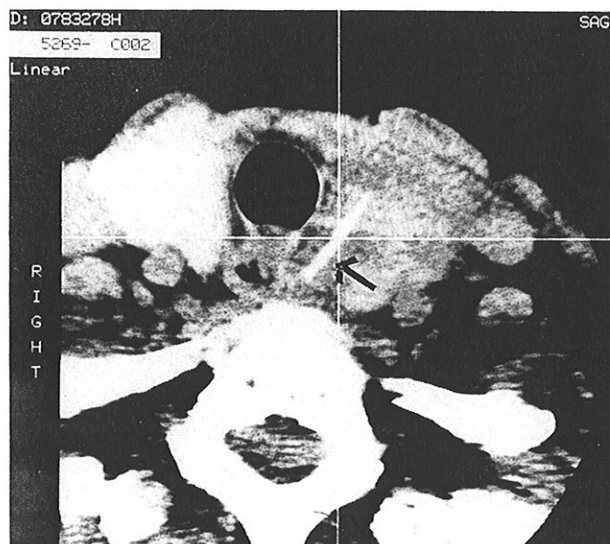
Almost 7 weeks later, she returned to be attended by another otolaryngologist with the complaint of a painful left neck swelling. Clinically, she was afebrile and there was a diffuse left thyroid lump measuring 2 cm in diameter with tenderness on palpation. Re-examination of the upper aerodigestive tract was done and again with negative findings for foreign body in the area. Review of her previous lateral neck radiograph did not show any radio-opaque fish bone. In view of recent past history of ingested fish bone, a migratory foreign body was suspected. She was then admitted for further management.

Computerised tomogram of the neck swelling (Fig 3) showed a straight, pointed fish bone that had perforated the left anterior oesophageal wall at thoracic spine, T1 level and penetrating into the left thyroid lobe. Marked soft tissue reaction was seen in the thyroid gland.

An operative procedure was planned. Rigid oesophagoscopy was done first and this showed a small punctured wound with granulation tissues seen at the level of the cricopharynx but no foreign body was detected. Neck exploration followed and a left partial lobectomy of the thyroid was done to remove the deeply embedded fish bone. No abscess was seen but the thyroid gland involved was swollen and inflamed.

She was treated post-operatively with parenteral antibiotics Rocephin (1 gm bd) and Flagyl (500 mg 8-hourly) for a

**Fig 3 - Axial CT scan of the neck showing a fish bone that has penetrated through the anterolateral oesophageal wall and migrated into the left thyroid lobe.**



week. The culture swab from the operative site was sterile. The patient recovered uneventfully after the surgery.

### DISCUSSION

The typical migratory bone as illustrated in Fig 4 is a sharp, straight and pointed object about 2.5 cm in length. It can cause

spontaneous penetration of the oesophagus and migrate out, posing dangers to the adjacent structures. Usually, it is a fish bone or a broken bone chip derived from chopped up meat bone. The feature of this "danger" bone had been illustrated in the two cases reported here and also elsewhere<sup>(3,6,7)</sup>. Such sharp, pernicious looking bone is usually ingested accidentally and most of the time passes down the gastrointestinal tract without causing any harm.


Entrapped bones in the upper oesophagus are usually triangular or "T" shaped. They may puncture the wall of the viscera but will usually be retained at the cricopharynx until they are safely removed endoscopically. Their retention within the lumen of the viscera can be explained by the mere shape of the bone, thus preventing them from migrating out into the neck or thoracic cavity. Secondly, the expulsion force of the cricopharyngeal contraction or the upper oesophageal peristalsis are far too weak to move such usually larger and irregular shaped bone out<sup>(2,8,9)</sup>. However, the typical migratory bone, if for any reason, is held up in the lumen of the upper or mid oesophagus, it will become a potentially "dangerous" bone. In the two cases reported and the others reviewed, no abnormality like oesophageal stricture was detected. However, there have not been any further oesophageal manometric studies done for these patients. The mechanics of spontaneous penetration and migration of such bone have been explained briefly by two previous authors, Ong GB and Jemerin EF<sup>(2,6)</sup>.

The incidence of such migratory foreign body is about 1% in a local series reviewing 218 patients admitted for surgical management of ingested foreign body. The migration of such bone into the neck spaces certainly results in higher morbidity, cost and longer hospitalisation stay to the patient. A surgical neck exploration will be required. The bone becomes a focus of sepsis causing deep neck space suppuration forming retropharyngeal or lateral neck space abscesses. The spreading suppuration in the tissue planes of the neck can further complicate matters with upper airway obstruction and in late cases with mediastinitis from infection tracking down through the root of the neck.

Mortality from such migratory bone has been well documented. A patient died from a puncture of the left carotid artery by such migratory bone and thromboembolism<sup>(5)</sup>. The much rarer complication from such similar "killer" bone in the thoracic cavity causes higher fatality from oesophago-aortic fistula or mediastinal abscess<sup>(2)</sup>.

The public awareness in our local population of the dangers of ingested foreign bodies had been made repeatedly over the years in our local news. The isolated cases of mortality had not been able to deter the local public from changing their eating habits. The cultural eating habits include preference for

**Fig 4 -The "danger" bone - typical shape and size of such migratory bone.**



bony fish or fish head to filleted fish; chopped chicken or meat bones which contain broken bone chips; use of chopsticks which leads to loss of discrimination of bone chips in the food especially in people wearing large denture; and the common habit of speaking and rushing through a meal. Daily occurrence with patients seeking treatment for ingested foreign bodies testify the fact that this problem will stay for a long time here.

Fortunately, the complications that arise from ingestion of foreign body are mostly minor, and major complications are usually uncommon<sup>(1,5,10)</sup>. The possible high morbidity and mortality from such serious complications can be prevented by the clinicians who have to deal with these patients at primary health care level or in the hospital. It will be important to emphasise two salient points:

- a) Though morbidity and mortality from ingested foreign body are generally negligible, fatal complications do occur.
- b) Early surgical intervention remains the pillar of treatment to reduce further disastrous consequences: endoscopy to remove impacted bone, surgical exploration of the neck or thoracic cavity, when necessary, to retrieve embedded bone and drainage of consequential abscess.

The clinical awareness of foreign body problem has been

well complemented with the modern day medical technology like CT scan, bacteriological control, safe surgical and anaesthetic techniques making the management of its complication far more easier and safer.

#### ACKNOWLEDGEMENT

I would like to thank Ms Lily Lum for helping me to type this manuscript and to Dr Loh Leong Eam for his advice.

#### REFERENCES

1. Leong HK, Chan RKC. Foreign bodies in the upper digestive tract. Singapore Med J 1987;28:162-5.
2. Nandi P, Ong GB. Foreign body in the oesophagus: Review of 2394 cases. Br J Surg 1978;65:5-9.
3. Strieder JW. Surgery of the oesophagus. N Eng J Med 1950;243:445-54.
4. Clerf LH. Foreign bodies in the air and food passages: observations on end-results in a series of nine hundred and fifty cases. Surg Gynae Obstet 1940;70:328-39.
5. Yang CY. The management of ingested foreign bodies in the upper digestive tract: A retrospective study of 49 cases. Singapore Med J 1991;32:312-5.
6. Jemerin EF, Arnoff JS. Foreign body in the thyroid following perforation of oesophagus. Surgery 1949;25:52-9.
7. Muhanna AA, Chra KAA, Dashti H, Behbehani A, Al-Naqeeb N. Thyroid lobectomy for removal of a fish bone. J Laryngol Otol 1990;104:511-2.
8. Nagler R, Spiro HM. Serial esophageal motility studies in asymptomatic young subjects. Gastroenterology 1961;41:371-9.
9. Richter JE, Wu WC, Johns DN et al. Oesophageal manometry in 95 healthy adult volunteers. Variability of pressures with age and frequency of "Abnormal" contractions. Digestive Dis Sci 1981;32:583-92.
10. Ngan JHK, Fok PJ, Lai ECS, Branicki FJ, Wong J. A prospective study on fish bone ingestion: Experience of 358 patients. Ann Surg 1989;211:459-62.

## THE IXTH BIENNIAL SCIENTIFIC MEETING

*organised by the Asian Pacific Association  
for the Study of the Liver*

Date: 27 - 29 January 1994  
Venue: Kuala Lumpur, Malaysia

**For further enquiries, please contact:**  
The IXth Biennial Scientific Meeting APASL  
Suite 11, Ground Floor  
Pantai Medical Centre  
No 8 Jalan Bukit Pantai  
59100 Kuala Lumpur  
Malaysia  
Tel: (03) 2821753 or 2821777  
Fax: (03) 2821753