

# A RARE WANDERING SPLENIC CYST REMOVED WITH LAPAROSCOPIC ASSISTANCE

C K Kum, S S Ngoi, P Goh, Y S Lee, R Gopalan

## ABSTRACT

*This is a report of the first case of a true cyst arising in a wandering spleen. Laparoscopic splenectomy was attempted. The spleen was mobilized under laparoscopic control and the cyst aspirated. Dissection of the pedicle was technically feasible. However, the procedure was aborted due to uncontrollable bleeding from a moderate-sized artery. Although the whole procedure was not completed laparoscopically, laparoscopic assistance facilitated extirpation of the spleen through a 5-cm oblique left iliac fossa incision in a minimally invasive fashion.*

**Keywords:** splenic cyst, wandering spleen, laparoscopically assisted splenectomy

SINGAPORE MED J 1993; Vol 34: 179-180

## INTRODUCTION

This is a report of the first case of a true solitary cyst arising in a wandering spleen. Although a multicystic wandering spleen<sup>(1)</sup> and a wandering spleen with multiloculated cysts<sup>(2)</sup> have been reported previously, a true solitary epithelial cyst arising in a wandering spleen has never been reported. Laparoscopic splenectomy was attempted.

## CASE REPORT

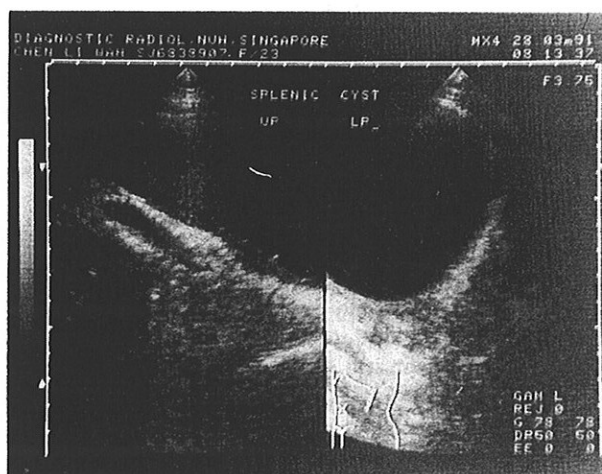
A 23-year-old Chinese woman presented with a history of bilateral leg swelling after a long aeroplane flight one month prior to admission. This was associated with lower abdominal fullness. Several weeks later, she was admitted for acute urinary retention and required catheterisation. Following catheterisation, a large suprapubic cystic mass measuring about 12-cm in diameter was found. The distinctive feature of the mass was its mobility. At various times, it had been felt in the left lumbar region, left iliac fossa and in the pelvis. There was also bilateral pitting edema of the legs up to the knees. The provisional diagnosis was that of an ovarian cyst compressing on the pelvic veins.

CT of the abdomen and pelvis revealed a large cystic mass of uncertain origin in the pelvis. The intra-abdominal organs were reported to be normal but the spleen was noted to be displaced from its anatomical position. Ultrasound revealed a smooth anechoic cyst that is related to the spleen in the superior aspect (Fig 1); and a diagnosis of a cyst arising from a wandering spleen was made.

Laparoscopic splenectomy was planned. We felt that a

wandering spleen would be eminently suitable for laparoscopic removal as it is only attached by a long pedicle without further attachments to the other organs. The patient was put under general anaesthesia. Pneumoperitoneum was created with carbon dioxide introduced via Veress needle through a subumbilical incision. A 11-mm trocar was inserted subumbilically and the laparoscope introduced. There was a large cyst arising from a very mobile spleen attached only by its pedicle to the tail of the pancreas. A 5-mm trocar was inserted in the left iliac fossa and a suction apparatus introduced. The cyst was punctured and its clear contents aspirated. Another 11-mm trocar was then inserted in the right iliac fossa to facilitate dissection of the pedicle. The pedicle was dissected with a combination of sharp dissection and diathermy. Blood vessels were doubly clipped with titanium clips and cut. Midway through the procedure, significant bleeding from a moderate size artery was encountered that could not be safely controlled. The spleen was brought down to the left iliac fossa and externalized through a 5-cm oblique abdominal incision. The pedicle was ligated and the spleen excised. Although the splenectomy could not be completed laparoscopically, laparoscopic aspiration of the cyst and stabilization of the spleen with laparoscopic forceps in the left iliac fossa facilitated splenectomy through a small incision.

**Fig 1 - Ultrasound showing an anechoic cyst related to the spleen in the superior aspect**



Histological examination revealed a true epithelial cyst arising from the lower pole of the spleen (Fig 2). Lining the cyst was columnar epithelium with some cilia. The patient made an uneventful and speedy recovery and was able to return to work in a week.

Department of Surgery  
National University Hospital  
Lower Kent Ridge  
Singapore 0511

C K Kum, FRCS  
Registrar

S S Ngoi, FRCS  
Consultant

P Goh, FRCS  
Consultant

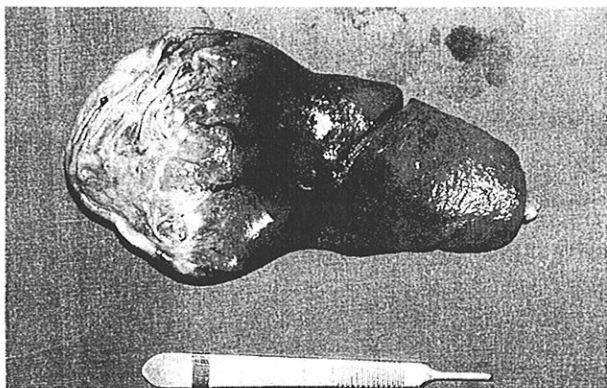
R Gopalan, FRCS  
Consultant

Department of Pathology  
National University Hospital

Y S Lee, FRACP  
Professor

Correspondence to: Dr C K Kum

**Fig 2 - Gross specimen showing a collapsed solitary cyst at the inferior pole of the spleen**



## DISCUSSION

This case report is unique in several aspects. Firstly, this is probably the first case of a true solitary epithelial cyst arising in a wandering spleen to be reported. Both true cysts and wandering spleens are so rare that concurrence in the same patient is remarkable. It was possible that a cyst developed early in the childhood of this patient and that the weight of the undetected cyst led to stretching the abnormal development of the splenic attachments<sup>(3)</sup>. However, the complete lack of attachments to the other organs suggests that the spleen was developmentally loose and that the cyst probably appeared in an already wandering spleen. The second unique feature of this case was the unusual presentation of bilateral leg edema and acute retention of urine. There has only been one other case reported in the literature where a wandering spleen led to acute retention of urine<sup>(4)</sup>. Bilateral leg edema has never been associated with wandering spleens or splenic cysts. In this case, the edema was probably due to compression of the pelvic veins by the hypermobile large cyst.

The treatment of splenic cysts and wandering spleens has traditionally been splenectomy<sup>(5-8)</sup>. However, the current appreciation of the immunological importance of the spleen has prompted a reappraisal of this doctrine. The key consideration is the high mortality associated with overwhelming post splenectomy infection<sup>(9)</sup>, which could happen at any time and age<sup>(10-13)</sup>. This has led to the more conservative approach of partial splenectomy for splenic cysts. Satisfactory results have been obtained in the few cases reported<sup>(14-16)</sup>. Preservation of 25% viable remnant spleen offers protection against pneumococcal bacteremia<sup>(17)</sup>. The latest innovation in partial splenectomy is the use of staplers. Experience with staplers in four cases of non-parasitic cysts reported in the literature suggest the technique to be technically simple, fast and safe<sup>(18,19)</sup>.

The idea of conserving the wandering spleen by splenopexy is not new. The earlier techniques of splenopexy were ineffective, leading to a high incidence of recurrence and torsion<sup>(7,20,21)</sup>. This setback, together with the belief that the spleen is an expendable organ, resulted in splenectomy being the operation of choice. But, the present recognition of the importance of

the spleen has refocused attention on splenopexy. Various methods of splenopexy have been tried with some success documented by postoperative ultrasound examination<sup>(20,22,23)</sup>. Splenic conservation should be attempted in children and very young adults. In adults with splenic cysts, splenic conservation is probably worthwhile if it can be done safely. However, in the case of wandering spleens, the wisdom of splenopexy is questioned. The problem of fixation of the spleen to prevent recurrence or torsion has not been adequately resolved.

Laparoscopy has a definite role in managing splenic cysts and wandering spleens in the present era of minimal invasive surgery. Besides its usefulness as a diagnostic tool, laparoscopic splenectomy is technically possible as seen in this case. The spleen itself after mobilization can either be removed through a small incision or broken up within a plastic bag intra-abdominally and then aspirated via a small puncture site. Partial splenectomy will also be possible with the advent of laparoscopic staplers. Although the laparoscopic procedures described above have not been done in human subjects yet, experimental studies are being conducted and it will not be long before splenectomies are done laparoscopically in the human subject.

## REFERENCES

1. Siniluoto T, Paivansalo M, Lohela P. A multicystic wandering spleen. *J Clin Ultrasound* 1987;15:475-7.
2. Spencer GR. A wandering cystic spleen. *J R Coll Edin* 1982;27:183-4.
3. Miller EI. Wandering spleen and pregnancy. *J Clin Ultrasound* 1975;3:281-2.
4. Samuel N, Feldberg D, Dicker D, Goldman JA. Acute urinary retention as presenting symptom of torsion of a wandering spleen. *Eur J Obstet Gynecol Reprod Biol* 1985;19:109-11.
5. Sloane CE, Bramis J, Janowitz HD et al. Epidermoid cyst of the spleen: Case report and discussion. *Mt Sinai J Med (NY)* 1976;43:372-6.
6. Gary Robbins F, Yellin AE, Robert W et al. Splenic epidermoid cyst. *Ann Surg* 1978;187:231-5.
7. Abell I. Wandering spleen with torsion of the pedicle. *Ann Surg* 1933;98:722-35.
8. Hinck VC. Wandering spleen. *Norwest Med* 1961;60:1183-5.
9. Krivit W, Giebink SG, Leonard A. Overwhelming post splenectomy infection. *Surg Clin North Am* 1979;59:223-33.
10. Eichner ER. Splenic function. Normal, too much and too little. *Am J Med* 1979;66:311-20.
11. Balfanz JR, Nesbit ME, Jarvis C et al. Overwhelming sepsis following splenectomy for trauma. *J Pediatr* 1976;88:458-60.
12. Walker W. Splenectomy in childhood: A review in England and Wales, 1960-4. *Br J Surg* 1973;63:36-43.
13. Strauch GO. Preservation of splenic function in adults and children with injured spleens. *Am J Surg* 1979;137:478-83.
14. Senocak ME, Kale G, Hicsonmez A, Buyukpamukcu N. Epidermoid cyst of the spleen. *Turk J Pediatr* 1989;31:233-7.
15. Khan AH, Bensoussan AL, Ouitmet A et al. Partial splenectomy for benign cystic lesions of the spleen. *J Pediatr Surg* 1986;21:747-52.
16. Moller Petersen V, Geerdsen JP, Worning AM. Conservative surgical treatment of splenic cysts. *Acta Chir Scand* 1985;151:397-8.
17. Goldthorn JF, Schwartz AD, Swift AJ et al. Protectiveness of residual splenic tissue after subtotal splenectomy. *J Pediatr* 1978;13:587-90.
18. Flautner L, Harsanyi L, Winternitz T, Horanyi J. Excision of a splenic cyst using a surgical stapler in partial splenectomy. *Orv-Hetil* 1990;131:1363-5.
19. Emery E, Houry S, Lacaine F, Huguier M. Technic of partial splenectomy with linear stapler instrument. *J Chir (Paris)* 1990;127:356-8.
20. Carswell JW. Wandering spleen. 11 cases from Uganda. *Br J Surg* 1974;61:495-7.
21. Fowler RS. Movable spleen. *JAMA* 1914;62:198-9.
22. Stringel G, Sovey P, Mercer S. Torsion of wandering spleen. Splenectomy or splenopexy. *J Pediatr Surg* 1982;74:373.
23. Caracciolo F, Bonatti PL, Castrucci G et al. Wandering spleen: Treatment with colonic displacement. *J R Coll Edin* 1986;31(4):242-4.