

# ELECTROCARDIOGRAPHIC CASE

## SUDDEN ONSET OF RIGHT BUNDLE BRANCH BLOCK

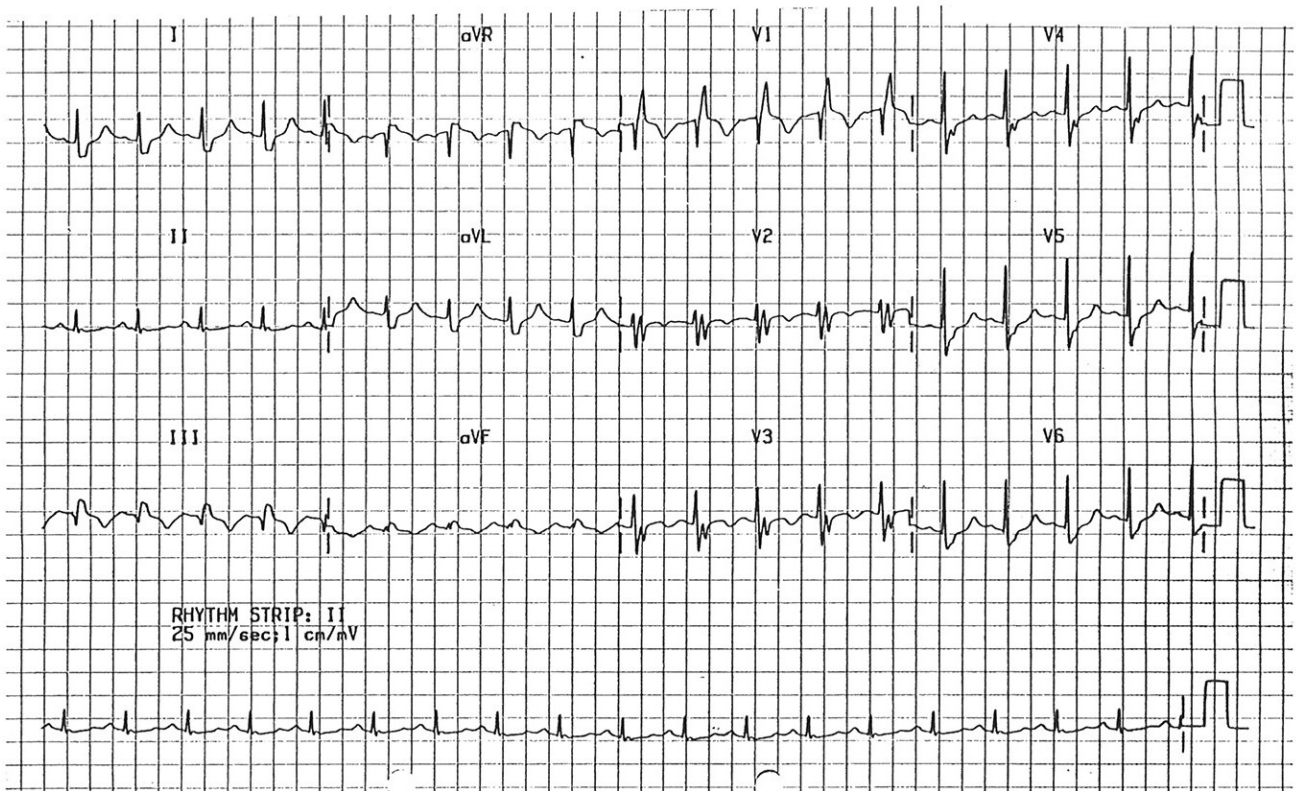
T Chua, W S Teo

### CASE REPORT

A 61-year-old man complained of acute breathlessness and pleuritic chest pain at the Accident and Emergency Department. The 12 lead ECG done at the time is shown in Fig 1. A subsequent ECG done in the ward is shown in Fig 2. What was the diagnosis? (Answer on Page 184)

SINGAPORE MED J 1993; Vol 34: 167-168

Fig 1 - 12 lead electrocardiogram of the patient at the Accident and Emergency Department.



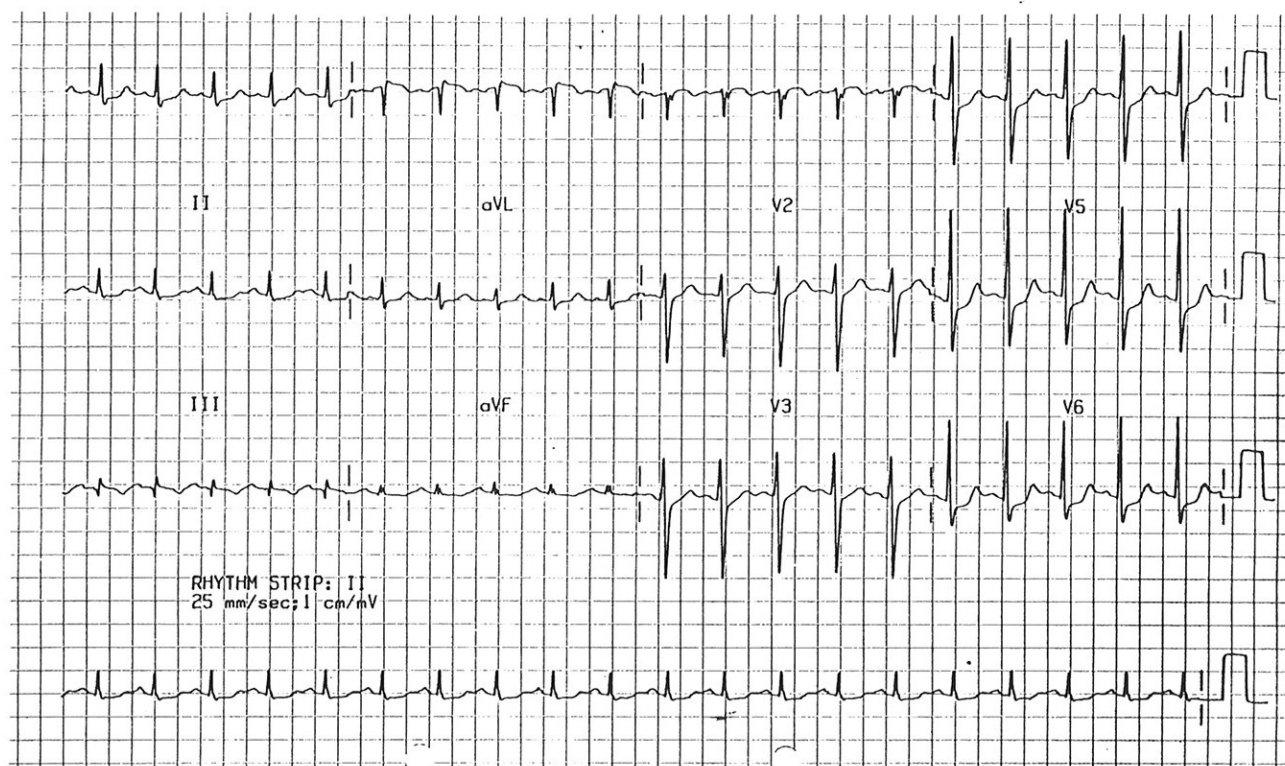
Department of Cardiology  
Singapore General Hospital  
Outram Road  
Singapore 0316

✓ T Chua, MBBS, MRCP(UK), M Med(Int Med)  
Senior Registrar

✓ W S Teo, MBBS, MRCP(UK), M Med(Int Med), FAMS  
Senior Registrar

Correspondence to: Dr W S Teo

Fig 2 - 12 lead electrocardiogram of the patient in the ward.



## 1st Asian Pacific Congress of Endoscopic Surgery

*Date: 6 – 8 August 1993*

*Venue: Shangri-La Hotel, Singapore*

*Theme: Minimally Invasive Surgery – Surgery 2000*

### **For enquiries, please contact:**

Congress Secretariat

1st Asian Pacific Congression of Endoscopic Surgery  
c/o Conference & Exhibition Management Services Pte Ltd  
#09-43 World Trade Centre

Singapore 0409

Tel: (65) 278-8666

Fax: (65) 278-4077

Attn: Ms Maggie Phang