

MAGNETIC RESONANCE IMAGING OF LEPTOMENINGEAL METASTASES TO THE SPINE

S L Chua, P S Goh, L K A Tan

ABSTRACT

Neurologic complications of malignancy can result from paraneoplastic manifestations, cerebral metastases or leptomeningeal involvement. Radiologic evaluation by computerised tomography (CT) has proven to be an invaluable tool in cancer patients with neurologic symptoms. Myelography and CT myelography have been the main modalities for evaluating leptomeningeal metastases. The advent of magnetic resonance imaging (MRI) with contrast has provided an alternative modality for evaluation of leptomeningeal disease. MRI as compared to CT myelography is non-invasive and at least as sensitive. The findings in two patients with leptomeningeal involvement are reported to illustrate the value of MRI.

Keywords: leptomeningeal, contrast MRI, CT myelography

SINGAPORE MED J 1993; Vol 34: 253-256

INTRODUCTION

Leptomeningeal metastases in the spine may be a difficult diagnosis to establish even in patients with a known malignancy. Non-specific symptoms of headache, neck or back pain with or without focal neurological deficit is the usual clinical presentation. We describe two such cases (performed on a GE Signa 1.5 T system) that were examined with contrast enhanced MRI. This modality is a safe, non-invasive means of investigating suspected leptomeningeal disease. The importance of a contrast-enhanced examination is highlighted.

Case 1

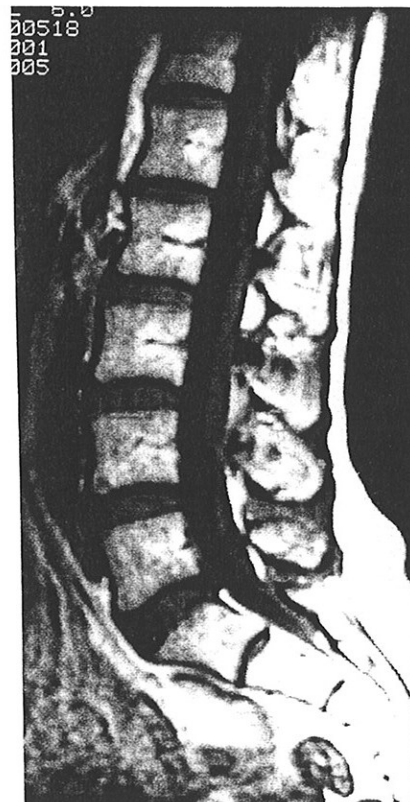AM, a 49-year-old Eurasian lady, presented with a left breast lump for which a mastectomy and axillary clearance was performed. Histology confirmed infiltrative ductal carcinoma with extensive axillary nodal metastases. She was given post-operative radiotherapy to the left chest, but absconded planned adjuvant chemotherapy. She subsequently returned for follow-up and was noted to have left axillary and cervical lymphadenopathy. She was given six cycles of chemotherapy which she tolerated well.

Two months after the discontinuation of chemotherapy, she complained of vomiting, headache and lower back pain and sciatica. Clinical examination revealed decreased perianal sensation to light touch and pin-prick with absent ankle reflexes bilaterally. Power was normal.

MRI of the lumbo-sacral region revealed a degenerated L5/S1 disc but no significant disc herniation or compression of the spinal thecal sac (Fig 1a, 1b). In view of her clinical findings, contrast injection of Gadolinium-DTPA was administered (Fig 2a, 2b). Enhancement of the posterior meninges and nerve roots in the region of the conus was demonstrated. A diagnosis of leptomeningeal metastases was made. Lumbar

puncture confirmed the presence of anaplastic carcinoma cells in the cerebro-spinal fluid. Intra-thecal chemotherapy via an Omayia shunt was administered but the patient's condition continued to deteriorate and she died.

Fig 1a - Non-enhanced MRI Scan.
Spin Echo 600/17 Sagittal image in the lumbar region shows no significant abnormality



Department of Diagnostic Radiology
National University Hospital
Lower Kent Ridge Road
Singapore 0511

S L Chua, MBBS, FRCR(UK)
Senior Lecturer

P S Goh, MBBS
Resident

L K A Tan, MBBS, FAMS, FRCR(UK)
Professor

Correspondence to: Dr S L Chua

Case 2

JJL, a 32-year-old Chinese lady presented with proptosis and epistaxis. Clinical and radiological evaluation confirmed a large tumour in the ethmoid sinus extending into the right orbit and frontal lobe. Biopsy of the mass revealed rhabdomyosarcoma. Treatment with combination chemotherapy and consolidative radiotherapy resulted in marked and rapid regression of the tumour.

Fig 1b - Non-enhanced MRI Scan.

Spin Echo 840/15 Axial image in the lumbar region shows prominence of the nerve roots of the cauda equina.

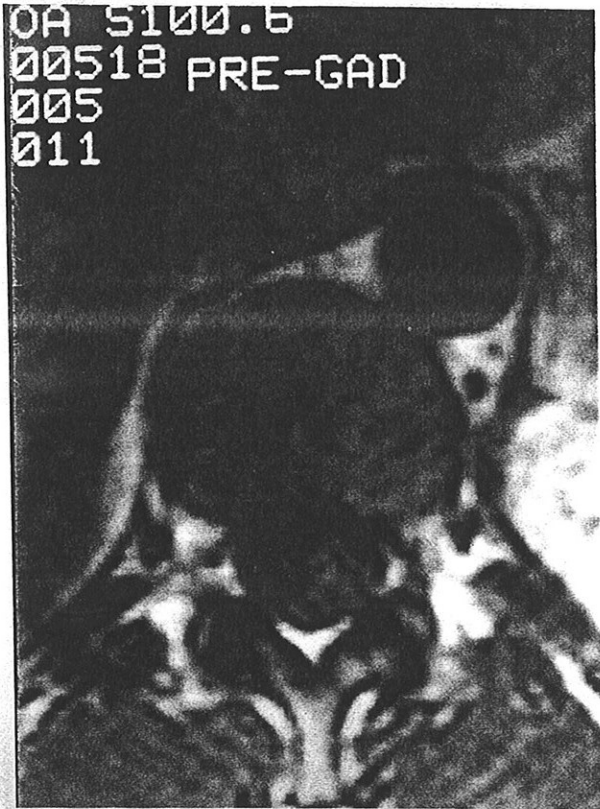

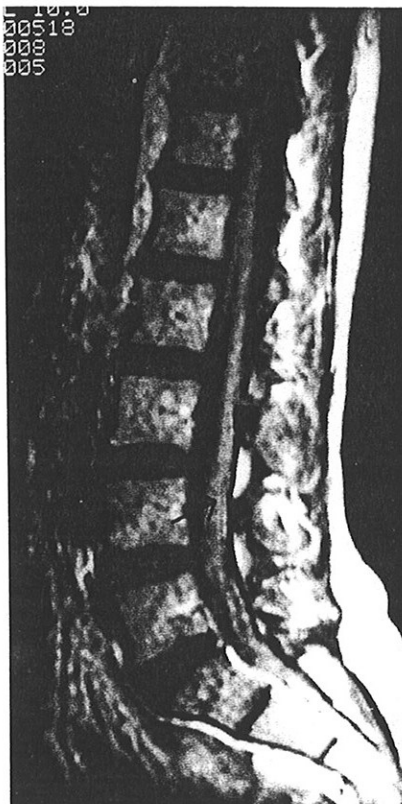
Fig 2b - Enhanced MRI Scan.

Spin Echo 840/15 Axial image demonstrates the thickened and enhancing nerve roots of the cauda equina.

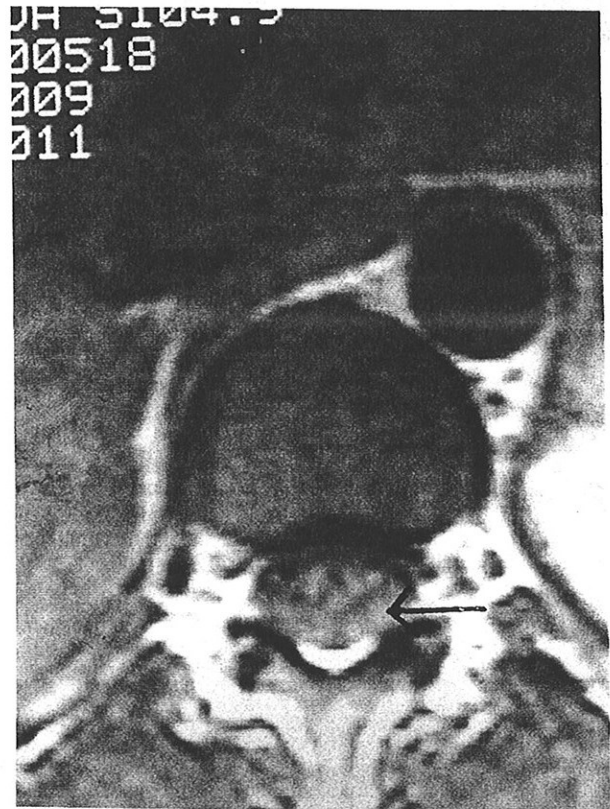

Fig 2a - Enhanced MRI Scan.

Spin Echo 600/17 Sagittal image shows enhancement of the nerve roots of the cauda equina.



However, the patient subsequently presented with bilateral leg weakness of one-month's duration. Clinically, there was decreased power (Grade 4/5) of the upper and lower limbs and a right Babinski reflex.

MRI revealed the spinal cord to be enlarged from C2 to T3 (Fig 3a). Multiple enhancing nodular masses were noted on the surface of the spinal cord in the cervical (Fig 3b) and thoracic regions (Fig 4). In the lumbar region, the pre-enhancement sagittal images appeared grossly normal but after contrast, there was enhancement and thickening of the nerves at the cauda equina. The findings were consistent with leptomeningeal spread of tumour. CSF cytology revealed malignant cells.

The patient was given intra-thecal chemotherapy and radiotherapy. She improved symptomatically but the disease subsequently progressed. She succumbed to her illness 5 months after the diagnosis of leptomeningeal disease.

DISCUSSION

Leptomeningeal metastatic seeding can occur with central nervous system (CNS) and non-CNS tumours. The primary CNS tumours commonly associated with leptomeningeal spread are ependymoma, medulloblastoma, glioblastoma multiforme, germinoma and primary pineal tumours. The common primary non-CNS tumours that also can seed are small cell lung carcinoma, breast carcinoma, melanoma and haematologic malignancies like non-Hodgkin's lymphoma and leukemia^(1,2).

Pathologically, leptomeningeal tumour in the spine is characterised by sheets of tumour cells lining the leptomeninges⁽³⁾. The changes are most prominent on the dorsal aspects of the cord, near the conus medullaris, cauda equina and meninges. They are often overlooked as they may not be evident on

gross examination⁽⁴⁾. As the deposits increase in size, the leptomeninges become thickened and with subarachnoid spread, nodular masses appear.

These gross pathology changes explain the myelographic, CT and MRI appearances of leptomeningeal metastases in the spine. It may appear as diffuse thickening of the nerve root, spinal cord, or nerve root nodules, thickening of the meninges or subarachnoid space nodules. With administration of intravenous contrast in MRI, enhancement of areas of involvement in the meninges, spinal nerves or surface of the spinal cord would improve the detectability of the tumour⁽⁵⁾. The minimum amount of tumour required for detection on MRI has not been ascertained⁽⁶⁾.

Fig 3a - Non-enhanced MRI Scan.
Spin Echo 480/15 Sagittal image in the cervical region shows the cervical spinal cord to be enlarged.

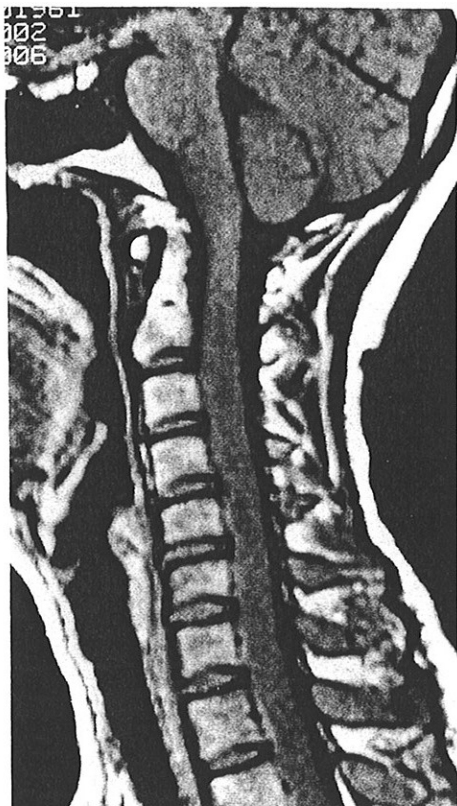


Fig 3b - Enhanced MRI Scan.
Spin Echo 480/15 Sagittal image demonstrates multiple enhancing nodular masses on the surface of the spinal cord.

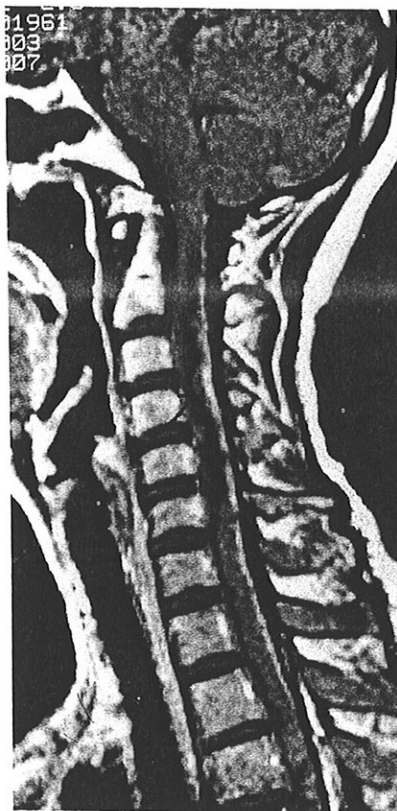
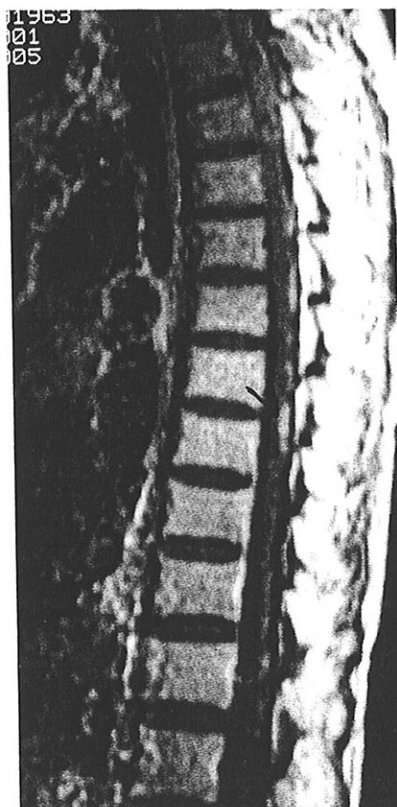


Fig 4 - Enhanced MRI Scan.
Spin Echo 500/20 Sagittal image in the thoracic region shows enhancing plaques along the thoracic cord.



Our two cases illustrate the appearance of leptomeningeal metastases on MRI. On an unenhanced MRI, the leptomeningeal disease in the first patient could not be seen. It was only with contrast enhancement that the leptomeningeal involvement could be demonstrated. The importance of contrast enhancement is highlighted by this case. The MR findings in this patient mimic arachnoiditis, which has similar MRI appearances. However, this is unlikely in patients without prior surgery or instrumentation.

In the second patient, the leptomeningeal metastases was evident even without contrast. This is probably related to higher tumour load in and around the cord. Enhancement with contrast helps to clinch the diagnosis, as demonstrated by nodular enhancing masses and enhancing thickened nerves of the cauda equina.

Myelography and CT myelography are established methods of detecting leptomeningeal disease in the spine. Although useful, these are invasive procedures which are potentially

hazardous, especially in patients with concomitant raised intracranial pressure from cerebral metastases. With the advent of MRI, the role of myelography and CT myelography has declined. While a non-enhanced MRI is inferior to myelography^(7,8), enhanced MRI with Gadolinium-DTPA is comparable to myelography and CT myelography⁽⁵⁾ in the evaluation of leptomeningeal disease of the spine. Studies have shown that metastatic screening MRI without the intravenous administration of MRI contrast agent may miss the diagnosis of leptomeningeal disease^(9,10). The appearances are not specific for metastatic disease, and infectious and inflammatory conditions may present similarly. However, patients with a known malignancy and unexplained neurologic symptoms and signs undergoing MRI to evaluate for spinal disease should have a contrast-enhanced examination to improve the detection rate for leptomeningeal metastases to the spine⁽¹¹⁾.

As to the choice between a myelographic examination and a contrast-enhanced MRI to evaluate for leptomeningeal metastases, MRI is at least comparable to myelography and if not superior, for it has the added advantages of being non-invasive and the ability to detect metastatic disease in marrow and surrounding tissues.

MRI improves our ability to image the central nervous

system. With its increasing use, we will be able to further understand its strengths and weaknesses and place it in proper perspective against the other conventional imaging modalities.

REFERENCES

1. Berns DH, Blaser S, Ross JS, Masaryk TJ, Modic MT. MR Imaging with Gd-DTPA in lepto-meningeal spread of lymphoma. *J Comput Assist Tomogr* 1988;12:499-500.
2. Yousem DM, Patrone PM, Grossman RI. Lepto-meningeal metastases: MR Evaluation. *J Comput Assist Tomogr* 1990;14:225-61.
3. Wasserstrom WR, Glass JP, Posner JB. Diagnosis and Treatment of Lepto-meningeal metastases from Solid Tumours: Experience with 90 patients. *Cancer* 1982;49:759-72.
4. Parsons M. The Spinal Form of Carcinomatous Meningitis. *Q J Med* 1972;164:509-19.
5. Sze G. Gadolinium-DTPA in Spinal Disease. *Rad Clin North Am* 1988;26:1009-24.
6. Frank JA, Girton M, Dwyer AJ, Wright DC, Conen PJ, Doppman JL. Meningeal Carcinomatosis in the VX2 Rabbit Tumour Model: Detection with Gd-DTPA-enhanced MR Imaging. *Radiology* 1988;167:825-9.
7. Carmody RF, Yang PJ, Seeley GW, Seeger JF, Unger FE, Johnson JE. Spinal cord compression due to metastatic disease: Diagnosis with MR Imaging versus Myelography. *Radiology* 1989;173:225-9.
8. Davis PG, Friedman NC, Fry SM, Malko JA, Hoffmann JC, Braun IF. Lepto-meningeal metastasis: MR Imaging. *Radiology* 1987;163:449-54.
9. Lim V, Sobel DF, Zyroff Z. Spinal cord pial metastases: MR Imaging with Gadopentetate Dimeglumine. *AJNR* 1990;11:975-82.
10. Sze G, Stimac GK, Bartlett C, Dillon WP, Houghton VM, Orrison W, et al. Multicentre Study of Gadopentetate Dimeglumine as an MR Contrast Agent: Evaluation in Patients with Spinal Tumours. *AJNR* 1990;11:967-74.
11. Sze G, Krol G, Zimmerman RD, Deck MDF. Intramedullary Disease of the Spine: Diagnosis Using Gadolinium - DTPA-Enhanced MR Imaging. *AJR* 1988;151:1193-204.

8TH INTERNATIONAL WORKSHOP ON THERAPEUTIC ENDOSCOPY

*organised by The Chinese University of Hong Kong
and Hong Kong Society of Digestive Endoscopy*

Date : 30 November to 2 December 1993

Venue: Combined Endoscopy Unit

Prince of Wales Hospital

The Chinese University of Hong Kong

Shatin, N.T.

Hong Kong

For further information, please contact:

Dr Sydney Chung

Combined Endoscopy Unit

The Chinese University of Hong Kong

Prince of Wales Hospital

Shatin, N.T.

Hong Kong