

EXPERIENCE WITH LAPAROSCOPIC CHOLECYSTECTOMY AT THE TOA PAYOH HOSPITAL

H C Chng, K H Chia, F C Ng

ABSTRACT

A retrospective analysis was done of 88 cases of laparoscopic cholecystectomy performed by the first author from November 1990 to March 1992 at the Toa Payoh Hospital. There were 61 female and 27 male patients; the average age was 47.1 years. The most common presenting symptom was biliary colic (85.3%), followed by acute cholecystitis (10.2%) and gallstone pancreatitis (4.5%). In the vast majority of patients, the diagnosis was established by ultrasound (96.6%) while the remainder was diagnosed by oral cholecystography (3.4%). The operation was performed using the usual 4 puncture approach with the single-handed technique of dissection. Antibiotic prophylaxis with a broad-spectrum agent was used in all patients and there was no incidence of wound infection. A low complication rate of 4.5% was experienced - consisting of 1 case each of subcutaneous emphysema, abdominal colic, fever and bile duct injury. There was no mortality in our series. The conversion rate was 9.1% and this was due to our policy of performing laparotomy whenever the safety of laparoscopic surgery was in doubt. The mean duration of postoperative hospitalisation was 3 days and 7 days after laparoscopic and converted cholecystectomies respectively. The majority of patients (61.4%) returned to work after 2 weeks.

Keywords: Laparoscopy, cholecystectomy

SINGAPORE MED J 1993; Vol 34: 205-207

INTRODUCTION

Open cholecystectomy has remained the gold standard for the treatment of gallstones despite the introduction of dissolution therapy and the advent of the lithotripter. With the current wave of interest in minimal access surgery in the past 2 years, laparoscopic cholecystectomy has evolved as an alternative to the open method. Laparoscopy has been around since the turn of the century and had been used by general surgeons for assessment of upper abdominal masses, in particular, liver masses; it was, however, mainly an instrument of the gynaecologists. Recently, with improvement in the technology of laparoscopic equipment, new interest and enthusiasm have been re-focused on laparoscopic surgery.

Laparoscopic cholecystectomy was first performed by Philippe Mouret of Lyon, France in March 1987 when he removed the diseased gallbladder of a woman during laparoscopic gynaecological surgery. The technique was subsequently popularised by Dubois in France, Reddick in USA and Cushieri in Scotland, amidst a great wave of enthusiasm and interest in laparoscopic surgery all over the world.

Our retrospective study aims to ascertain the safety and efficacy of laparoscopic cholecystectomy over the conventional open operation. The complications and benefits of the laparoscopic method are also determined.

PATIENTS AND METHODS

A total of 88 laparoscopic cholecystectomies were performed by the first author at the Department of Surgery from November 1990 to March 1992.

Department of Surgery
Toa Payoh Hospital
Toa Payoh Rise
Singapore 1129

H C Chng, MBBS, M Med(Int Med), FRACS, FAMS
Senior Consultant Surgeon and Chief

K H Chia, MBBS, FRCS(Edin)
Registrar

F C Ng, MBBS, FRCS(Edin)
Registrar

Correspondence to: Dr H C Chng

Our indication for surgery was the presence of symptomatic gallstones.

Contraindications to laparoscopic cholecystectomy included pregnancy, cholangitis, previous extensive upper abdominal surgery, peritonitis, ileus, morbid obesity, bleeding disorders and advanced liver disease.

Preoperative evaluation included routine assessment for fitness to undergo general anaesthesia, liver function test, plain abdominal X-ray and an ultrasound scan of the hepatobiliary system. Endoscopic retrograde cholangiopancreatography (ERCP) was performed preoperatively in selected cases where there had been jaundice, pancreatitis, dilated CBD on ultrasound scan or a raised serum alkaline phosphatase.

A single intravenous dose of a broad-spectrum antibiotic is given preoperatively and is continued for 24 to 48 hours after surgery. The patient is placed in the supine position with a head-up tilt under general anaesthesia with the preplacement of a nasogastric tube and a urinary catheter. The operating surgeon stands on the left side of the patient. The operative procedure is based on the 'single-handed' technique. Surgical access is obtained via 4 punctures made in the anterior abdominal wall. The first step involves the creation of a pneumoperitoneum via insertion of a Veress needle into the subumbilical region followed by insufflation of carbon dioxide and the subsequent establishment of the 11 mm primary portal for the operating laparoscope (0 or 30°) with its attached camera system. A second 10 mm portal is placed in the upper abdomen in the midline or slightly to the left and two other 5 mm portals are placed in the right upper abdomen under laparoscopic vision.

Laparoscopic instruments are inserted through the accessory cannulae for the manipulation and dissection of the gallbladder. Calot's triangle is dissected and the cystic duct and artery are displayed. Laparoscopic cholangiography was performed in the later part of the series to detect unsuspected stones in the common bile duct (CBD) and to provide a road map of the biliary tree in each patient in order to minimise the risk of iatrogenic bile duct injury. The technique requires the placement of a specially designed cholangiogram catheter into the cystic duct. The catheter is held in place by cholangiogram forceps. Two films are usually taken with the use of 75% diluted Uromiro^R contrast.

Following this, both the cystic duct and artery are ligated with clips and divided. The next step involves the dissection

of the gallbladder by using electrocautery. The gallbladder is then removed through the subumbilical portal. Both the nasogastric tube and urinary catheter are removed in the immediate postoperative period.

Oral feeding is started on the first postoperative day and the patient is discharged from the hospital from the first postoperative day onwards. Return to normal activity takes place within 1 week.

RESULTS

The 88 patients in the study ranged in age from 20 to 78 years with a mean of 47.1 years. There were 61 females and 27 males with a female to male ratio of 2.3:1.

Seventy-five patients (85.3%) presented with biliary colic while 9 patients had acute cholecystitis (10.2%). Four patients had acute pancreatitis (4.5%). Preoperative diagnosis was made in 85 patients (96.6%) by ultrasound and in the remaining 3 patients by oral cholecystography (3.4%). ERCP was performed preoperatively in 16 patients (18.2%) with papillotomy and extraction of stones from the CBD in 2 patients.

Sixteen patients (18.2%) had previous abdominal surgery - 2 upper and 14 lower abdominal operations respectively. Associated medical conditions such as ischaemic heart disease, hypertension, chronic obstructive airways disease and diabetes mellitus were present in 30 patients (34.1%).

The operating time ranged from 30 to 140 minutes with an average time of 64.5 minutes. The last 13 cases in our series also had operative cholangiography performed, with successful attempts made in 12 cases (92.3%). In these cases, the average operating time was 85.4 minutes with an average time of 20.9 minutes being taken to perform an operative cholangiogram. In patients with contracted gallbladders, the mean operating time was 71.7 minutes whereas it took an average of only 57.9 minutes to remove non-contracted gallbladders. The presence of intraabdominal and pericholecystic adhesions also prolonged the operating time by 17.9 minutes to an average duration of 75.8 minutes.

Laparoscopic surgery had to be aborted in 8 patients because of technical difficulties in gaining access and performing dissection. Open cholecystectomy was therefore carried out in these patients resulting in a conversion rate of 9.1%.

There were complications in 4 patients (4.5%) consisting of 1 case each of subcutaneous emphysema, abdominal colic, postoperative fever and bile duct injury. The complication of subcutaneous emphysema resolved spontaneously within 24 hours. The 2 patients with abdominal colic and fever were readmitted following discharge from hospital; the former patient was found to have a mild episode of adhesion colic which resolved with conservative management. An ultrasound scan of the abdomen for the patient with postoperative fever showed a small subhepatic collection which responded to a course of antibiotics. The patient with bile duct injury presented with obstructive jaundice in the postoperative period; ERCP showed complete obstruction of the CBD caused by an improperly placed clip. Exploratory laparotomy with an end-to-side choledochojejunostomy was performed with an uneventful postoperative recovery. There were no cases of wound infection, ileus, retained CBD stones, bowel injury, intraoperative bleeding, bile leak or respiratory complication. There was no mortality in the series.

The mean period of hospital stay was 3 days for the patients who had their gallbladders removed laparoscopically. For the remaining 8 patients who had an open procedure, their mean period of stay was 7 days. Four patients (4.5%) were discharged on the first postoperative day. The majority of patients were discharged on the second and third postoperative days - 32 patients (36.4%) and 19 patients (21.6%) respec-

tively. The remaining 33 patients (37.5%) were discharged from the fourth postoperative day onwards.

DISCUSSION

Laparoscopic cholecystectomy has distinct advantages over the conventional open operation in terms of reduction of hospitalisation stay and a early return to full activity and work. Morbidity is significantly much lower with minimal postoperative pain and discomfort and an absence of wound complications. In addition, the cosmetic result is superior with four small scars which are hardly visible⁽¹⁾. Moreover, there is no increase in cost over the conventional method.

In our series, we had a conversion rate of 9.1% because of various reasons such as dense adhesions, difficult biliary tract anatomy and severe inflammation around the gallbladder. The relatively high conversion rate demonstrates our readiness to convert to an open cholecystectomy at any time when there is doubt about the safety of further laparoscopic dissection. A similar sentiment has been echoed by Flowers⁽²⁾. In the later part of the series, 9 patients (10.2%) who had acute cholecystitis were operated on and had an uneventful postoperative recovery.

Out of 88 patients, there were 16 patients (18.2%) who had previous abdominal surgery, 2 in the upper and 14 in the lower abdominal regions respectively. One of the 2 patients with previous upper abdominal surgery required conversion to conventional cholecystectomy because of the presence of dense adhesions. The remaining 15 patients underwent uneventful laparoscopic cholecystectomies. Reddick et al⁽³⁾ similarly found that laparoscopic management of difficult gallbladder problems was both safe and effective. In their series, 96 of 360 patients (27%) had previous abdominal surgery and in difficult cases, the Hasson technique was used for initial entry into the abdomen. Eleven of their patients with acute cholecystitis and 12 patients with hydrops of the gallbladder were treated successfully by laparoscopic surgery. In our experience, the presence of a contracted gallbladder prolonged the duration of operation by 13.8 minutes and adhesions lengthened the operation by 17.9 minutes. A contracted gallbladder making laparoscopic dissection more difficult has been attributed by other authors to the short cystic duct in such cases.

Out of a total of 88 laparoscopic cholecystectomies, there were 4 patients (4.5%) with complications viz subcutaneous emphysema, abdominal colic, postoperative fever and bile duct injury. This is comparable to other series which report figures of about 5.1%⁽⁴⁾. Our rate of 1.1% for bile duct injury is comparable to figures of 0% to 1.4% reported by other centres. The potential for CBD injury may be greater in the laparoscopic method when compared to the open method as the CBD is usually not dissected to any great extent in the former; in addition, there is the problem of considerable tenting of the CBD. Various authors^(5,6) have emphasised meticulous dissection and adequate display of the gallbladder and cystic duct junction during laparoscopic cholecystectomy and that the cystic duct should be clearly traced to the gallbladder prior to any clipping or division.

In a retrospective review of the experience of various European surgeons⁽⁷⁾, antibiotic prophylaxis in the form of a single-dose cephalosporin was used by 95% of surgeons. In our series, antibiotic prophylaxis with a broad spectrum agent significantly reduced the incidence of postoperative infective complications. There was no incidence of wound infection; one patient who had postoperative fever due to a small subhepatic collection, resolved completely with antibiotic treatment.

Routine operative cholangiography has been advocated by some workers to delineate biliary tract anatomy so as to minimise the incidence of duct injury. In our study, operative

cholangiography was performed subsequently in the series when adequate experience and familiarity with the technique of laparoscopic cholecystectomy had already been achieved. In the earlier cases, ERCP was performed preoperatively where indicated ie jaundice, pancreatitis, dilated CBD on ultrasound scanning or a raised serum alkaline phosphatase. The efficacy and safety of laparoscopic operative cholangiography would be the subject of our subsequent review.

Laparoscopic cholecystectomy requires additional training in laparoscopic techniques and various centres all over the world recognise the need for a formal training programme with accreditation on completion of a course with 'hands-on' training and supervised practical experience^(8,9). The importance of familiarity with the highly specialised and technical equipment and new instruments cannot be overemphasised. The outcome of such a structured training programme must be a good outcome for patients who undergo laparoscopic cholecystectomy. The first author himself trained at the St Francis Medical Centre at Pittsburgh in USA.

CONCLUSION

The advent of laparoscopic cholecystectomy represents a milestone in the treatment of gallstones. Its use will gradually become more widespread and the results will improve with experience. Laparoscopic cholecystectomy is a major surgical

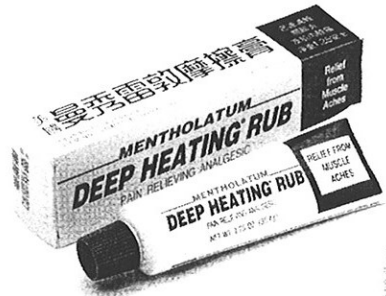skill that has to be acquired in a formal training programme in an institution with accreditation on completion of training and acquisition of the necessary experience; in addition; the surgical outcome of such laparoscopic services must be subjected to a stringent system of audit so that this promising new technique will not fall into disrepute as a result of inadequate training and inexperience. There are distinct advantages over conventional surgery in addition to an improved overall cost-effectiveness in the treatment of gallstone disease.

REFERENCES

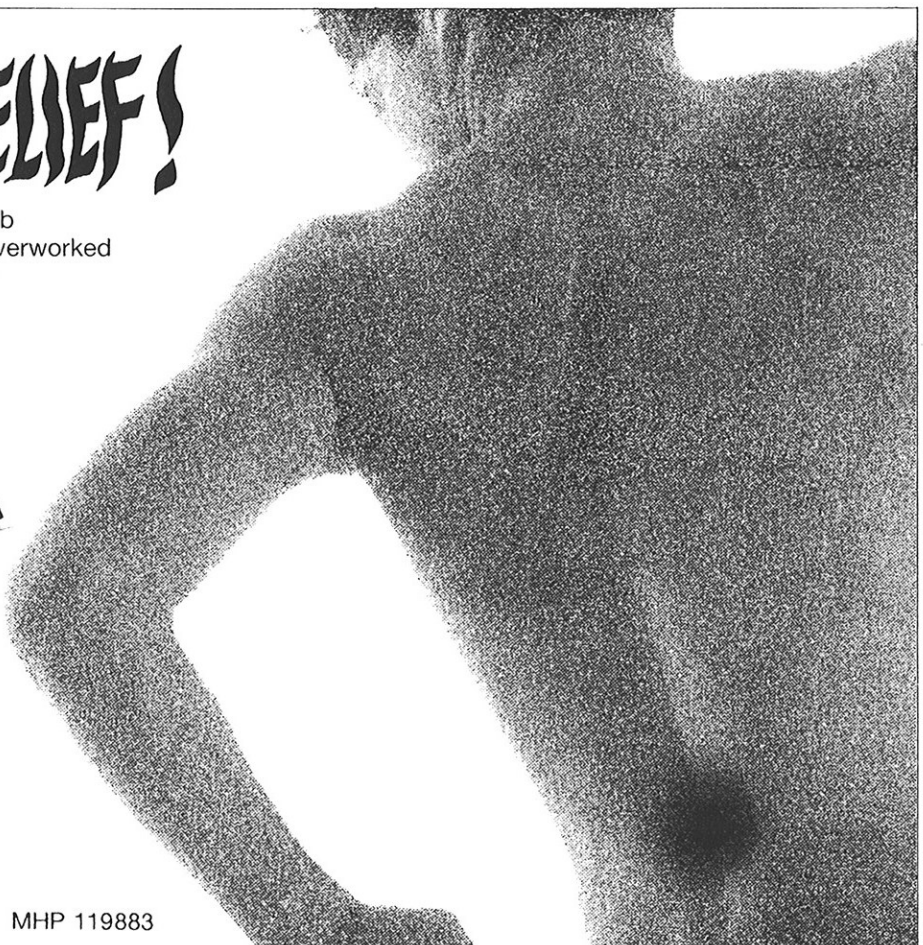
1. Olsen DO. Laparoscopic cholecystectomy. *Am J Surg* 1991;161:339-44.
2. Flowers JL, Bailey RW, Scovill WA, Zucker KA. The Baltimore experience with laparoscopic management of acute cholecystitis. *Am J Surg* 1991;161:388-92.
3. Reddick EJ, Olsen D, Spaw A, Baird D, Asbun H, O'Reilly M, et al. Safe performance of difficult laparoscopic cholecystectomies. *Am J Surg* 1991;161:377-81.
4. Southern Surgeons Club. A prospective analysis of 1518 laparoscopic cholecystectomies. *N Engl J Med* 1991;324:1073-8.
5. Ponsky JL. Complications of laparoscopic cholecystectomy. *Am J Surg* 1991;161:393-5.
6. Voyles CR, Petro AB, Meena AL, Haick AJ, Koury AM. A practical approach to laparoscopic cholecystectomy. *Am J Surg* 1991;161:365-70.
7. Cushieri A, Dubois F, Mouiel J, Mouret P, Becker H, Buess G, et al. The European experience with laparoscopic cholecystectomy. *Am J Surg* 1991;161:385-7.
8. Gadacz TR, Talamini MA. Traditional versus laparoscopic cholecystectomy. *Am J Surg* 1991;161:336-8.
9. Berci G, Sackier JM. The Los Angeles experience with laparoscopic cholecystectomy. *Am J Surg* 1991;161:382-4.

WHAT A RELIEF!

Mentholatum Deep Heating Rub brings effective relief to tired overworked muscles. Its deep, penetrating warmth brings fast relief.



Marketed and distributed by
GETZ
BROS. HEALTH AND BEAUTY CARE
 1006, Pasir Panjang Road, Singapore 0511. Tel: 4759777



MHP 119883