

PERCUTANEOUS BALLOON AORTIC VALVOTOMY

K S Ng, A T H Tan, C N S Chan, Z P Ding

ABSTRACT

We report our first case of percutaneous balloon aortic valvotomy in a 72-year-old Chinese female with critical aortic stenosis and carcinoma of the stomach. The presence of critical aortic stenosis (mean aortic pressure gradient of 65 mmHg and an aortic valve area of 0.5 cm²) placed her at a high risk for gastrectomy. After balloon valvotomy of the aortic valve, the mean pressure gradient fell to 21 mmHg and the aortic valvular area increased to 1.0 cm². She improved clinically and subsequently underwent surgery with no haemodynamic complication. Overseas experience has shown that percutaneous balloon valvotomy can be done with little technical difficulty and excellent patient tolerance, resulting in good haemodynamic and clinical improvement and a low acute complication rate. Present follow-up data however suggest significant mortality and restenosis rates at the end of one year. Percutaneous balloon aortic valvotomy (PBAV) has a significant though narrowly defined role in the management of patients with severe calcific aortic stenosis.

Keywords: critical calcific aortic stenosis, percutaneous balloon aortic valvotomy, carcinoma of the stomach, gastrectomy

SINGAPORE MED J 1993; Vol 34: 208-210

INTRODUCTION

Successful balloon valvotomy in adult patients with calcific aortic stenosis was first reported in 1986 by Cribier et al⁽¹⁾, followed shortly by McKay et al⁽²⁾. It has provided a new modality of treatment of critical aortic stenosis in elderly patients in whom valve replacement is refused or contraindicated because of high operative risk. It also offers a viable non-surgical approach for such patients who would otherwise be at prohibitive risk from a non-cardiac operation. We report a case of an elderly patient with critical calcific aortic stenosis who successfully underwent gastrectomy for carcinoma of the stomach after percutaneous balloon aortic valvotomy.

CASE REPORT

N.T., a 72-year-old Chinese female, was admitted to the hospital for non-specific giddiness and exertional shortness of breath (NYHA Class II). She did not have angina or syncope. She was diabetic and hypertensive, on medication at primary outpatient level. Physical examination showed an ejection systolic murmur grade 3/6 along left sternal edge, radiating to the carotids with an anacrotic pulse of severe aortic stenosis. ECG showed left ventricular hypertrophy and the chest X-ray mild cardiomegaly.

Echocardiography confirmed heavily calcific critical aortic stenosis. Peak pressure gradient across the aortic valve on Doppler flow studies (Table I) was 116 mmHg and the mean pressure gradient 69.4 mmHg. Vmax was 5.8 ms⁻¹. The calculated aortic valve area was 0.4 cm² (continuity equation). There was accompanying mild aortic regurgitation. The mitral valve was mildly stenotic (mitral valve area 1.8 cm² by pressure half-time method). Mild concentric left ventricular hypertro-

phy was present, with good left ventricular function (ejection fraction 70%). There was mild tricuspid regurgitation.

Table I - Doppler Characteristics of the patient's calcific aortic stenosis

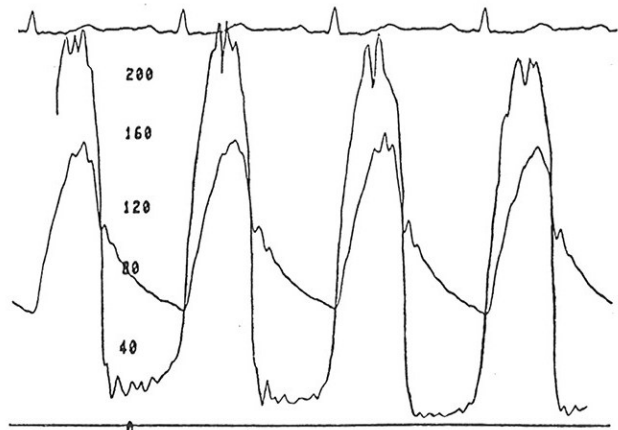
	Pre-PBAV	Post-PBAV
Peak pressure gradient	116.0 mmHg	72.3 mmHg
Mean pressure gradient	69.4 mmHg	40.8 mmHg
Vmax	5.8 ms ⁻¹	4.3 ms ⁻¹
AV area	0.4 cm ²	0.8 cm ²

She was found to have iron deficiency anaemia with a haemoglobin of 8.6 g/dL. The barium meal showed a raised lesion along the lesser curvature close to the incisura angularis, with an ulcerated centre. Histology of the biopsy specimen taken during gastroscopy subsequently confirmed a well-differentiated adenocarcinoma.

The patient was considered at a high risk for gastrectomy in view of the critical aortic stenosis.

Cardiac catheterisation showed a left ventricular pressure of 214/0/23 and aortic pressure of 152/58 (Fig 1). The aortic valve was heavily calcified with severely limited mobility. Left ventricular function was normal with thickened walls (EF 80%). Selective coronary arteriography did not show any significant coronary lesion.

Fig 1 - Simultaneous aortic and left ventricular pressure tracings obtained (0 - 200 mmHg scale) in N.T.



Department of Cardiology
Singapore General Hospital
Outram Road
Singapore 0316

K S Ng, MRCP(UK)
Registrar

A T H Tan, M Med(Int Med), FRACP(Aust), FAMS
Senior Consultant and Head

C N S Chan, MRCP(UK)
Senior Registrar

Z P Ding, M Med(Int Med)
Consultant

Correspondence to: Dr A T H Tan

Percutaneous balloon valvotomy was performed with a Cribier-Letac balloon via the retrograde femoral approach. After collecting the baseline haemodynamic data and recording the aortic-left ventricular pressures, an exchange guide wire technique was used to advance the valvotomy balloon catheter across the aortic valve (Fig 2). A pressure-controlled hand pump was used to inject a 50/50 mixture of contrast medium and 0.9% saline solution to inflate the balloon to the point of rupture. After balloon valvotomy, the mean aortic gradient fell from 65 mmHg to 21 mmHg with an increase in calculated aortic valve area from 0.5 cm² to 1.0 cm² (Table II). There was no increase in aortic regurgitation or emboli. A repeat echocardiographic study done the following week (Table II) showed a peak pressure gradient of 72.3 mmHg and mean pressure gradient of 40.8 mmHg. Vmax was 4.3 ms⁻¹ and the calculated aortic valve area was 0.8 cm². The patient improved clinically and eventually underwent a successful gastrectomy/omectomy with no occurrence of haemodynamic complication.

Fig 2(a) - Correct position of the balloon centred across the stenotic aortic valve during early balloon inflation

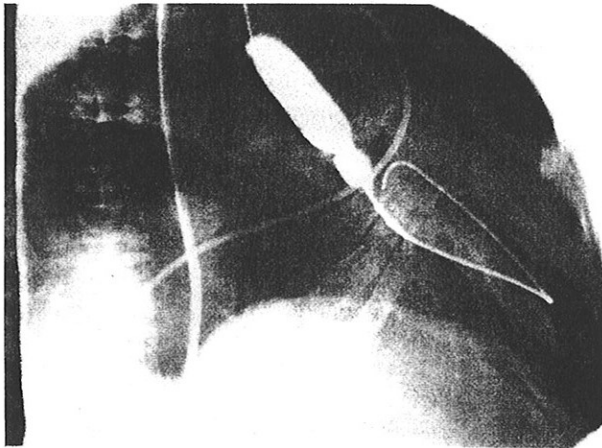


Fig 2(b) - Correct position of the balloon centred across the stenotic aortic valve during full balloon inflation

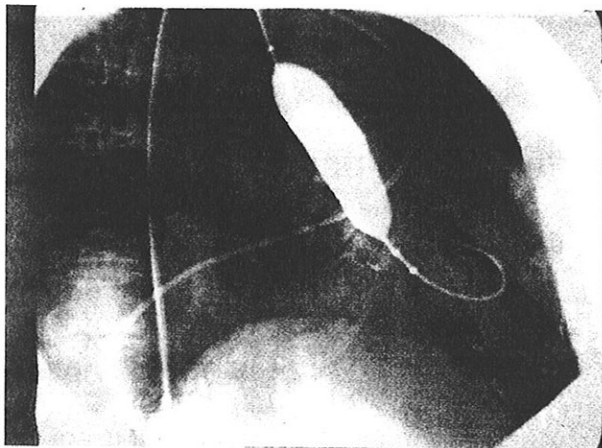


Table II - Haemodynamic data during percutaneous balloon valvotomy

	Pre-PBAV	Post-PBAV
Pulmonary artery pressure	37/16 mmHg	27/9 mmHg
Mean aortic pressure gradient	65 mmHg	21 mmHg
Aortic Valve Area	0.5 cm ²	1.0 cm ²

DISCUSSION

The management of the patient with severe aortic stenosis has in recent years seen a new development. Until 1986, the only modality of treatment had been surgical correction. Open commissurotomy or valvuloplasty may be possible in a few with non-calcific stenosis, but in the overwhelming majority, the correction entailed valve replacement. A significant drawback, however, was the substantial peri-operative risk involved, particularly in elderly patients⁽³⁾. In patients above 70 years of age, mortality rates ranged from 7% to 15%⁽⁴⁻⁶⁾ and peaked at 20%-30% in octogenarians⁽⁷⁾.

The first report in 1986 of Cribier et al of successful non-operative therapy of three elderly patients with severe calcific aortic stenosis⁽¹⁾, together with other early reports^(8,9), have suggested that balloon valvotomy might provide effective palliation in such patient subsets. Following initial reports of successful balloon aortic valvotomy in elderly patients, larger series have appeared^(10,11) (Table III). The mean age of Cribier's patient study group of 92 patients was 75 years. Valvotomy resulted in a reduction of the mean systolic pressure gradient from 75 ± 26 to 30 ± 13 mmHg and an increase in aortic valvular area from 0.49 ± 0.17 to 0.93 ± 0.36 cm². Immediately after the procedure, the ejection fraction increased from 48 ± 16 to 51 ± 16%. There were only minor increases in the severity of aortic regurgitation. Subsequent follow-up showed marked clinical improvement although there were 3 in-hospital deaths and 8 late deaths. Catheterisation performed in 12 patients 4 to 24 weeks later showed that the haemodynamic improvement persisted. Similar results were noted in Schneider's series⁽⁸⁾.

Table III- Summary of reported series

Reference (first author)	Year	No of Patients	Aortic gradient (mmHg)		Valve Area (cm ²)	
			Pre	Post	Pre	Post
Lababidi	1984	23	113	32	-	-
Walls	1984	27	125	35	-	-
Cribier	1987	92	75	30	0.49	0.93
McKay	1987	32	77	39	0.6	0.9
Isner	1987	9	57	30	0.42	0.81
Schneider	1987	6	47	32	0.64	0.9
Dorros	1987	10	62	26	0.56	1.03
Palacios	1987	35	66	33	0.5	0.8
Safian	1988	170	71	36	0.6	0.9
Litvack	1988	25	66	40	0.5	0.7
Nishimura	1988	25	48	33	0.54	0.85
Letac	1988	218	72	29	0.52	0.93

These results were also verified later by a multicentre study involving 492 patients across Europe and North America (Mansfield Scientific Aortic Valvuloplasty Registry)⁽¹²⁾ which showed that balloon aortic valvotomy can result in acute haemodynamic improvement with minimal risk of increased aortic regurgitation. Acute complications were acceptably low. Thirty-one patients (6.3%) suffered acute catastrophic complications⁽¹³⁾, viz ventricular perforation (1.8%), acute severe aortic regurgitation (0.8%), fatal cardiac arrest (2.6%), fatal cerebrovascular accident (0.4%) and limb amputation (0.6%). When complications such as these developed, fatality rate was high at 77%. Overall mortality was 7.5% (37 patients)⁽¹⁴⁾. Multivariate analysis identified 4 factors associated with increased mortality: 1) the occurrence of a procedure-related complication, 2) a lower initial left ventricular systolic pressure, 3) a small final aortic valve area, and 4) a lower baseline cardiac output.

The mechanisms of balloon aortic valvotomy studied in 39 cases by Safian et al⁽¹⁵⁾ include fracture of calcified nod-

ules, separation of fused commissures and grossly inapparent micro-fractures. Liberation of calcific debris, valve disruption or middleleaflet tears did not occur as was initially feared. The range of possible mechanisms together with the range of possible aetiologies of aortic stenosis may explain the heterogeneous results seen in balloon aortic valvotomy and may be an important factor in the time-course of valvular restenosis.

Although follow-up of balloon valvotomy is limited, there are sufficient data to show that mortality and restenosis rates are high in the first year following the procedure. From the Mansfield Scientific Aortic Valvuloplasty Registry at one year, the overall survival rate was 64% and the event-free survival rate (survival free of repeat valvotomy or valve replacement) was 43%^(16,17). The results of the repeat or multiple valvotomy procedures in patients with valvular restenosis have not been much better⁽¹⁷⁾.

As a result, use of the procedure thus far has been commonly limited to patients with severe aortic stenosis in whom risk of open heart surgery is high because of advanced age or concurrent illness (eg chronic obstructive airway disease) and also those with severe aortic stenosis and a second medical condition in need of surgical intervention (eg resection of a malignancy, fixation of a hip fracture, surgery for gastrointestinal bleeding). Studies are underway to define a role for balloon valvotomy in reducing the afterload and thereby slowing the natural history and delaying the need for operation. Conceivably too, the procedure may be used to predict the response following valve dilatation of patients with critical aortic stenosis characterised by a low aortic valve gradient with low cardiac output in whom valve replacement is contemplated.

The use of percutaneous balloon valvotomy in our patient here is the first well documented case in Singapore. The procedure proved a technical success and the patient experienced clinical improvement. This enabled her to undergo abdominal surgery for carcinoma of the stomach uneventfully. As at the time of writing, she has been discharged well.

ACKNOWLEDGEMENT

We thank Mr Lim Chye Kwee of Cardiovascular Laboratory, Singapore General Hospital for his kind assistance in the production of the illustrations.

REFERENCES

1. Cribier A, Savin T, Saoudi N, et al. Percutaneous transluminal valvuloplasty of acquired aortic stenosis in elderly patients: an alternative to valve replacement? *Lancet* 1986;i:63-7.
2. McKay RG, Safian RD, Lock JE, et al. Balloon dilatation of calcific aortic stenosis in elderly patients: postmortem, intraoperative, and percutaneous studies. *Circulation* 1986;74:119-25.
3. O'Keefe JH, Shub C, Rettke SR. Can patients with severe aortic stenosis safely undergo non-cardiac surgery? (abstract) *Circulation* 1988;78(suppl 2):II-132.
4. Magovern JA, Pennock JL, Campbell DB, et al. Aortic valve replacement and combined aortic valve replacement and coronary artery bypass: predicting high risk groups. *J Am Coll Cardiol* 1987;9:38-43.
5. Carabello BA, Green LH, Grossman W, et al. Haemodynamic determinants of prognosis of aortic valve replacement in critical aortic stenosis and advanced congestive heart failure. *Circulation* 1980;62:42-8.
6. Mullany CJ, Elveback LR, Frye RL, et al. Coronary artery disease and its management: influence on survival in patients undergoing aortic valve replacement. *J Am Coll Cardiol* 1987;10:66-72.
7. Edmunds LH Jr, Stephenson LW, Edie RN, Ratcliffe MB. Open heart surgery in octogenarians. *N Engl J Med* 1988;319:131-6.
8. Schneider JF, Wilson M, Gallant TE. Percutaneous balloon aortic valvuloplasty for aortic stenosis in elderly patients at high risk for surgery. *Ann Intern Med* 1987;106:696-9.
9. Safian RD, Berman AD, Diver DJ, et al. Balloon aortic valvuloplasty in 170 consecutive patients. *N Engl J Med* 1988;319:125-30.
10. McKay RG, Safian RD, Lock JE, et al. Assessment of left ventricular and aortic valve function after aortic balloon valvuloplasty in adult patients with critical aortic stenosis. *Circulation* 1987;75:192-203.
11. Cribier A, Savin T, Berland J, et al. Percutaneous transluminal balloon aortic valvuloplasty of adult aortic stenosis: report of 92 cases. *J Am Coll Cardiol* 1987;9:381-6.
12. McKay RG. The Mansfield Scientific Aortic Valvuloplasty Registry: Overview of acute haemodynamic results and procedural complications. *J Am Coll Cardiol* 1991;17:485-91.
13. Isner JM. Acute catastrophic complications of balloon aortic valvuloplasty. *J Am Coll Cardiol* 1991;17:1436-44.
14. Holmes DR, Nishimura RA, Reeder GS. In-hospital mortality after balloon aortic valvuloplasty: frequency and associated factors. *J Am Coll Cardiol* 1991;17:189-92.
15. Safian RD, Mandell VS, Thurer RE, et al. Postmortem and intraoperative balloon valvuloplasty of calcific aortic stenosis in elderly patients: mechanisms of successful dilation. *J Am Coll Cardiol* 1991;17:485-91.
16. O'Neill WW. Predictors of long-term survival after percutaneous aortic valvuloplasty. Report of the Mansfield Scientific Balloon Valvuloplasty Registry. *J Am Coll Cardiol* 1991;17:193-8.
17. Ferguson JJ, Garza RA. Efficacy of multiple balloon valvuloplasty procedures. *J Am Coll Cardiol* 1991;17:1430-5.

11th Biennial Asian Congress on Thoracic and Cardiovascular Surgery

*organised by the Malaysian Thoracic and Cardiovascular
Surgical Association*

*Date: 21 – 25 November 1993
Venue: Kuala Lumpur, Malaysia*

For further information, please contact:

11th BACTCS Secretariat
Room 3, 5th Floor, MMA House
124 Jalan Pahang
53000 Kuala Lumpur
Malaysia
Tel: 03-4429662
Fax: 03-4421618