

# ELECTROCARDIOGRAPHIC CASE

## LOW QRS VOLTAGES - DIFFERENTIAL DIAGNOSIS

W S Teo, S A Gunawan

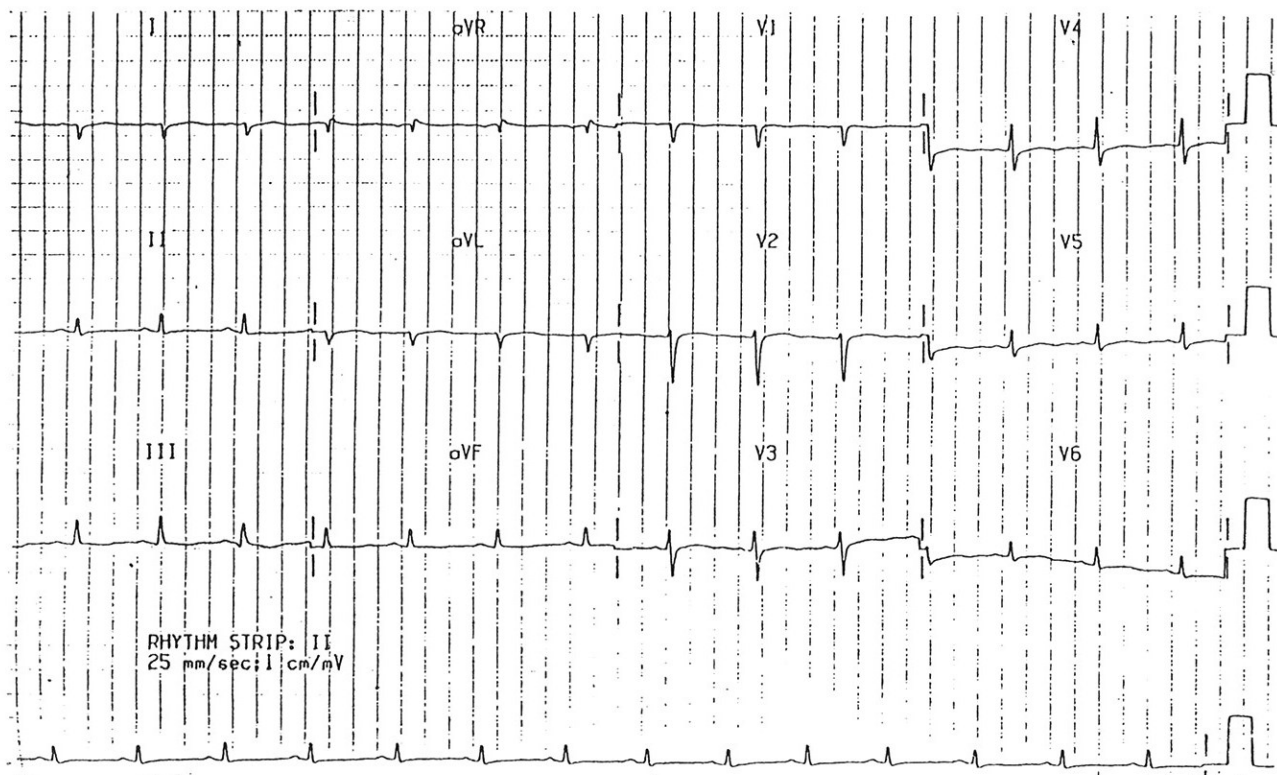
### CASE REPORT

A 35-year-old Chinese female was admitted with complaints of breathlessness for 3 days, swelling of the limbs and history of menorrhagia. Clinical examination revealed a fair general condition. The blood pressure was 130/80 mmHg, the pulse rate was 80 beats per minute and regular. She was found to have a raised jugular venous pressure, soft heart sounds, no pericardial rub, bilateral basal crepitations and an enlarged liver. Chest X-ray showed cardiomegaly with pulmonary congestion. Her 12 lead electrocardiogram is shown below.

What is your diagnosis? (Answer on Page 280)

SINGAPORE MED J 1993; Vol 34: 265 & 280

Fig 1 - 12 lead electrocardiogram on admission



Department of Cardiology  
Singapore General Hospital  
Outram Road  
Singapore 0316

W S Teo, MBBS, M Med(Int Med), MRCP(UK), FAMS  
Senior Registrar

S A Gunawan, MD  
Registrar

Correspondence to: Dr W S Teo