

EXCIMER LASER PHOTOREFRACTIVE KERATECTOMY IN SINGAPORE - A NEW TREATMENT MODALITY FOR MYOPIA

V Balakrishnan, A S M Lim, C H Low, C P Lee, P S F Tseng, W K Chan, T K Chan, J Tan, D Tan

ABSTRACT

Background : Myopia is a national epidemic in Singapore. Photorefractive Keratectomy (PRK) for the treatment of myopia using the Argon Fluoride Excimer Laser commenced in January 1992 at the Singapore National Eye Centre.

Methods : An open, prospective, non randomised clinical trial to assess the efficacy, predictability, stability, and safety of PRK for the correction of myopia between -2.0 to -6.0 dioptres.

Results : One hundred and fifty-five eyes of one hundred and thirty-five patients underwent PRK between January and September 1992, of which thirty-one had completed at least six months of follow-up. Twenty-nine of the thirty-one patients (93.5%) achieved an unaided visual acuity of at least 6/12. Twenty-six patients (83.9%) were within 1 dioptre of emmetropia. There was an initial over-correction in all patients which regressed to a plateau at around three or four months. Corneal haze did not pose a significant problem. Three patients had ocular hypertension, and another developed a mild allergic reaction to the antibiotic-steroid ointment.

Conclusions : Excimer Laser Photorefractive Keratectomy is a very effective, fairly predictable, stable and safe surgical method for the treatment of myopia.

Keywords: myopia, excimer, laser, photorefractive keratectomy, Singapore

SINGAPORE MED J 1993; Vol 34: 309-312

INTRODUCTION

Myopia is a national epidemic in Singapore, affecting an estimated 25-50% of students and up to 80% of undergraduates⁽¹⁻³⁾. For the vast majority of such patients, spectacles have been, and are the safest and most effective means of refractive cor-

rection.

However, our increasing obsession with physical appearance and lifestyle has prompted a significant minority of such patients to undertake the gamble of refractive surgery.

Radial keratotomy has been widely practised and available in Singapore since 1986. The results obtained locally have been gratifying, and comparable with those obtained overseas. However, there have been reasonable objections to this procedure on both theoretical and practical grounds. The procedure consists of almost full thickness incisions in the corneal periphery which cause peripheral bulging and central flattening of the cornea. Unfortunately, this method results in radical biomechanical changes in the cornea, with the attendant problems of a permanently weakened globe, refractive instability, irregular refractive surfaces, scars along the incision sites, and variability of correction achieved⁽⁴⁾. The permanent linear scars also evoke an almost instinctive aversion in most ophthalmologists who have been brought up to value corneal clarity.

Consequently, the advent of a new ultraviolet laser under microcomputer control was greeted with excitement by both ophthalmologists and their patients. This paper describes the initial results of an open, prospective, non randomised clinical trial in Singapore which began in January 1992.

MATERIALS AND METHODS

Theoretical Basis of Photoablation

The word EXCIMER is derived from the term EXCIted diMER. Atoms of argon can be transiently attached to atoms of fluoride through a very high kilovoltage electrical discharge. The resulting dimer is extremely unstable and breaks down readily with the emission of a photon of light with a wavelength of 193 nm. This short wavelength (in the UV-C region of the spectrum) confers upon each photon 6.8eV. This highly energetic photon is able to directly cleave the carbon to carbon bonds which form the backbone of all organic molecules. This is a photochemical effect, quite unlike the thermal denaturation which is the typical effect of lasers with longer wavelengths.

Thus, photoablation is a unique laser tissue interaction

Department of Ophthalmology
National University of Singapore
Lower Kent Ridge Road
Singapore 0511

V Balakrishnan, M Med (Ophth), FRCSEd, FCOphth
Lecturer

A S M Lim, FRCS, FRCSEd, FRACS, FRACO, FCOphth, FAMS
Professor

C H Low, FRCS, FRCSEd, FRCSSG, FCOphth, FAMS
Visiting Consultant

T K Chan, M Med (Ophth), FRCSEd, FCOphth
Lecturer

Singapore National Eye Centre
11 Third Hospital Avenue
Singapore 0316

C P Lee, FRCSG, FAMS
Visiting Consultant

P S F Tseng, FRCSG, FAMS
Consultant

W K Chan, M Med (Ophth), FRCSEd, FCOphth
Registrar

J Tan, FRCSEd
Visiting Consultant

D Tan, FRCSG
Registrar

Correspondence to: Dr V Balakrishnan

This project was supported by a grant from the Singapore Totalisator Board.

whereby organic material is converted into a gaseous state within tenths of a microsecond and expelled from the surface. The small penetration depth (about 3 microns at 193 nm) and the short laser pulse (less than 50 nsec) result in minimal heat transfer to the adjacent tissue. This is of considerable importance when dealing with a transparent tissue like the cornea, when denaturation of the collagen would result in loss of transparency and distortion.

Krauss et al⁽⁵⁾ has shown that normal microscopic ultrastructure is retained just 0.5 microns from the edge of an excision. Thus, it is an atraumatic fine cutting tool, with accuracy measured in terms of less than 0.25 microns.

In 1983, Trokel and Srinivasan⁽⁶⁾ first described the interaction of argon fluoride excimer laser and the cornea. In this paper, they suggested the possibility of using the laser for precise refractive and therapeutic applications. In particular, the application of graded amounts of photons from the centre to periphery of the cornea provides a method for causing either flattening or steepening of the central corneal profile. The mathematics of this procedure was described by Munnerlyn⁽⁷⁾.

Device description

The ExciMed UV200 excimer laser system from Summit Technology, Inc which emits pulsed laser light at 193 nm with an internally controlled fluence of 180 mJ/cm² and frequency of 10 Hz was used. A 5-mm diameter ablation zone was used.

Patients

We operated on one hundred and fifty-five eyes of one hundred and thirty-five patients between January and September 1992. Of these, thirty-one patients have reached at least 6 months of follow up.

All potential patients who were spectacle and contact lens intolerant were screened extensively prior to recruitment for this study.

Inclusion Criteria:

1. Male or female, any race, 21 years of age or older.
2. Mild to moderate degree of myopia (2.0-6.0 dioptres, spherical equivalent).
3. Best corrected visual acuity (BCVA) of 6/9 or better in both eyes.
4. Cylindrical component of the manifest refraction is not greater than 1.0 dioptre.
5. Contact lens wearers must have
 - a) removed soft or gas permeable contact lenses two weeks prior to baseline measurements
 - b) removed hard (PMMA) contact lenses three weeks prior to baseline measurements, and have three central keratometry readings and manifest refractions taken at one week intervals, the last two of which must not differ by more than 0.5 dioptres in either meridian; mires regular
6. Spherical or cylindrical portion of manifest refraction has progressed at a rate of -0.50 dioptre or less per year from date of baseline examination.
7. Available to attend follow-up examinations for a one-year period.

Exclusion Criteria:

1. Under 21 years of age.
2. Progressive myopia or keratoconus.
3. Residual, recurrent or active ocular disease or corneal abnormality, such as iritis, uveitis, keratitis sicca, blepharitis, or visually significant cataract.
4. Taking any systemic medications likely to affect wound healing, such as corticosteroids or antimetabolites.
5. Immunocompromised.

6. Patent corneal neovascularization within 1 mm of the ablation zone.
7. Refractive error progression -0.50 dioptre per year from date of baseline examination.
8. Previous corneal surgery or trauma in the ablation zone.
9. Systemic disease likely to affect wound healing, such as systemic connective tissue disease, diabetes and severe atopic disease.
10. Unstable or irregular keratometry readings.
11. Cylindrical component of the manifest refraction is greater than 1.00 dioptre.

If both eyes could potentially be treated, the selection of the operative eye was made by the physician and patient, and was, in most cases, the non dominant eye.

Preoperative examination

This included a detailed history, slit lamp examination, keratometry, subjective and cycloplegic refraction, ultrasonic axial length determination, applanation tonometry and a retinal review.

Operative procedure

Topical anaesthesia was administered using Proparacaine drops every five minutes until patient comfort was secured. One drop of 1% Pilocarpine was used thirty minutes before surgery to obtain partial miosis.

The patient was instructed to fixate on a green fixation light, and familiarised with the sights, smells and sound of laser ablation. Fixation stability was also assessed and in doubtful cases, the procedure was postponed.

The corneal epithelium was removed with a #64 Beaver blade up to a diameter of 6 mm. Meticulous removal of all cellular debris from Bowman's membrane was done. Aiming of the laser beam was performed using the confluence of 2 HeNe laser beams. The procedure was pupil centred and dependent on patient fixation.

In this phase of study, we aimed for full correction of the myopia.

An ointment containing Tobramycin and Dexamethasone was applied. The eye was then padded and the patient discharged with analgesics and sedatives.

Post-operative drug regime

The eye was padded until full reepithelialisation had occurred. This took between two to five days in all our patients. After this stage, the patients were put on Fluoromethalone Forte (1%) drops five times a day for one month. Subsequently, they were given Fluoromethalone 0.1% drops four times a day for one month. This was gradually tailed down over a period of four months.

Post-operative examination

The patients were seen daily until reepithelialisation was complete. Thereafter, they were seen at the end of the first week, second week, first month and monthly until the sixth month. Subsequent follow-up examinations will be conducted at one year, eighteen months and two years after the procedure.

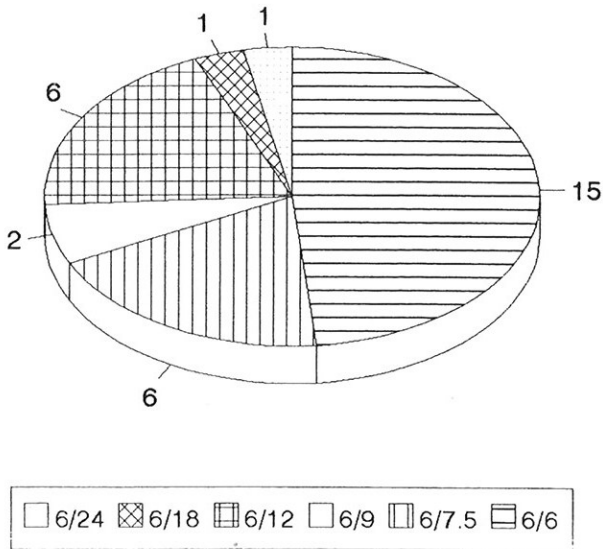
At each visit, the state of epithelial healing, corneal clarity, visual acuity (unaided and best corrected), refractive status, intraocular pressure and complications (if any) were assessed and recorded. All data was captured using a Dbase program written by the author and analysed using the SAS-PC (Statistical Analysis System Inc) software package.

RESULTS

We will be presenting the refractive results obtained after six months of follow-up in thirty-one patients.

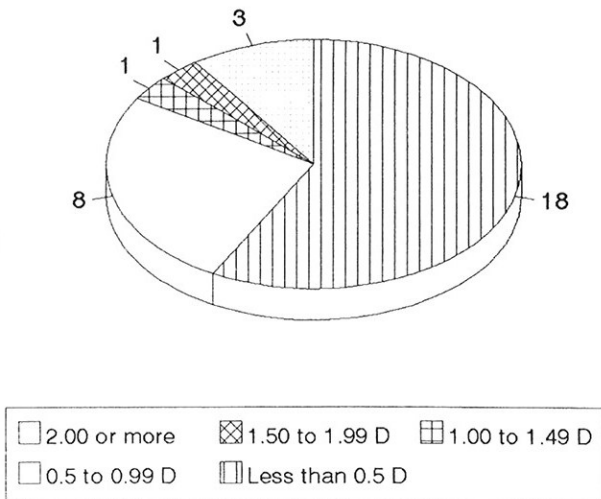
The results will be analysed in terms of efficacy, predictability, stability and safety.

Fig 1 - Efficacy (Unaided visual acuities)



93.6% achieved 6/12 or better

Fig 2 - Efficacy (Spherical Equivalents)



83.9% within 1 Dioptre of emmetropia

Efficacy

Twenty-nine of the thirty-one patients (93.6%) achieved unaided visual acuities of 6/12 or better. The 95% confidence interval is from 78.6% to 99.2%. Even more gratifying was the fact that fifteen patients (48.4%) reached 6/6 without any correction (Fig 1).

Less than satisfactory results occurred in only 2 patients who failed to achieve this, and this was due to residual hyperopia of 1.5 and 2 dioptres respectively.

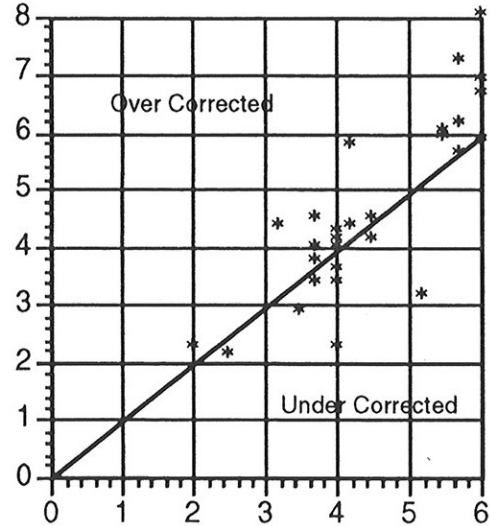
Twenty-six of the thirty-one patients (83.9%) were within one dioptre of emmetropia (Fig 2). The standard deviation was 0.86 dioptres. The most undercorrected case had residual myopia of -2.25 dioptres, and the most overcorrected case had hyperopia of 2 dioptres.

Predictability

This was evaluated by comparing the intended correction vs the achieved correction. The scatterplot shows fairly tight as-

sociation between these two variables, However, there is some concern that we are obtaining significant overcorrections in almost all of those who underwent an attempted correction of 6 dioptres (Fig 3).

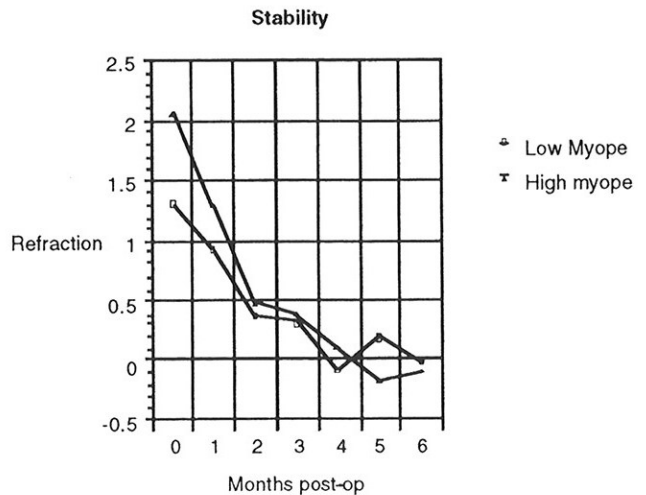
Fig 3 - Predictability



Stability

All patients showed an initial hyperopia immediately post-operatively. This was followed by a regression phase during which there was a shift in the myopic direction (ie became less hyperopic). Some went on further to become mildly myopic. Our sample is too small for statistical significance, but it appeared that patients for whom smaller corrections were attempted reached emmetropia faster (Fig 4).

Fig 4 - Stability



Change in best corrected acuity

This was obviously an issue of paramount concern. Fortunately, only one patient lost two lines (from 6/6 to 6/9) in best corrected acuity. This was a patient in whom a 6 dioptre correction was attempted, and slight haze was still present.

Eight patients dropped one line from 6/6 to 6/7.5

Epithelial healing

All patients re-epithelialised within three days except for one patient who took five days. There were no cases of recurrent erosions.

Corneal clarity

All patients developed some measure of haze around three to four weeks after the procedure. However, at the sixth month follow-up, only two had mild haze which did not affect refraction, twelve had trace amounts of haze, whilst seventeen had no clinically detectable haze.

Change in astigmatism

Only three patients developed more than 1.5 dioptres of astigmatism post-operatively. The worst case has 3 dioptres, but still manages to achieve 6/9 unaided.

Glaucoma

One patient was noted to have intraocular pressure of 39 mm Hg 2 months after PRK. However, the contralateral eye was found to have a similarly elevated pressure. Fortunately, the visual fields were intact, and the optic discs did not show any glaucomatous cupping. On reviewing the case sheets subsequently, it was found that he had pre-existing ocular hypertension, and had inadvertently been included in the series. Consequently, it appears that this was not related to either the procedure or the steroids used post-operatively. Nevertheless, the steroids were discontinued in this patient.

Two other patients developed steroid induced glaucoma. This responded to treatment with beta blockade and reduction/cessation of steroid therapy. No perimetric or optic disc changes were noted.

Allergy

One patient developed allergic reaction to the Tobradex ointment, but made an uneventful recovery with systemic antihistamines.

DISCUSSION

Excimer laser photorefractive keratectomy is a new technique⁽⁷⁻¹²⁾, with no long term results available anywhere in the world. However, our preliminary results are encouraging.

PRK is certainly efficacious for the reduction of low to moderate myopia. This is precisely the same group who also do well with radial keratotomy, which has minimal capital outlay, compared to the \$700,000 needed for the Excimer laser itself. Consequently, it must be shown to be manifestly superior to radial keratotomy if it is to assume its place as the routine method for the surgical correction of myopia.

The fact that 93.6% achieve 6/12 vision is certainly promising.

Predictability, or accuracy, seems to be good, at least at the sixth month milestone. However, the regression towards myopia is worth noting for at least two reasons.

Firstly, it appears to be flattening around three to four months post-operatively. In fact, this is necessary in order to compensate for the initial hyperopia which is believed to result from greater epithelial hyperplasia at the margins of the wound, compared to the centre, thus causing excessive central flattening.

Secondly, there is a possibility of a long term, albeit slow drift towards frank myopia^(10,11). This is in contrast to radial keratotomy which manifests a long term hyperopic shift, which is more difficult to treat surgically. On the other hand, regression of myopia may only require top up treatments with the laser in the future.

Corneal haze has been another issue of great concern⁽¹³⁾. It is our impression that the actual effects of the haze on visual performance may have been over-rated. The haze that is visible to the clinician represents backward scatter, ie light which does not enter the patient's eye, and hence does not significantly affect visual performance. Instead, it is forward scatter that is the critical issue, and this does not always correlate well with clinically observed haze. Nevertheless, it appears that all patients show a reduction of haze with time.

Another issue of contention is the use of steroid drops post operatively. The basis for this is the theory that pharmacologic modification of corneal wound healing would prevent undue regression of effect and reduce the development of haze.

Nevertheless, some doubts have been expressed by Gartry et al⁽¹⁴⁾ about whether any long term benefits are obtained from routine post PRK steroid treatment, and randomised double blind studies are underway in a few centres. If this hypothesis is proven, then elimination of steroids would alleviate the anxieties of ophthalmologists regarding patients being on topical steroids for up to five months.

In conclusion, preliminary results show that excimer laser photorefractive keratectomy is highly efficacious, fairly predictable, probably stable and safe for the correction of low to moderate myopes. Further studies will be required for patients with high myopia and astigmatism. The post-operative regime will probably undergo further modification in the light of new information.

ACKNOWLEDGEMENTS

We record our appreciation to Professor Wallace Foulds, CBE, MD, FRCS, FRCSG, DO, Hon DSc, Hon FRACO, Hon FCOphth for invaluable assistance in the preparation of this manuscript.

REFERENCES

1. Ling SL, Chen AJ, Rajan U, Cheah WM. Myopia in ten year old children: A case control study. *Singapore Med J* 1987; 28:288-92.
2. Chew SJ, Chia SC, Lee L. Epidemiology of myopia in young Singapore men. *Singapore Med J* 1988; 29:201-11.
3. Chow YC, Dhillon B, Chew PTK, Chew SJ. Refractive errors in Singapore medical students. *Singapore Med J* 1990; 31:472-3.
4. Waring GO, Lynn MJ, Fielding B, Asbell PA. Results of the prospective evaluation of radial keratotomy (PERK) study 4 years after surgery for myopia. *JAMA* 1990; 263:1083-91.
5. Krauss JM, Puliafito CA, Steinert RF. Laser interactions with the cornea. *Surv Ophthalmol* 1986; 31:37-53. [published erratum appears in *Surv Ophthalmol* 1986; 31:144].
6. Trokel SL, Srinivasan R, Braren B. Excimer laser surgery of the cornea. *Am J Ophthalmol* 1983; 96:710-5.
7. Munnerlyn CR, Koons SJ, Marshall J. Photorefractive keratectomy: a technique for laser refractive surgery. *J Cataract Refract Surg* 1988; 14:46-52.
8. Gartry D, Kerr Muir MG, Marshall J. Photorefractive keratectomy with an argon fluoride excimer laser: A clinical study. *Refract Corneal Surg* 1991; 7:420-35.
9. Zabel RW, Sher NA, Ostrov CS, Parker P, Lindstrom RL. Myopic excimer laser keratectomy: a preliminary report. *Refract Corneal Surg* 1990; 6:329-34.
10. McDonald MB, Frantz JM, Klyce SD, Beuerman RW, Varnell R, Munnerlyn CR, et al. Central photorefractive keratectomy for myopia. The blind eye study. *Arch Ophthalmol* 1990; 108:799-808.
11. McDonald MB, Frantz JM, Klyce SD, Salmeron B, Beuerman RW, Munnerlyn CR, et al. One-year refractive results of central photorefractive keratectomy for myopia in the nonhuman primate cornea. *Arch Ophthalmol* 1990; 108:40-7.
12. Marshall J, Trokel SL, Rothery S, Krueger RR. Long-term healing of the central cornea after photorefractive keratectomy using an excimer laser. *Ophthalmology* 1988; 95:1411-21.
13. Lohmann CP, Fitzke F, Timberlake G, Gartry D, Kerr Muir M, Marshall J. Corneal transparency after excimer laser photorefractive keratectomy: a new technique for objective measurements of haze. *Refract Corneal Surg* 1992; 8:114-21.
14. Gartry D, Kerr Muir MG, Lohmann CP, Marshall J. The effect of topical corticosteroids on refractive outcome and corneal haze after photorefractive keratectomy. *Arch Ophthalmol* 1992; 110:944-52.