

ATYPICAL PNEUMONIA DUE TO CHLAMYDIA PNEUMONIAE: A CASE REPORT

Y M Cheong, W K Wong, Y F Ngeow

ABSTRACT

A first case of *Chlamydia pneumoniae* pneumonia in Malaysia is reported. The diagnosis was made by a significant change in *C. pneumoniae* antibody titre. The infection responded well to a course of erythromycin.

Keywords : atypical pneumonia, *Chlamydia pneumoniae*

SINGAPORE MED J 1993; Vol 34: 352-353

INTRODUCTION

Until recently, the causes of atypical pneumonia have been attributed to mainly *Mycoplasma pneumoniae* and viruses. However, with the demonstration of *Chlamydia pneumoniae*, a newly recognised chlamydial species previously called the TWAR strain of *Chlamydia psittaci*, as a cause of respiratory infections, there has been a number of reports describing it to be a common cause of community acquired pneumonia⁽¹⁻³⁾. We report the first case of atypical pneumonia due to *C. pneumoniae* detected in a seroepidemiological survey of pneumonias in Malaysia.

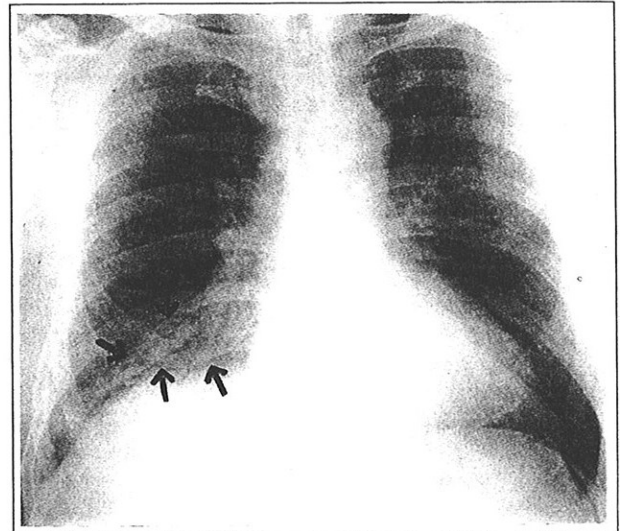
CASE REPORT

The patient was a 48-year-old steelpipe worker. He was a diabetic of many years on glibenclamide 5 mg daily. He smoked 60 cigarettes daily. He first presented to his general practitioner with a history of fever and malaise of 5 days duration and a dry irritating cough of one day. He did not feel dyspnoea and there was no pleuritic chest pain. He was diagnosed by his general practitioner to have pneumonia and subsequently referred for treatment on 13 June 1991.

Physical examination showed that he was febrile with a temperature of 38.2°C. His pulse rate was 120 per min, but he was not tachypnoeic or cyanosed. There was no clubbing or lymphadenopathy. There were localised fine crepitations in the right middle zone and right lower zone posteriorly. No wheeze or pleural rub was detected.

Chest X-ray showed partial collapse and patchy consolidation of the lower right lobe. There was no associated hilar enlargement or pleural effusion (Fig 1).

Fig 1 - Chest X-ray showing partial collapse and patchy consolidation of right lobe



Laboratory investigation showed that he had a haemoglobin of 14.8 g/dl and a total white count of 5600 per mm³ with 72% polymorphs, 20% lymphocytes and 2% atypical lymphocytes.

Based on the above findings, a diagnosis of atypical pneumonia was made. He was treated with oral erythromycin 500 mg qid for fourteen days. He was reviewed four days and twelve days later and there was marked symptomatic and clinical improvement. A repeat chest X-ray on 10 July 1991 ie about a month later, showed complete resolution.

Sera obtained on the fifth and thirty-third day of illness were examined for the presence of antibodies to *Mycoplasma pneumoniae* by the passive particle agglutination method (Serodia, Myco II, Fujireibo, Japan); to *Legionella pneumophila* serogroup 1-6 by the indirect immunofluorescence method (MarDx Diagnostics Inc.) and to *Chlamydia trachomatis*, *C. psittaci* and *C. pneumoniae* by the microimmunofluorescence method. The results are shown in Table I.

DISCUSSION

Laboratory diagnosis of *Chlamydia pneumoniae* infection is based on isolation of the organism, serological findings and lately the polymerase chain reaction technique⁽⁴⁾. In a private practice situation, the only convenient test is by serology. In this patient, the IgG antibody level was 1:256 taken during the first week of illness, and dropped to 1:64 in the 4th week of illness. Hence there was a significant drop in titre. IgM antibody was not detected. This is consistent with the serological changes in a case of acute reinfection with *Chlamydia pneumoniae* where classically the TWAR IgG antibody often appears within one to two weeks and may reach very high titre with no IgM antibody or a very low titre⁽⁵⁾.

Institute for Medical Research
Bacteriology Division
Jalan Pahang
50588 Kuala Lumpur
Malaysia

Y M Cheong, MBBS, MSc, MRCP
Head

Wong Medical & Chest Clinic
Kuala Lumpur
Malaysia

W K Wong, MBBS, MRCP
Consultant Physician

Department of Medical Microbiology
University Hospital
Kuala Lumpur
Malaysia

Y F Ngeow, MBBS, MSc
Associate Professor

Correspondence to: Dr Y M Cheong

Table I - Results of serological tests

Antigen	Antibody level	
	1st sample (5th day)	2nd sample (33th day)
<i>Mycoplasma pneumoniae</i>	< 1:40	< 1:40
<i>Legionella pneumophila</i> serogroup 1-6	1:16	1:16
<i>Chlamydia trachomatis</i>	< 1:8	< 1:8
<i>Chlamydia psittaci</i>	< 1:8	< 1:8
<i>Chlamydia pneumoniae</i>	IgG 1:256 IgM < 1:8	IgG 1:64 IgM < 1: 8

Antibodies to *Mycoplasma pneumoniae* and *Legionella pneumophila* were insignificant for both samples. Unfortunately serological tests for viral antibodies were not done. Sputum smear and culture were not done because the patient's cough was non-productive. However, based on the four-fold decrease in antibody titre to *Chlamydia pneumoniae* and the absence of significant antibodies to *Mycoplasma pneumoniae* and *Legionella pneumophila* in a case of atypical pneumonia plus the response of the patient to a course of erythromycin, it was concluded that *C. pneumoniae* was the aetiological agent.

Population antibody study that have been carried out suggest that *C. pneumoniae* antibody is more common in tropical countries like Panama and Taiwan⁽⁵⁾. The epidemiology and clinical spectrum of *C. pneumoniae* infections in Malaysia is still unknown. This first confirmed *C. pneumoniae* pneumonia seen in a private clinic showed that it is probably quite common in this country especially when the serological findings were consistent with an acute reinfection. More studies are required to determine the prevalence of this infection and its frequency in relation to other respiratory pathogens so that these cases can be better managed.

ACKNOWLEDGEMENT

The author thank the Director of the Institute for Medical Research, Dato' Dr M Jegathesan, for permission to publish the paper and Mrs Norangizan for typing the manuscript.

REFERENCES

1. Grayston JT, Diwan VK, Cooney M, Wang SP. Community and hospital acquired pneumonia associated with *Chlamydia* TWAR infection demonstrated serologically. Arch Intern Med 1989; 149 : 169-73.
2. Chirgwin K, Roblin PM, Gelling M, Hammerschlag MR, Schachter J. Infection with *Chlamydia pneumoniae* in Brooklyn. J Infect Dis 1991; 163 : 757-61.
3. Bass JB. *Chlamydia pneumoniae* Pneumonia, strain TWAR. Pulmonary Perspectives 1990; 7: 4-7.
4. Holland SM, Gaydos CA, Quinn TC. Detection and differentiation of *Chlamydia trachomatis*, *Chlamydia psittaci* and *Chlamydia pneumoniae* by DNA amplification. J Infect Dis 1990; 162 : 984-7.
5. Grayston JT. *Chlamydia pneumoniae*, strain TWAR. Chest 1989; 95 : 664-9.

THE IXTH BIENNIAL SCIENTIFIC MEETING

organised by the Asian Pacific Association
for the Study of the Liver

Date : 27 - 29 January 1994

Venue : Kuala Lumpur, Malaysia

For further enquiries, please contact:

The IXth Bienial Scientific Meeting APASL
Suite 11, Ground Floor
Pantai Medical Centre
No. 8 Jalan Bukit Pantai
59100 Kuala Lumpur
Malaysia
Tel : (03) 2821753 or 2821777
Fax : (603) 2821753