

# ASCARID WORMS CAUSING RECURRENT CHOLANGITIS IN A PATIENT WITH AN OBSTRUCTING AMPULLARY TUMOUR

T F Toufeeq Khan, A Zahari, Z A Sherazi, R Visvanathan

## ABSTRACT

This is a report of a 57-year-old Malay lady who presented with recurrent episodes of cholangitis and septicaemia. A dilated biliary tree caused by a stenosing periampullary tumour was found to contain adult round worms. A pancreatico-duodenectomy was performed following biliary decompression. Ascarid worms are a rare cause of cholangitis in malignant biliary obstruction.

**Keywords:** cholangitis, ascarid worms, periampullary tumour, pancreatico-duodenectomy.

SINGAPORE MED J 1993; Vol 34: 462-463

## INTRODUCTION

The presence of ascarid worms in the biliary tree proximal to an obstructing periampullary tumour with recurrent episodes of cholangitis is unusual and has not been previously reported.

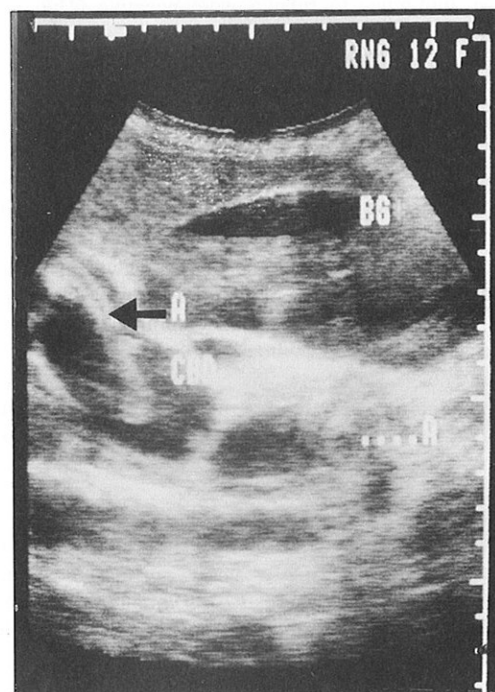
## CASE REPORT

A 57-year-old Malay lady was admitted with a 10-day history of abdominal pain, deepening jaundice and recurring fever with chills and rigors. There was a history of similar but milder episodes during the past 5 months. She was found to be deeply jaundiced, with a total serum bilirubin of 288 mmol/l, and hypotensive with a pyrexia of 39°C. She had an enlarged, tender liver with a palpable gall bladder. Her haemoglobin was 9.1 g/dl, a white cell count of 18000 per mm<sup>3</sup>, and serum alkaline phosphatase was 1685 IU/dl. With a diagnosis of acute cholangitis with septicaemia a combination of intravenous cefuroxime, gentamicin and metronidazole was commenced. Blood cultures on admission grew *E.Coli spp.* Ultrasonography of the biliary tree showed grossly dilated intra and extrahepatic ducts containing sludge and ascarid worms (Fig 1). She responded initially to the antimicrobial therapy but signs of sepsis reappeared after 10 days. The fever and jaundice settled following decompression of the biliary tract through a percutaneous transhepatic catheter.

Duodenoscopy revealed an ampullary tumour which on biopsy proved to be a well differentiated papillary adenocarcinoma. Endoscopic retrograde cholangiopancreatogram (ERCP) subsequently confirmed the presence of worms (Fig 2). Computerised tomography showed no evi-

Fig 1 - Ultrasound scan demonstrating a dilated biliary tree with Ascaris worms within the common bile duct.

A=Ascaris worms, BG=gall bladder, CBD=common bile duct.



dence of tumour involvement of the regional lymph nodes or the liver.

She underwent a Whipple pancreaticoduodenectomy and four dead, black round worms were removed from the intra and extra hepatic ducts (Fig 3). The resected specimen showed tumour infiltration of the duodenal wall while the pancreatic head and resection margins were free of tumour (Fig 4). She made an uneventful recovery and was discharged 19 days after surgery. She has been presently followed up for nine months and has remained well, gained weight and resumed normal activity.

## DISCUSSION

Malignant obstruction of the biliary tree produces cholangitis in 19% of patients<sup>(1)</sup>. Ascarid worms have been demonstrated within the bile ducts and gall bladder on ultrasonography<sup>(2,3)</sup>. They have also been observed emerging through the ampulla at endoscopy and have been postulated as a cause of cholangitis<sup>(4)</sup>. Round worm particles have been demonstrated in duct stones from patients in endemic areas<sup>(5,6)</sup>. Further, the

Department of Surgery  
School of Medical Science  
Hospital University Sains Malaysia  
Kubang Kerian 16150  
Kelantan  
Malaysia

T F Toufeeq Khan, FRCS(Edin)  
Associate Professor

A Zahari, MD  
Trainee Lecturer

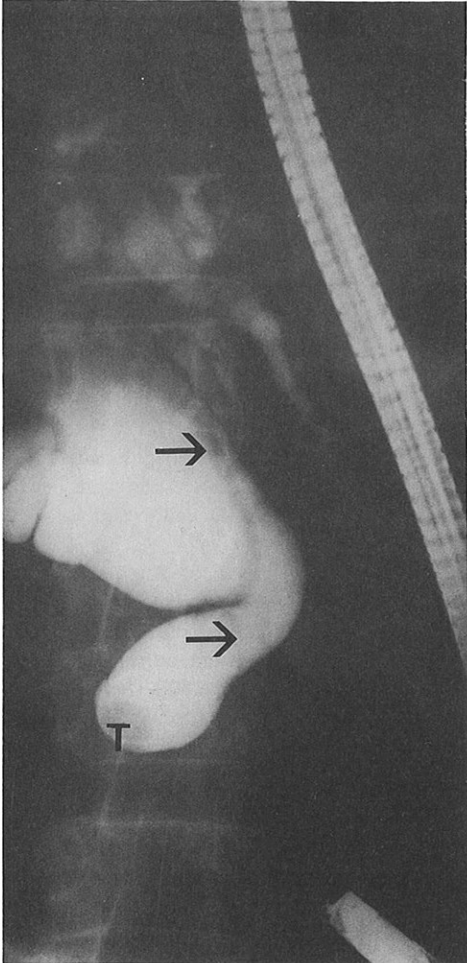
R Visvanathan, FRCS(Eng)  
Lecturer

Department of Radiology  
School of Medical Sciences  
Hospital University Sains Malaysia

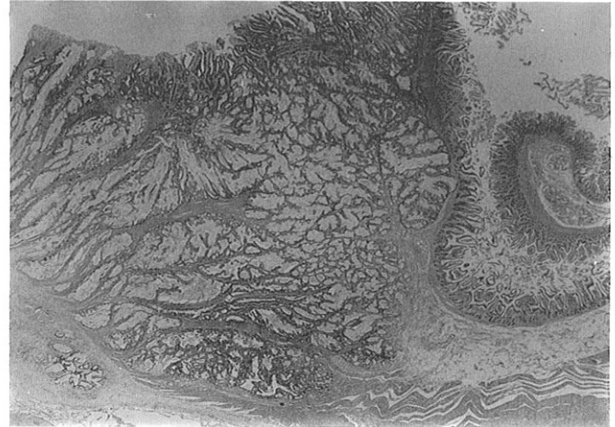Z A Sherazi, DMRD  
Lecturer

Correspondence to: Dr T F Toufeeq Khan

**Fig 2 - ERCP showing a grossly dilated bile duct with an adult Ascarid worm (arrows) and tumour (T).**



**Fig 4 - Photomicrograph of the part of the resection specimen showing invasion of the duodenal wall by adenocarcinoma (magnification x 40).**



absence of gall bladder stones in these patients suggests that ascarid worms in the bile ducts cause cholangitis and were responsible for the persisting biliary sepsis in the patient described. The coincidental finding of biliary ascariasis and malignant obstruction of the biliary tree has not been previously reported. Ascarid infestation in endemic areas may therefore play a significant role in the morbidity of patients with obstructive biliary pathology.

**REFERENCES**

1. Thompson JE, Tompkins RK, Longmire WP. Factors in the management of acute cholangitis. *Ann Surg* 1982; 195 : 137-45.
2. Khuroo MS, Zargar SA, Mahajan R. Sonographic appearances in biliary ascariasis. *Gastroenterology* 1987 ; 93 : 267-72.
3. Kamath PS, Joseph DC, Chandran R, et al. Biliary ascariasis : Ultrasonography, endoscopic retrograde cholangiopancreatography and biliary drainage. *Gastroenterology* 1986; 91:730-2.
4. Khuroo MS, Zargar SA. Biliary ascariasis: A common cause of biliary and pancreatic disease in an endemic area. *Gastroenterology* 1985; 88:418-23.
5. Maki T. Pathogenesis of calcium bilirubinate gallstone: role of *E.coli*, B-glucuronidase and coagulation by inorganic ions, polyelectrolytes and agitation. *Ann Surg* 1966; 164:90-100.
6. Teoh TB. A study of gallstones and included worms in recurrent pyogenic cholangitis. *J Path Bact* 1963;86:123-9.

**Fig 3 - Ascaris Lumbricoides removed at operation.**

