

THE FALSE POSITIVE LACHMAN TEST

V P Kumar, K Satku

ABSTRACT

Five patients with isolated rupture of the posterior cruciate injury following road traffic accidents were noted to demonstrate a "positive Lachman test". Stress radiographs while performing the Lachman manoeuvre confirmed that all 5 patients had only a posterior cruciate injury. Attention is drawn to the "false positive Lachman test" that indicates a posterior cruciate injury. The presence of a sag sign also establishes a diagnosis of posterior cruciate rupture and a positive Lachman test in this situation must be interpreted with caution.

Keywords: posterior cruciate injury, Lachman test

SINGAPORE MED J 1993; Vol 34: 551-552

INTRODUCTION

The reliability of the Lachman test and its increased accuracy over the anterior drawer sign for detecting anterior cruciate ligament rupture has been attested to by Torg, Conrad and Kalen⁽¹⁾ and Warren⁽²⁾. It is simple to perform and may be carried out without anaesthesia. The pivot shift test⁽³⁾ and its variations⁽⁴⁾ on the other hand are difficult to perform and without anaesthesia are negative in a large percentage of acutely injured knees⁽²⁾. The Lachman test has hence acquired a greater practical application for the diagnosis of anterior cruciate ligament disruption.

For the posterior cruciate injury, the posterior sag sign⁽⁵⁾ is reliable and diagnostic. Attention has been drawn to the false positive anterior drawer sign in the presence of a posterior cruciate injury. We have observed a similar phenomenon, a false positive Lachman sign in the presence of posterior cruciate ligament disruption. We report here five cases.

MATERIALS AND METHODS

Five patients were assessed using the Lachman manoeuvre.

All five sustained the injury in road traffic accidents. Their ages ranged from 21 to 35 years with an average of 25.5 years. All were males.

When first seen all patients had evidence of a posterior cruciate rupture in the form of a posterior sag. Except for grade 1 laxity of the medial collateral ligament in Case 1, no evidence of other ligament injury was detected in any of the patients. A mild to moderate effusion was evident in all five. Radiographs revealed no bony injury. All patients were managed conservatively.

Follow-up ranged from 3 to 5 years with an average of 4.5 years. No patient complained of locking, giving way or of swelling of the knee. Anterior knee pain was minimal in Cases 2 and 3. Examination revealed a posterior sag and a false positive anterior drawer test in all the patients. The Lachman test performed with the knee in ten degrees of flexion was also positive in all five but the pivot shift test was negative. The McMurray test was negative and no joint line tenderness was elicited.

Stress lateral radiographs of the affected knee was carried out while performing the Lachman manoeuvre. A lateral radiograph was taken as the proximal tibia was displaced posteriorly on the distal femur (Fig 1a and b) and repeated while the proximal tibia was drawn anteriorly as much as possible (Fig 2a and b). Tube to X-ray plate distance was standardised at 60 cm and X-rays were centred on the joint line.

Fig 1a – Posteriorly sagged proximal tibia in an almost fully extended knee.

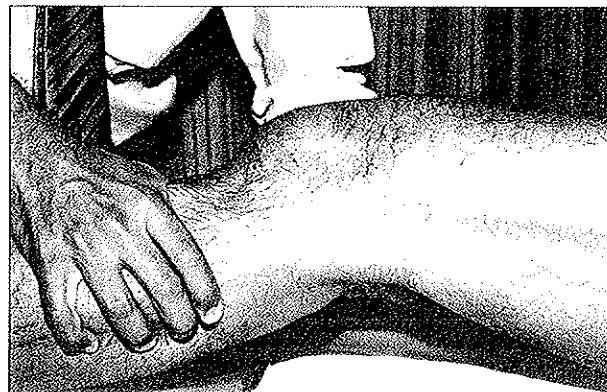
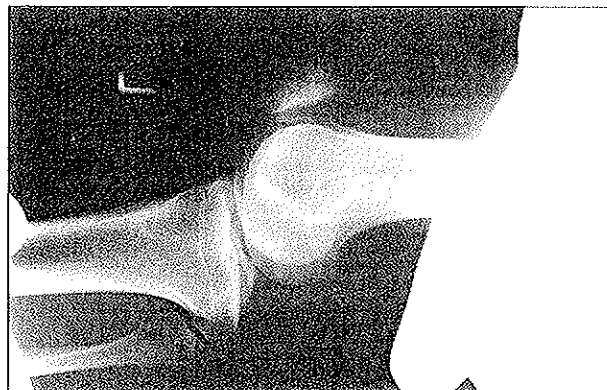


Fig 1b – Lateral radiograph showing the posteriorly sagged tibia.



RESULTS

The stress radiograph with a posteriorly directed force revealed posterior displacement of the proximal tibia in relation to the femur indicating a posterior cruciate laxity in all five Cases (Fig 1b). When the proximal tibia was drawn forward it returned to its normal relationship with the distal femur (Fig 2b). In none was the proximal tibia displaced further anteriorly relative to the distal femur indicating absence of anterior cruciate laxity.

The details of the five patients are shown in Table 1.

Department of Orthopaedic Surgery
National University Hospital
Lower Kent Ridge Road
Singapore 0511

V P Kumar, FRCS
Consultant Orthopaedic Surgeon

K Satku, FRCS
Consultant

Correspondence to: Dr V P Kumar

Fig 2a – Proximal tibia drawn forwards in the "False Positive Lachman Test". Note the tibia is now in its normal relationship with the femur.

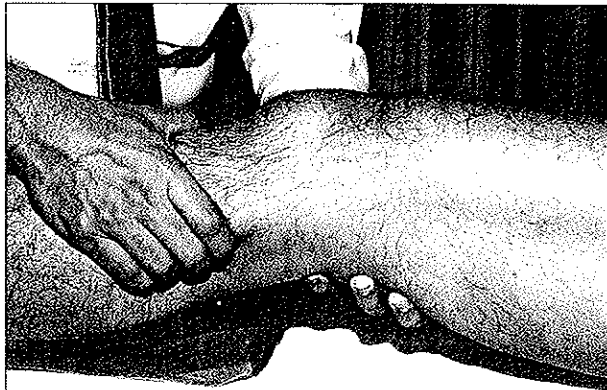


Fig 2b – Lateral radiograph showing the normal tibiofemoral relationship

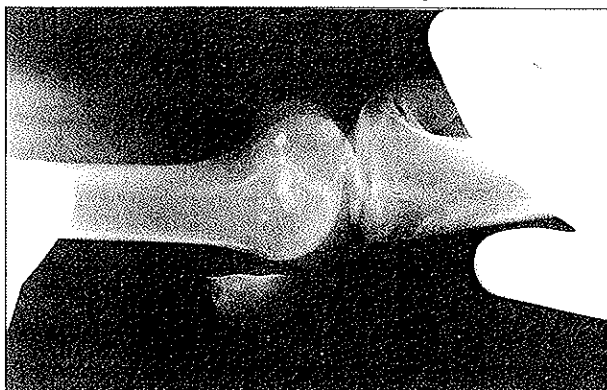


Table I – Results of clinical examination and stress radiographs for the five patients

Patient	Posterior Sag	False Positive Ant Drawer Test	"Lachman's Test"	Stress Radiograph	
				PCL	ACL
1	+	+	+	+	—
2	+	+	+	+	—
3	+	+	+	+	—
4	+	+	+	+	—
5	+	+	+	+	—

PCL: Posterior cruciate laxity

ACL: Anterior cruciate laxity

Arthroscopy carried out for 2 patients (Cases 2 and 3) with anterior knee pain revealed gross attenuation of the posterior cruciate ligament in both cases. The anterior cruciate was noted to be "lax", but taut when the tibia was drawn forward from its posteriorly sagged position. In this position the anterior cruciate ligament was noted to be of normal bulk and orientation consistent with that of a normal ligament. A magnetic resonance imaging in Case 5 confirmed an isolated posterior cruciate rupture.

DISCUSSION

We draw attention to the 'false positive Lachman test'. Staubli and Jakob⁽⁶⁾ alluded to this but failed to highlight it. When the knee was postured as for the Lachman manoeuvre, the proximal tibia had already subluxed posteriorly because of posterior cruciate insufficiency (Fig 1a and b). The Lachman test performed at this point will draw the tibia forward to its normal position (Fig 2a and b). The unwary clinician may interpret this as an anterior cruciate injury. Further, even at arthroscopy a "lax" anterior cruciate may be seen and interpreted by the inexperienced as an anterior cruciate injury, should the knee be posteriorly sagged during the procedure. The posterior cruciate even when it is attenuated and lax is often covered by synovium and its injury may be missed.

In conclusion we submit that the examination for ligament injury of the knee should commence with an assessment of the sag sign of Kennedy Roth and Walker⁽⁵⁾. Its presence will establish a posterior cruciate injury and a positive anterior drawer or Lachman sign must be interpreted with caution.

REFERENCES

1. Torg JS, Conrad W, Kalen V. Clinical diagnosis of anterior cruciate ligament instability in the athlete. *Am J Sports Med* 1976; 4: 84-93.
2. Warren RF. Acute ligament injuries. In: Insall J, ed. *Surgery of the knee*. New York: Churchill Livingstone, 1984: 261-94.
3. Slocum DB, James SL, Larson RL, Sanger KM. Clinical test for anterolateral rotary instability of the knee. *Chin Orthop* 1976; 118: 63-9.
4. Losee RE, Johanson TR, Southwick WO. Anterior subluxation of the lateral tibial plateau: A diagnostic test and operative repair. *J Bone Joint Surg (Am)* 1978; 60A: 1015-30.
5. Kennedy JC, Roth JH, Walker DM. Posterior cruciate ligament injuries. *Orthop Digest* 1979; 7: 19-31.
6. Staubli HU, Jakob RP. Posterior instability of the knee near extension. A clinical and stress radiographic analysis of acute injuries of the posterior cruciate ligament. *J Bone Joint Surg (Br)* 1990; 72B: 225-30.