

ACCIDENTAL CANNULATION OF THE HEPATIC VEIN DURING PULMONARY ARTERY CATHETERISATION - A CASE REPORT

V G Reddy, B George

ABSTRACT

A 22-year-old male was admitted to the adult ICU with a diagnosis of massive cardiomegaly and a large left ventricular thrombus, and needed Swan-Ganz catheterisation for proper haemodynamic monitoring. Insertion of the Swan-Ganz catheter resulted in hepatic vein cannulation. Pulmonary artery was successfully cannulated only when the patient was put in the headup and right lateral position. It is suggested that to increase the success rate of patients with low cardiac output, cardiomegaly or pulmonary hypertension, they be placed in a headup and right lateral position.

Keywords: malposition, pulmonary artery catheter, Swan-Ganz, hepatic vein

SINGAPORE MED J 1993; Vol 34: 561-562

INTRODUCTION

The use of pulmonary artery catheters (PA) has been of great value in monitoring pulmonary wedge pressure and guiding fluid and vasoactive drug therapy in the critically ill. Unfortunately insertion of such catheters is not risk free. The reported complications related to the use of flow directed balloon tipped catheters are extensive and well documented. One such complication is malposition⁽¹⁾. We wish to report an unusual malposition of Swan-Ganz catheter in the hepatic vein and ways to overcome the problem.

CASE REPORT

A 22-year-old male was admitted to the Surgical Ward with acute onset of epigastric pain with a tentative diagnosis of acid peptic disease or acute pancreatitis. Investigations revealed no pathology. On the 7th day of admission he suddenly became violent, disoriented and breathless. On examination there were no palpable peripheral pulses, feeble carotid and femoral pulses. Heart rate was 120 beats/min, BP was 90/60 mmHg, respiratory rate 36/min. Auscultation of the chest revealed minimal inspiratory crackles. Cardiac examination demonstrated flat neck veins at 45° and tachycardia with normal heart sounds. The abdomen was not tender with a mildly tender and enlarged liver of 3 cm. The patient was immediately transferred to the ICU for resuscitation and haemodynamic monitoring.

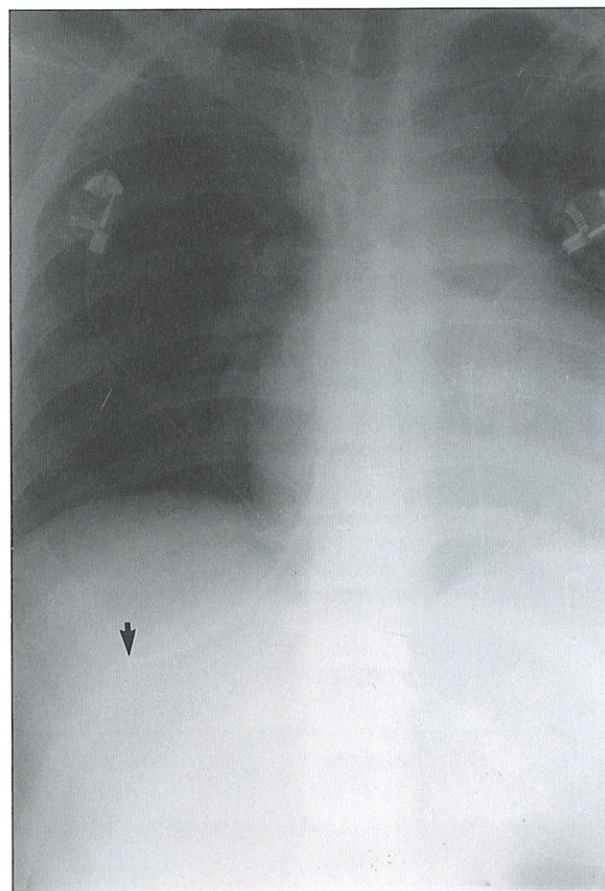
The patient initially responded to fluid load and dopamine with the return of peripheral pulses and improvement in peripheral perfusion. After 30 minutes he deteriorated again with dyspnoea, fall in blood pressure and tachycardia. Portable X-ray showed massive cardiomegaly and mild pulmonary congestion. 12-lead ECG revealed sinus tachycardia and anteriolateral ischaemia. Echocardiography showed poor ventricular ejection fraction with a large thrombus in the left ventricle. It was decided to insert a Swan-Ganz catheter to assess and for further management. We used a Spectramed penta cath SP5507H 7.5 thermodilution catheter with Spectramed introducer 010177 Fr

with Gould P₂3 pressure transducer and Siemens Sirecrest 404-1 three channel monitor.

After checking the equipment, catheters and integrity of the balloon, the Swan-Ganz catheter was inserted under strict aseptic conditions with continuous monitoring of the patient.

The patient was positioned 30° head down tilt with his head turned to the left. In an attempt to minimise the risk of venous air embolism, a PA catheter introducer with self healing diaphragm was inserted without any trauma into the right internal jugular vein using the Seldinger technique. The Swan-Ganz catheter was laid in its resting coil shape so that advancement would result in anticlockwise passage of the tip through the right heart into the right pulmonary artery⁽²⁾. At 15 cm the balloon was inflated with

Fig 1 – Showing the tip of the pulmonary artery catheter in the hepatic vein



Department of Anaesthesia and Intensive Care
Sultan Qaboos University Hospital
P O Box 32485
Al Khod, MUSCAT
Sultanate of Oman

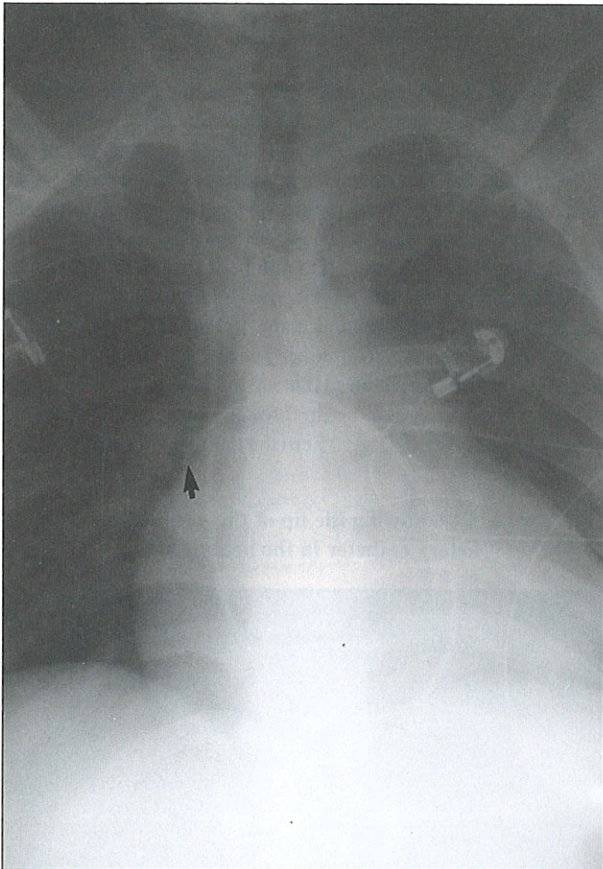
V G Reddy, MBBS, MD
Assistant Professor

B George, MBBS, MD
Registrar

Correspondence to: Dr V G Reddy

1.5 ml of air and gently advanced under pressure guidance. The tracing was consistent with that of the superior vena cava but failed to change to right atrial tracing or right ventricular tracing. At 60 cm it looked as if it had wedged with a pressure of 28 mmHg. Deflation of the balloon changed the pressure reading to 25 mmHg. The Swan-Ganz catheter was withdrawn to the 15 cm marking and reinserted with the same result. An X-ray taken to confirm the position of the tip of the catheter showed it to be in the hepatic vein (Fig 1). The balloon was deflated and the catheter withdrawn to the 15 cm marking. The patient was positioned in

Fig 2 – Showing the pulmonary artery catheter in the right pulmonary artery



a 20° head up and right lateral tilt position and the catheter was reinserted⁽³⁾. This time the tracing changed as it entered the right atrium, right ventricle, followed by pulmonary artery. Repeat X-ray confirmed the proper position of the catheter in the right pulmonary artery (Fig 2).

DISCUSSION

Malposition is one of the complications of central venous cannulation or pulmonary artery cannulation. Langston⁽⁴⁾ while using arm veins for central venous cannulation reported various malpositions and one of them was in the hepatic vein. Accidental hepatic cannulation by a Swan-Ganz catheter has not been reported though Insel⁽⁵⁾ deliberately used Swan-Ganz catheters into the hepatic vein prior to pulmonary artery catheterisation in order to evaluate patients with anasarca.

Factors predisposing to difficult pulmonary artery catheter placement include low cardiac output, enlarged right ventricular cavity and pulmonary hypertension⁽⁶⁾. The above mentioned patient had low blood pressure, low cardiac output, massive cardiomegaly and pulmonary hypertension. When a patient is placed in the right lateral position the pulmonary valve becomes the most superiorly located structure in the right ventricle. This might allow the air filled balloon to float promptly through the right ventricular outflow tract and into the pulmonary artery⁽⁶⁾.

Hence it is suggested that if the patient were to have any predisposing factors as mentioned above the catheterisation of the pulmonary artery may be easily done in the right lateral headup position. If the catheter during its passage after 25 cm fails to show a typical right atrial tracing one should have high suspicion of its direction.

ACKNOWLEDGEMENT

We thank the Hospital Director for his permission to publish this article.

REFERENCES

1. Weideman HP, Matthay MA, Matthay RA. Cardiovascular pulmonary monitoring in the intensive care unit. *Chest* 1984; 85: 537-42.
2. Pierce T, Woodcock T. How to insert a pulmonary arterial flotation catheter. *Br J Hosp Med* 1989; 42: 485-7.
3. Keusch DJ, Winters S, Thys DM. The patient's position influences the incidence of dysrhythmias during pulmonary artery catheterisation. *Anaesthesiology* 1989; 70: 582-4.
4. Langston CS. The aberrant central venous catheter and its complications. *Radiology* 1971; 100: 55-9.
5. Insel JM, Mookherjee S, Smulyan H, Warner R. Use of hepatic vein catheterisation in the evaluation of patients with anasarca. *Am J Med Sci* 1990; 299: 245-9.
6. Sprung CL, Jaqcobs LJ, Caralis PV, Karpf M. Ventricular arrhythmias during Swan Ganz catheterisation of the critically ill. *Chest* 1981; 79: 43-5.