

CONGENITAL POSTERIOR MEDIASTINAL TERATOMA – A CASE REPORT

M H Harun, I Yaacob

ABSTRACT

Almost all mediastinal teratomas are found in the anterior mediastinum. We describe a case of a 41-day-old baby girl who had teratoma in the posterior mediastinum. She presented at the age of 6 days with the problem of progressive jaundice and was found to have septicaemia. During septic screening, chest X-ray revealed a mass in the right mediastinum. Ultrasound and CT-scan of the chest showed a multiloculated mass at the right posterior mediastinum. Fine needle aspiration biopsy of the mass confirmed a teratoma.

Keywords: teratoma, congenital, mediastinum, posterior.

SINGAPORE MED J 1993; Vol 34: 567-568

INTRODUCTION

Teratomas are congenital tumours arising from pluripotent cells. These tumours most often occur in a para-axial or midline location. About 10% occur in the mediastinum, where almost 100% are in the anterior mediastinum.

In this paper, we described a case of congenital teratoma which was located in the posterior mediastinum in a newborn child.

CASE REPORT

A 41-day-old baby girl was referred to Hospital Universiti Sains Malaysia for further management of a mediastinal mass. At the age of 6 days, she was admitted to the General Hospital Kota Bharu with progressive jaundice, poor feeding, persistent indirect hyperbilirubinaemia and pancytopenia. Blood culture grew *Enterobacter* species. After treatment with antibiotics, exchange transfusion and other supportive therapy, the patient made a good recovery.

However, during septic screening, a right-sided intrathoracic mass was noted on the Chest X-ray (Fig 1). An ultrasound and CT scan of the chest were done and revealed a multiloculated mass measuring 23 X 28 mm in the right posterior mediastinum (Fig 2). Barium meal showed no displacement or indentation of oesophagus. Fine needle aspiration biopsy of the mass was done and the histology showed glandular and squamous epithelium compatible with teratoma (Fig 3).

Unfortunately, before further work-up such as serum alpha-fetoprotein and surgical excision could be performed, the baby was lost to follow-up as the parents refused further investigations and treatment.

Fig 1 – Chest X-ray: Right sided intrathoracic mass

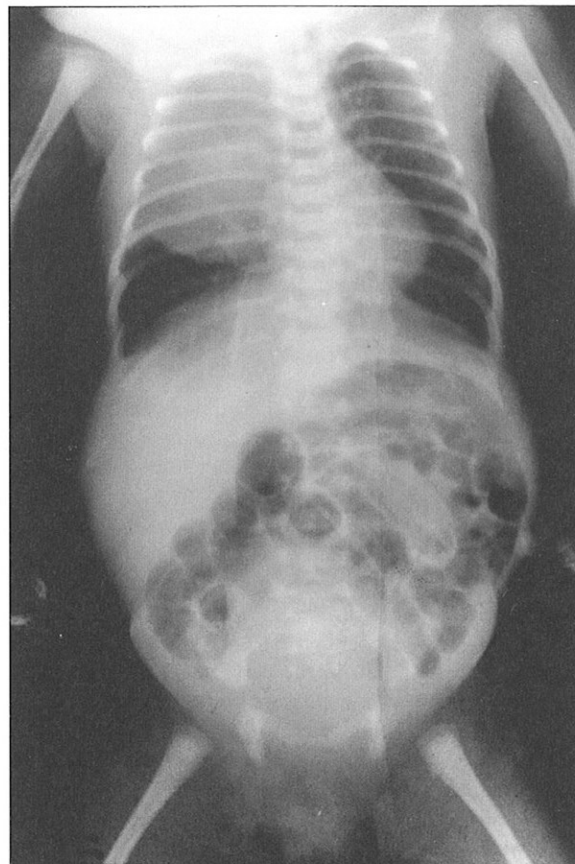
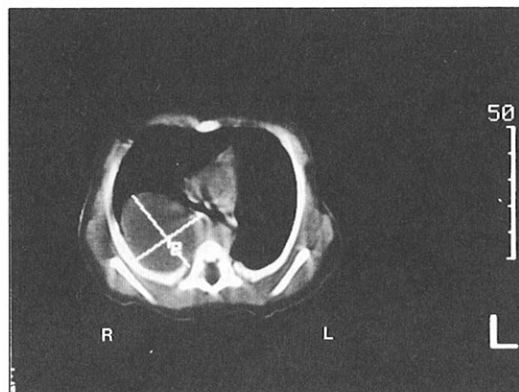

Fig 2 – CT scan of the chest: Capsulated multiloculated mass 23 x 28 mm in right posterior mediastinum occupying left upper and mid zone.



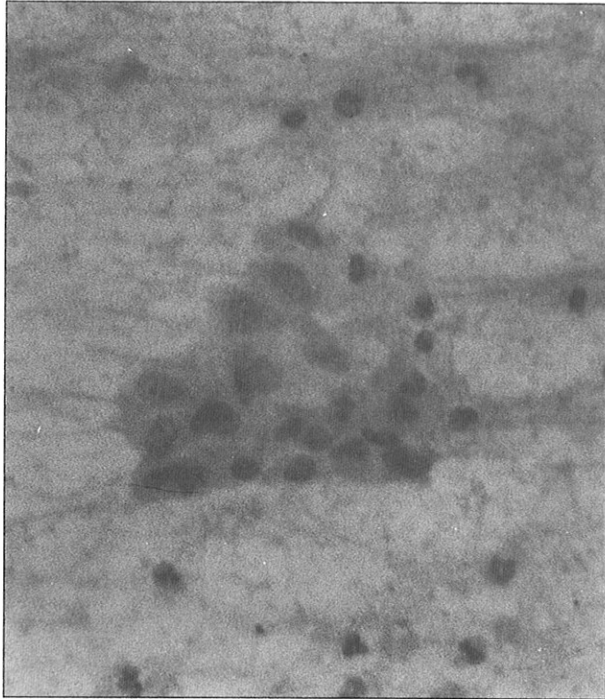
Department of Medicine
Hospital Universiti Sains Malaysia
Kubang Kerian 16150
Kelantan
Malaysia

M H Harun, MD (UKM)
Registrar

I Yaacob, FRCPI
Chest Physician and Lecturer

Correspondence to: Dr M H Harun

Fig 3 – FNAB: Sheets of glandular epithelium and occasional squamous epithelial cells (X250 Papanicolaou's stain)



DICUSSION

Teratomas account for about 3% of all childhood tumours^(1,2). A study of 4,357 patients with primary mediastinal tumours and cysts in Northern China showed that teratomas are the most common of the mediastinal tumours and cysts⁽³⁾. Ellis and DuShane found that 27.6% of mediastinal tumours in infants were teratomas⁽⁴⁾.

Grosfeld et al found that of 85 cases of teratoma in childhood, 64.8% were located in the sacrococcygeal region, 11.7% in the gonads, 11.7% mediastinal, 4.8% presacral, 3.5% retroperitoneal and 3.5% in the cervical region⁽⁵⁾. Similarly, Billmire et al found that mediastinal teratomas accounted for about 10% of all teratomas occurring in infants and children⁽⁶⁾. The location of teratoma at the posterior mediastinum in this patient is unusual. Grosfeld and colleagues in two separate studies, found that all the 24 mediastinal teratomas in their studies were sited in the anterior mediastinum^(5,6). There have been only 8 cases of posterior mediastinal teratomas reported in the world's literature⁽⁷⁾.

Teratomas of the mediastinum may be classified into (1)

benign cystic teratomas, (2) benign teratomas (solid), and (3) teratocarcinoma. The majority of teratomas are benign^(2,4,8). Of the 16 teratomas reported by Ellis and DuShane, 8 (50%) were benign teratomas, 5 (30%) were cystic teratomas, and 3 (20%) were teratocarcinoma⁽⁴⁾. Overall, a 28% incidence of malignancy was noted. The risk of malignancy depends on a few factors including the anatomic sites of the lesion and the age of the patient^(5,6). Presacral teratomas have the greatest potential for malignancy^(8,9). No malignant teratomas arising in the neck, oropharynx or stomach have been reported in childhood. The age of the patient at the time of the diagnosis is a significant risk factor for malignancy in sacrococcygeal teratomas. However, there was no direct effect of age as a prognostic factor in teratomas in other locations⁽⁵⁾. Serum alpha fetoprotein appears to be an excellent indicator of the presence of a malignant tumour. It may be a useful screening test in evaluating malignant teratoma and in children with established malignancies, alpha fetoprotein level has been shown to be a reliable marker for disease activity⁽⁵⁾. The size of the tumour and the presence of cystic or solid components are not accurate indicators of a malignant process⁽⁵⁾.

Surgical excision alone may be the treatment in benign cases. In benign cases, complete excision gave a 97% survival rate⁽⁶⁾. In malignant cases, multiple agent chemotherapy and surveillance with tumour markers have improved both recognition of relapse and survival. The cyclic chemotherapy used has included actinomycin-D, vincristine, cyclophosphamide and methotrexate⁽⁶⁾. When treated with surgical excision alone, there is nearly universal recurrence and death in malignant mediastinal tumours⁽⁶⁾.

Surgical removal of the tumour was advised for this patient ± multiple agent chemotherapy depending on histologic study of tumour after tumour removal. However, the patient's parents refused further treatment and the patient has been lost to follow-up.

REFERENCES

1. Talmi YP, Sadow R, Dulitky F, Finkelstein Y, Zohar Y. Teratoma of the mastoid region in a newborn. *J Laryngol Otol* 1988; 102: 1033-5.
2. Brooks JW. Tumours of the chest. In: Kendig Jr EL, ed. *Disorders of the respiratory tract in children*, 3rd ed. Philadelphia: WB Saunders Company 1977: 726-7.
3. Zeng LQ, Liu QX, Zhang CY, Wang TS, Shou HS, Yi NT, et al. The changing patterns of occurrence and management in primary mediastinal tumours and cysts in the People's Republic of China. *Surg Gynecol Obstet* 1988; 166: 55-9.
4. Ellis FH Jr, DuShane JW. Primary mediastinal cysts and neoplasms in infants and children. *Am Rev Tuberc Pulmon Dis* 1956; 74:940.
5. Grosfeld JL, Ballantine TVN, Lowe D, Baehner RL. Benign and malignant teratomas in children: Analysis of 95 patients. *Surgery* 1976; 80: 297-305.
6. Billmire DF, Grosfeld JL. Teratomas in childhood: Analysis of 142 cases. *J Paed Surg* 1986; 21: 548-51.
7. Karl SR, Dunn J. Posterior mediastinal teratomas. *J Paed Surg* 1985; 20: 508-10.
8. Harms D, Janig U. Immature teratomas of childhood. *Pathol Res Pract* 1985; 179: 388-400.
9. Ganick DJ, Gilbert EF, Opitz JM. Teratomas in children and young adults. *Med Paediatr Oncol* 1979; 6: 235-42.