

ELECTROCARDIOGRAPHIC CASE

BUNDLE BRANCH BLOCK AND SYNCOPES?

C Barendra, W S Teo

CASE REPORT

An 84-year-old Indian man was admitted with a history of recurrent episodes of giddiness for the last 5 years. He also had 3 previous episodes of transient loss of consciousness. He has a history of hypertension for the past 28 years and angina pectoris for the past 10 years. The clinical examination was unremarkable and no postural hypotension was detected. The electrocardiogram is illustrated in Fig 1.

What is your diagnosis? (Answer on page 576)

SINGAPORE MED J 1993; Vol 34: 560

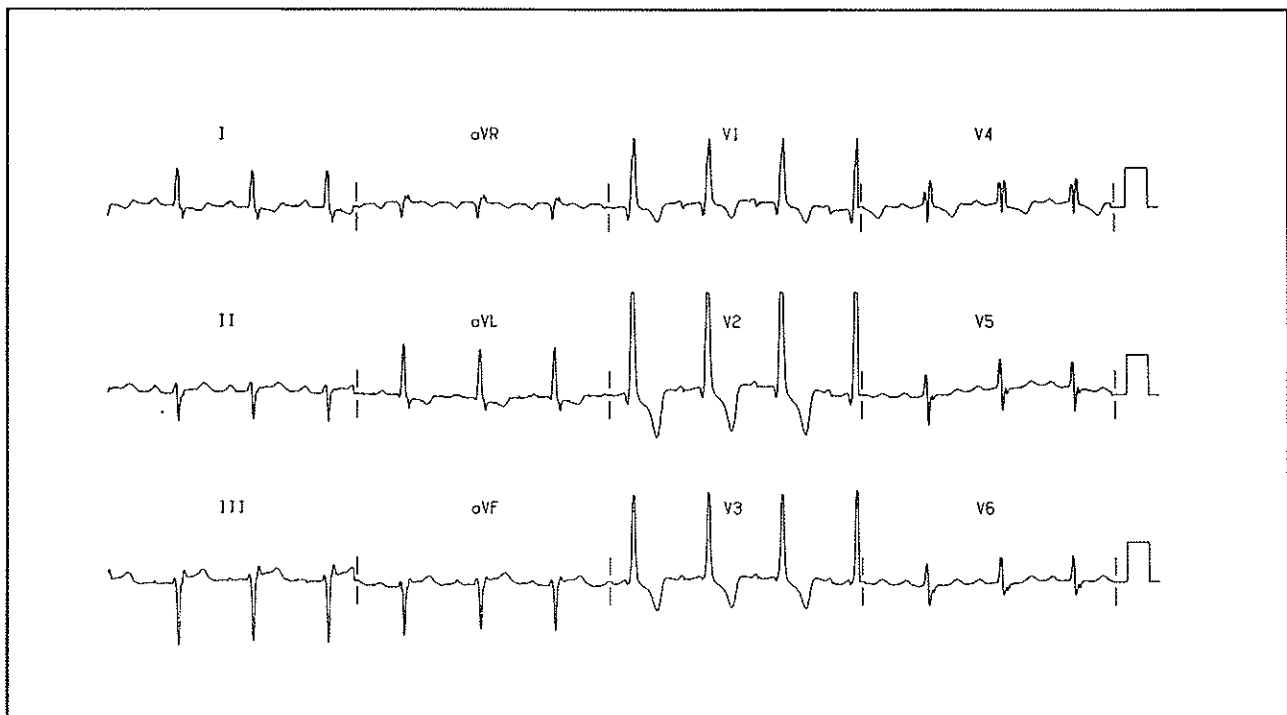


Fig 1 – 12 lead electrocardiogram on admission to hospital

Department of Cardiology
Singapore General Hospital
Outram Road
Singapore 0316

C Barendra, MBBS, FCPS (Int Med)
Registrar

W S Teo, MBBS, M Med (Int Med), MRCP (UK), FAMS
Consultant

Correspondence to: Dr W S Teo