

# MECONIUM ILEUS – A RARE CAUSE OF NEONATAL INTESTINAL OBSTRUCTION IN MALAYSIA

C T Lim, C H Yip, K W Chang

## ABSTRACT

*Meconium ileus, rare in Malaysia, accounts for 3.7% of all neonatal intestinal obstructions (excluding imperforate anus) seen in the University Hospital, Kuala Lumpur, from 1980-1990. This paper retrospectively reviews our clinical experience with 5 cases of meconium ileus seen over a 12-year period from 1980-1991 in the University Hospital, Kuala Lumpur. Three of the neonates were Malays, and two were Punjabis. Four of them were full-term and one preterm. The birth weights ranged from 1900 to 3700 g, with a mean of 2670 g. One of them also had a sibling with meconium ileus. Two of them were found to have foetal ascites and one had intestinal obstruction, antenatally by ultrasonography. The remaining two were symptomatic soon after birth. Extensive calcification was observed on plain abdominal radiographs in three babies and dilated bowels in the other two. All of them underwent laparotomy and uncomplicated meconium ileus was confirmed in two cases, meconium peritonitis in two and one meconium pseudocyst in addition to meconium peritonitis. There was one intraoperative death, and one long-term survivor who did not have cystic fibrosis. The remaining three did not have additional features suggestive of cystic fibrosis, and finally succumbed to respiratory infection. Sweat test was not done to confirm the diagnosis for logistic reasons. The management of such patients proved to be a challenge to clinicians because of the rarity of this condition.*

**Keywords:** meconium ileus, meconium peritonitis, cystic fibrosis, intestinal obstruction, neonatal

SINGAPORE MED J 1994; Vol 35: 74-76

## INTRODUCTION

Meconium ileus (MI), a well recognised cause of neonatal intestinal obstruction, is uncommon in Malaysia. Most of the cases of MI in the literature are associated with cystic fibrosis (CF). MI can also occur without CF<sup>(1-3)</sup> and familial cases of MI had also been reported<sup>(4)</sup>.

MI is small bowel obstruction caused by inspissated meconium usually at the level of the terminal ileum. The abnormally viscid meconium is the result of thick mucous produced in the mucous glands of the gastrointestinal tract<sup>(5)</sup>. In half of the patients, MI is complicated by in-utero intestinal perforation resulting in meconium peritonitis, gangrene, atresia, or volvulus of small bowel with the formation of meconium pseudocyst<sup>(6)</sup>.

Five cases of MI seen in University Hospital, Kuala Lumpur from 1980-1991, a 12-year period, were reviewed with respect to clinical presentation, investigation and surgical management.

## MATERIALS AND METHODS

The identifying data of patients diagnosed to have meconium ileus (MI) were obtained from the admission records of the special care nursery, paediatric wards and operative records of University Hospital, Kuala Lumpur, from 1980-1991, a 12-year period. These case records were then retrieved from the Medical Record Unit and reviewed retrospectively with respect to clinical presentation, investigation and surgical management.

## RESULTS

### Clinical presentation

The clinical presentations of the five cases were summarised in

---

Department of Paediatrics  
University Hospital  
59100 Kuala Lumpur  
Malaysia

C T Lim, MCRP  
Lecturer

C H Yip, FRCS  
Lecturer

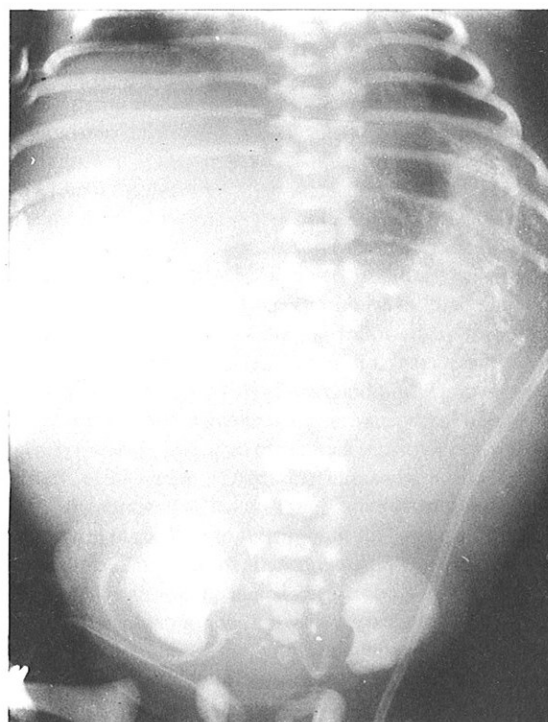
K W Chang, FRCS  
Associate Professor

Correspondence to: Dr C T Lim

---

Table I. Antenatal ultrasonography showed evidence of foetal ascites in Cases 1 and 5 and intestinal obstruction in Case 4. Postnatally, all these babies had intestinal obstruction. Plain abdominal radiograph revealed extensive calcification in Cases 1 and 5 (Fig 1). An opaque mass with a calcified rim suggestive of a meconium pseudocyst was seen in Case 4, which was also demonstrated on CT scan of the abdomen (Fig 2). In Cases 2 and 3 dilated bowels were seen on plain abdominal radiograph and diagnosed as ileal atresia and Hirschsprung disease respectively. A gastrograffin enema was subsequently performed in Case 3 showing stringy filling defects in the colon suggestive of meconium ileus. Gastrograffin enema however failed to disimpact the obstruction.

**Fig 1 – Abdominal radiograph of Case 5 showing calcification in the abdomen suggestive of meconium peritonitis.**

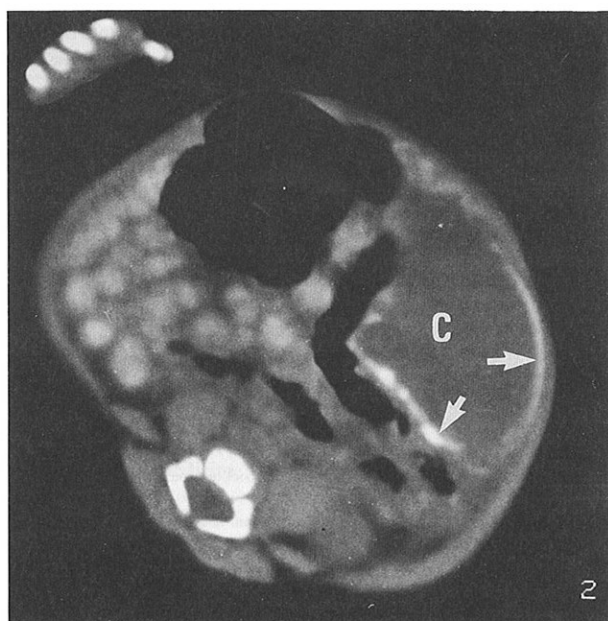


**Table I – Clinical features, investigation, surgical management and outcome of 5 cases with meconium ileus**

	Case 1	Case 2	Case 3	Case 4	Case 5
Ethnic group	Malay	Punjabi	Punjabi	Malay	Malay
Sex	female	male	male	male	male
Maturity	full term	full term	full term	full term	preterm 34 weeks
Birth weight	2060 g	2520 g	3200 g	3700 g	1900 g
Family history	nil	nil	1 sibling died from pneumonia	1 sibling had MI died from pneumonia	nil
Clinical feature	antenatal U/S foetal ascites	intestinal obstruction	intestinal obstruction	antenatal U/S dilated bowels	antenatal U/S foetal ascites
Investigations	AXR: Calcification U/S: meconium peritonitis	AXR: dilated bowels	AXR: dilated bowels gastrograffin: meconium ileus	AXR: opaquemers calcified rim CT scan: meconium pseudocyst	AXR: calcification
Laparotomy findings	MI, meconium peritonitis	MI	MI	meconium pseudocyst	MI, meconium peritonitis
Other features	nil	FTT, diarrhoea bronchopneumonia	FTT, diarrhoea obstructive jaundice bronchopneumonia	diarrhoea, obstructive jaundice bronchopneumonia	nil
Sweat test	normal results	not done	not done	not done	nil
Outcome	alive and well at 8 years	died at age 11 weeks, bronchopneumonia, sepsis	died at 7 weeks, bronchopneumonia, sepsis	died at 7 weeks, bronchopneumonia, sepsis	operative mortality

NB: AXR = abdominal X-ray; U/S = ultrasonography; MI = meconium ileus; CT scan = computerised tomography; FTT = failure to thrive.

**Fig 2 – Computerised tomography of the abdomen of Case 4 showing a cyst (C) on the left side of the abdomen with a calcified rim (arrows) suggestive of a meconium pseudocyst.**



#### Surgical management

All these cases were operated on. The findings were uncomplicated MI in Cases 2 and 3, meconium peritonitis in Cases 1 and 5 and meconium pseudocyst in Case 4. Bishop-Koop procedure was performed in all in addition to resection of pseudocyst in Case 4. There was unfortunately one intraoperative mortality, Case 5, a preterm infant.

#### Investigations for cystic fibrosis

A sweat test and stool trypsin level to exclude cystic fibrosis were done in only one patient (Case 1). The results were normal, thus excluding CF as an aetiology. She is thriving well at age 8 years.

Unfortunately, the other three cases were not investigated for cystic fibrosis because when readmitted, they were either too sick or because technical problems precluded the performance of the sweat test. However, there were evidence to suggest that MI could be related to CF. Case 4 had a sibling who also had MI operated overseas and died of bronchopneumonia at the age of 26 days. All these three babies had failure to thrive. In addition, Cases 2 and 3 had chronic diarrhoea and fat globules were seen in the stool suggestive of steatorrhoea. Cases 3 and 4 also had obstructive jaundice. Cholangiogram done in Case 4 showed obstruction of the biliary tree probably by inspissated bile. Liver biopsy done revealed cholestasis with cytoplasmic retention of bile pigment and feathery degeneration of hepatocytes, consistent with that seen in CF. All three of these eventually died of bronchopneumonia, 2 at 7 weeks, one at 11 weeks of age. A combination of MI, chronic diarrhoea, failure to thrive, obstructive jaundice and recurrent chest infection was suggestive of cystic fibrosis.

#### DISCUSSION

Compared to results from Western countries, where the incidence of MI is about 10% of neonatal intestinal obstruction (excluding imperforate anus)<sup>(7-9)</sup>, MI accounts for only 3.7% of all neonatal intestinal obstruction (excluding imperforate anus) seen in University Hospital, Kuala Lumpur, during the period 1980-1990 (Table II, unpublished data). A similar report from Nigeria<sup>(10)</sup>, also noted absence of MI as a cause of neonatal intestinal obstruction.

Meconium ileus is almost always associated with cystic fibrosis (CF). Meconium ileus does occur in the absence of CF<sup>(5)</sup>. Rickham et al (1965)<sup>(3)</sup> reported 7 cases of MI presented with

intestinal obstruction in the early neonatal period. Of the five infants who survived, stool trypsin was present and the sweat chlorides were normal. Of the two who died, postmortem examination did not reveal evidence of CF. Dolan et al (1974)<sup>(4)</sup>, documented 2 full-term siblings with MI but there was no evidence of CF on history or physical examination and sweat electrolytes were normal. Hence MI may be familial and not related to CF.

In CF, there is an abnormality of the exocrine gland secretion, producing mucous secretions with abnormal physicochemical properties, causing it to precipitate and obstruct organ passages. The cardinal laboratory confirmation of CF is sweat test which shows an elevation in sweat chloride and sodium concentration<sup>(11)</sup>. CF, an autosomal recessive condition, occurs in 1:2000 live births among Caucasians. About 5% of Caucasians are carriers of the abnormal genes<sup>(12)</sup>. Fifteen percent of them present in the neonatal period with MI<sup>(13,14)</sup>.

**Table II – Neonatal intestinal obstruction: causes and relative frequencies (University Hospital, Kuala Lumpur 1980-1990, unpublished data)**

Causes	Number	Percent
Duodenal obstruction (duodenal atresia and malrotation)	40	30
Pyloric obstruction	28	21.1
Hirschsprung disease	21	15.8
Jejuno-ileal atresia	19	14.3
Volvulus neonatorum	9	6.8
Obstructed hernias	5	3.8
Meconium ileus	5	3.8
Intussusception	3	2.3
Foreign body	1	0.8
Prenatal perforation and adhesion	1	0.8
Duplication cyst of ileum	1	0.8
Total	133	

CF is however rare in people of Mongolian descent and in native African negroes<sup>(5)</sup>. Isolated cases had been documented in Singapore<sup>(15)</sup>, Japan<sup>(16)</sup> and the Indian subcontinent<sup>(17,18)</sup>. It is noteworthy that two of the patients (Cases 2 and 3) were Punjabi in origin, who are thought to be closer to Caucasians. However Yadav 1983<sup>(18)</sup> from Chandigarh, Punjab, only documented 6 cases of MI. 3 of them were thought to be associated with CF. The lack of reported cases among Asian countries could be due to a combination of underreporting and low incidence.

Meglumine diatrizoate (gastrograffin) enema has been used to disimpact the bowel and relieve the obstruction in uncomplicated MI<sup>(19)</sup>. However, several enemas may be required and some patients still require surgical disimpaction. In our patients, Bishop-Koop procedure was used in four with good results. This operation was first described in 1957<sup>(20)</sup> and involves resection of the most dilated portion of the ileum, an end-to-side proximal-to-distal ileo-ileal anastomosis, and the free end of the distal ileum brought out of the abdomen as an ileostomy. The stoma acts as a safety valve and can be used to instil gastrograffin to relieve any

residual blockage. This technique proved to be an important factor in the improvement in operative survival<sup>(21)</sup>. Because of the many complications of ileostomy management and closure, enterostomy and irrigation with 4% N-acetylcysteine have also been tried with good results<sup>(22)</sup>. However, multiple enterostomies may be required before the intestines can be cleared of inspissated meconium.

With improvement in surgical technique, paediatric anaesthesia, neonatal care, total parenteral nutrition and care of CF patients, the long-term survival of patients with meconium ileus have improved dramatically over the past 3 decades, mortality decreasing from 70% to less than 20%<sup>(6,9)</sup>. In our experience, there was only one long-term survivor (20%) and one operative mortality (20%).

## CONCLUSION

MI is a rare problem in Malaysia. Five cases were described. There was only one long term survivor, one patient died intra-operatively, and the three late mortalities had clinical features of CF although, for logistic reasons, a confirmatory sweat test could not be done. These three eventually died of respiratory complications. The management of such patients proved to be a challenge to both paediatrician and surgeon because of the rarity of this condition here and relative inexperience and lack of resources for the management of such patients.

## REFERENCES

- Rachagan SP, Lim CT, Chang KW, Kwan BB. Meconium peritonitis due to meconium ileus presenting as fetal ascites: a case report. *Asia-Oceania J Obstet Gynecol* 1989; 15: 117-20.
- Hinden E. Meconium ileus with no pancreatic abnormality. *Arch Dis Child* 1950; 25: 99-102
- Rickham PP, Boeckman CR. Neonatal meconium obstruction in the absence of mucoviscidosis. *Am J Surg* 1965; 109: 173-7.
- Dolan TF, Touloukian RJ. Familial meconium ileus not associated with cystic fibrosis. *J Pediatr Surg* 1974; 9: 821-4.
- di Sant' Agnese PA, Davis PB. Research in cystic fibrosis. *N Engl J Med* 1976; 295: 481-5.
- Rescorla FJ, Grosfeld JL, West KJ, Vane DW. Changing patterns of treatment and survival in neonates with meconium ileus. *Arch Surg* 1989; 142: 837-40.
- Rickham PP, Lister J. Intestinal atresia and stenosis, excluding the duodenum. In: Rickham PP, Lister J, Irving IM, eds. *Neonatal Surgery*. 2nd ed. London: Butterworth & Co Ltd. 1978: 381-400.
- Jones PG, Woodward AA. *Clinical pediatric surgery: Diagnosis and management*. Melbourne: Blackwell Scientific Publications. 1986: 76-94.
- Raffensperger JG. Intestinal obstruction in the neonate. In: Raffensperger JB, ed. *Swenson's Pediatric Surgery*. 4th ed. New York: Appleton - Century Crafts. 1980: 461-5.
- Adeyemi D. Neonatal intestinal obstruction in a developing tropical country: Patterns, problems and prognosis. *J Trop Pediatr* 1989; 35: 66-70.
- di Sant' Agnese PA, Darling DC, Perera GA, Shea G. Abnormal electrolyte composition of sweat in cystic fibrosis of pancreas: Clinical significance and relationship to the disease. *Pediatrics* 1953; 12: 549-63.
- di Sant' Agnese PA, Davis PB. Research in cystic fibrosis. *N Engl J Med* 1979; 66: 121-30.
- Caniano DA, Beaver BL. Meconium ileus: A fifteen-year experience with forty-two neonates. *Surg* 1987; 102: 699-719.
- Abramson SJ, Baker DH, Amodio JB, Berdon WE. Gastrointestinal manifestations of cystic fibrosis. *Semin Roentgenol* 1987; 22: 97-113.
- Wong HB. Cystic fibrosis in a Chinese girl. *J Singapore Pediatr Soc* 1975; 17: 96-102.
- Katayama H, Tanaka T, Kurnihara G. Cystic fibrosis of the pancreas: a report of a Japanese autopsy case. *Radiat Med* 1985; 3: 137-43.
- Tagadish TS. Cystic fibrosis of the lungs. *Ind J Pediatr* 1989; 56: 288-90.
- Yadav K. Intestinal obstruction. In: Yadav K. *A Textbook of Neonatal Surgery*. Chandigarh: Vikas Publishing House Pte Ltd. 1983: 200-34.
- Noblett HR. Treatment of uncomplicated meconium ileus by gastrograffin enema: A preliminary report. *J Pediatr Surg* 1969; 4: 190-7.
- Bishop HC, Koop CE. Management of meconium ileus resection, Roux-en-Y anastomosis and ileostomy irrigation with pancreatic enzymes. *Ann Surg* 1957; 145: 410-4.
- McParthin JF, Dickson TAS, Swain VAJ. Meconium ileus: Immediate and long-term survival. *Arch Dis Child* 1972; 47: 207-10.
- Kalayogku M, Sieber WK, Rodnan JB, Kiesewetter WB. Meconium ileus: A critical review of treatment and eventual prognosis. *J Pediatr Surg* 1971; 6: 290-300.