

SIMPLE ASPIRATION OF PNEUMOTHORAX

A W K Ng, K W Chan, S K Lee

ABSTRACT

The effectiveness of simple aspiration of pneumothorax with an intravenous cannula was evaluated in 34 patients who would otherwise have been treated by intercostal tube drainage with underwater seal. The procedure was successful in 25 patients (73.5%). The following features were associated with a successful outcome: (a) age below 50 years, (b) absence of underlying lung disease, (c) pneumothorax size not exceeding 50%, (d) volume of air aspirated less than 3000 ml, and (e) no previous pneumothorax. There were no complications encountered. Successfully treated patients benefitted from a shorter hospitalisation stay. The potential use of this procedure in treating selected patients in an outpatient setting should be explored.

Keywords: pneumothorax, aspiration, intravenous cannula, safe, cost savings.

SINGAPORE MED J 1994; Vol 35: 50-52

INTRODUCTION

Pneumothorax can result in significant morbidity particularly in patients with compromised lung function. Immediate treatment directed at evacuating the pneumothorax is crucial in relieving the patient of his symptoms and may be lifesaving.

Insertion of an intercostal tube with underwater seal drainage is the time honoured way of treating a pneumothorax. This, however, can be a painful procedure and potential complications may arise^(1,2). Additional inconvenience to the patient are the restriction of mobility by the indwelling tube and the need for hospitalisation for a period which may range from five to thirty days⁽³⁾. Moreover, tube drainage does not prevent recurrence⁽⁴⁾.

The aspiration of a pneumothorax with a needle was frowned upon because of the fear of lacerating the expanding lung^(4,5). With the introduction of intravenous cannulas, many workers have shown that a pneumothorax can be aspirated safely and the patient saved the discomfort of having an indwelling tube^(3,6-10).

We evaluated the results of simple aspiration of pneumothorax using intravenous catheters in 34 patients who would otherwise have been treated by tube drainage. Our objective was to determine the role of aspiration in the present day management of pneumothorax.

MATERIAL AND METHODS

Patients with pneumothorax confirmed radiologically were considered for simple aspiration. The size of the pneumothorax was determined by visual estimation of the extent of regression of the visceral pleura from the chest wall on the chest radiograph. Correlation of this estimation with the method of Rhea et al⁽¹¹⁾ was done.

We excluded patients who had the following problems: tension pneumothorax, bilateral pneumothoraces, hydropneumothorax and patients in respiratory distress. Small pneumothoraces (<20%) were treated conservatively unless

symptomatic. Pneumothorax occurring in mechanically ventilated patients or those being considered for ventilation was excluded from our study.

Consent was obtained from all patients. The site of aspiration was either anteriorly at the second intercostal space, along the mid-clavicular line or laterally between the fifth to seventh intercostal space along the mid-axillary line. The appropriate site is cleaned and approximately 5ml of 1% lignocaine injected.

An 18G intravenous cannula was then inserted with gentle suction into the pleural cavity, the needle being withdrawn once the cannula entered the pleural cavity. The cannula is connected to a 3-way tap to which is attached a 50ml plastic syringe and a length of plastic tubing with the other end immersed in a jug of water. By manipulating the 3-way tap, air is aspirated from the pneumothorax with the syringe and expelled underwater. Care is taken not to kink the cannula during the procedure. The volume of air aspirated is recorded.

The procedure was terminated when (a) there was resistance to further aspiration, (b) 4000ml of air was aspirated, or (c) progressive breathlessness, pain or giddiness occurred.

Chest radiograph was done within 6 hours following aspiration and another at 24 hours post aspiration. The procedure was considered successful if aspiration reduced the size of the pneumothorax to less than half the initial size and avoided the insertion of an intercostal tube. These patients were then discharged with advice to return if breathlessness occurred. They were followed up at the outpatient clinic with repeat radiographs in 4 to 6 weeks.

Patients in whom significant pneumothorax remained after aspiration, were treated conventionally by insertion of an intercostal tube.

RESULTS

A total of 34 patients were treated by simple aspiration. There were 31 males and 3 females. Their ages ranged from 16 to 82 years; the mean age was 43.2 years (Table I).

Table I – Age and sex distribution

Age (years)	Male	Female
< 30	14	0
30 – 50	5	2
> 50	12	1

Fifteen patients (44%) had one or more underlying lung diseases. This included 7 with COPD, 2 with bronchial carcinoma, one with bullae and one with pneumocystis carinii pneumonia. Two patients were undergoing treatment for active pulmonary

Department of General Medicine
Tan Tock Seng Hospital
345 Jalan Tan Tock Seng
Singapore 1130

A W K Ng, MBBS, M Med (Int Med), MRCP (UK)
Registrar

K W Chan, MBBS, FRCP (Edin), FAMS
Consultant Physician

S K Lee, MBBS, FRCP (Glas), FRCP (Edin), FAMS
Senior Consultant Physician

Correspondence to: Dr A W K Ng

tuberculosis. In 7 patients there was radiologic evidence of scarring or fibrosis from previous disease. Six patients had a past history of pneumothorax.

Thirty-three patients (97%) were symptomatic. The most common symptoms were chest pain (55.9%) and breathlessness (55.9%).

The pneumothorax was spontaneous in 32 patients (94%). In one patient pneumothorax complicated fine needle aspiration biopsy of the lung. One patient with pneumocystis carinii pneumonia had pneumothorax following transbronchial lung biopsy.

The size of the pneumothorax ranged from 15% to 90%. (Table II). The correlation between the 'eyeball' method and Rhea's method in estimating the size of the pneumothorax was close in pneumothoraces less than 50%.

Table II – Estimated size of pneumothorax in patients

Size of pneumothorax	Number of patients
< 30%	17
30% – 50%	9
> 50%	8

Simple aspiration was a successful procedure in treating pneumothorax in 25 patients (73.5%) (Fig 1). In 3 patients, complete re-expansion was achieved. There was a residual pneumothorax of 5% or less in 19 (55.9%). Two patients had 10% and one had 20% residual pneumothorax. Symptoms were relieved in all 25 patients. The residual pneumothorax increased in one patient following discharge necessitating chest tube insertion.

Fig 1 – Large right pneumothorax in a 46-year-old man (a) before and (b) after simple aspiration. There is a small residual pneumothorax following simple aspiration which resolved spontaneously.

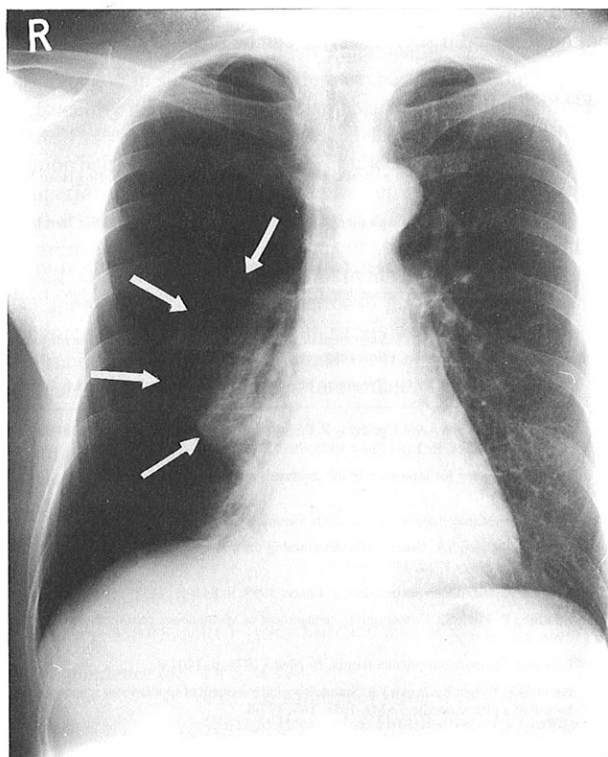


Fig 1 (a)

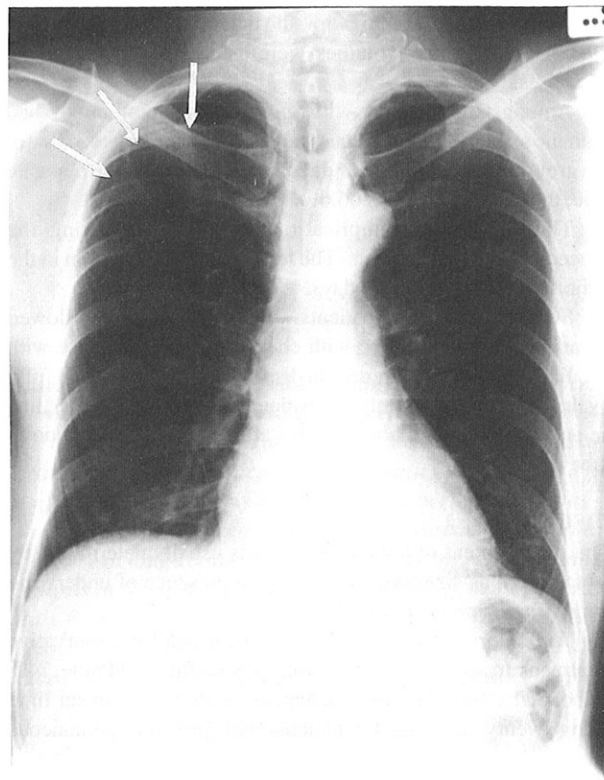


Fig 1 (b)

The results were also analysed with respect to the patient's age, presence of underlying lung disease and size of pneumothorax. The outcome was more likely to be successful in patients aged below 50 years where the success rate was 81% compared to 61.3% in patients aged 50 years and above (Table III).

Table III – Likelihood of successful aspiration with age

Outcome	Age < 50 years	Age > 50 years
Successful	17 (81%)	8 (61%)
Failure	4 (19%)	5 (39%)

Table IV – Likelihood of success and the presence of lung disease

Outcome	No lung disease	Underlying lung disease
Successful	15 (79%)	10 (66.7%)
Failure	4 (21%)	5 (33.3%)

Patients with no underlying lung disease were more likely to be successfully aspirated. (79% vs 66.7%; Table IV). The most common pathologies associated with failure was COPD and fibrosis.

Pneumothoraces less than 50% were more likely to be successfully aspirated (77% vs 62.5%; Table V) than large ones.

Table V – Likelihood of success and the size of pneumothorax

Outcome	< 50% pneumothorax	> 50% pneumothorax
Successful	20 (77%)	5 (62.5%)
Failure	5 (23%)	3 (37.5%)

It also appeared that the likelihood of a successful outcome is related to the volume of air aspirated. When the volume of air

aspirated was less than 3,000ml, the outcome was successful in 89.3%. When larger volumes were aspirated, there were no successes.

Amongst the 6 patients with a previous pneumothorax, 3 had it on the same side. The success rate in this group was 33.3%. In the group where the previous pneumothorax was on the opposite side, the success rate was 66.6%.

There were no complications encountered during the procedure in all the patients. The length of hospitalisation in the majority of patients was 2 days.

Successfully treated patients were discharged and followed up at the outpatient clinic with chest radiographs. Those with small residual pneumothorax on discharge had reexpanded fully by the time of review. Only one patient, as mentioned earlier, had an enlarging pneumothorax 2 days after discharge; he required tube drainage.

DISCUSSION

The management of a pneumothorax is usually determined by factors such as size, symptoms and the presence of underlying lung disease amongst others⁽¹²⁾.

The majority of pneumothoraces will respond to conservative treatment. In a series of 119 patients by Stradling and Poole, 74% responded to conservative management alone, the mean time being twenty-two days for patients with primary spontaneous pneumothorax⁽¹³⁾. Those who required active treatment had persistent dyspnoea, tension pneumothorax, marked pulmonary collapse, previous pneumothoraces, adhesions or pain. The main disadvantage with a conservative approach however is the length of time necessary for full reexpansion and the consequent loss of economic productivity to the patient⁽¹⁴⁾.

Intercostal tube drainage allows rapid evacuation of air from the pleural cavity. It has been the treatment of choice in the majority of patients with a pneumothorax⁽⁴⁾ but may be associated with potential complications in addition to discomfort to the patient^(10,12) and need for hospitalisation.

In a selected group of patients, the pneumothorax can be aspirated safely and the air evacuated fairly rapidly. The method was first described by Knuth et al in 1958⁽¹⁵⁾ but was initially discouraged for fear of lacerating the lung^(4,5). This fear is unfounded in the hands of various workers who have reported success with the use of plastic intravenous cannulas^(3,6-8, 10, 16).

Other results are compatible with those reported elsewhere. The overall success rate in our series was 73.5%. The factors influencing a successful outcome were age below 50 years, the absence of underlying lung disease and pneumothorax less than 50%. Generally younger patients are less likely to have an underlying lung disease. In our series, only 3 of 21 (14%) patients below 50 years had lung diseases whereas 12 of 13 (92%) patients aged above 50 years had abnormal lungs (Table VI).

Table VI – Association of lung disease with age (number of successfully aspirated cases in brackets)

Age (years)	Underlying lung disease	No lung disease
< 50	3 (3)	18 (14)
> 50	12 (7)	1 (1)

The presence of a persistent air leak is suggested when the volume of air aspirated was more than 4000ml. Simple aspiration is not therapeutic in such patients but helps in identifying this group of patients who require tube drainage. Similarly, results show that a successful outcome is less likely in patients who have had a previous pneumothorax, especially if it was on the same side. Recurrent pneumothoraces should therefore be managed by

tube drainage and pleurodesis to prevent a repeat.

There was no need to repeat the aspiration in any of our patients although some authors reported that repeat aspirations were required^(3,7,8). The pneumothorax need not be evacuated completely. We aimed at converting a sizeable pneumothorax to one that could be managed conservatively. The small residual pneumothorax is expected to resolve spontaneously at the rate of 1.25% of the hemithoracic volume daily⁽¹⁷⁾. The patient is allowed to rest at home and followed up at the specialist outpatient clinic till resolution.

Pneumothorax patients who have been successfully aspirated benefit from a short hospitalisation and suffer no restriction of mobility. The relatively less painful and traumatic procedure was not associated with any complications in our series. That it has resulted in avoidance of tube drainage in a selected group of patients indicates potential savings in the cost of treatment.

In our hands, only one patient had a worsening of the pneumothorax following discharge, necessitating tube drainage. Residual pneumothorax in all 21 patients resolved completely on follow-up, the duration depending on the size of the residual pneumothorax.

We have shown simple aspiration to be a relatively simple and safe procedure which can be performed relatively quickly utilising very basic equipment. Where facilities permit (radiological and observation), it may be possible to aspirate carefully selected patients with pneumothorax in the accident and emergency department or in the treatment room of the outpatient clinic.

The follow-up was not sufficiently long for us to comment on subsequent recurrences. However, we believe that it is unlikely that aspiration can prevent or reduce it. Recurrences should be treated with tube drainage and considered for pleurodesis, either medically or surgically.

There can be potential savings in medical costs in aspirating pneumothoraces in carefully selected patients with pneumothorax. Equipment for aspiration is easily obtainable and cheap compared to the setup for intercostal tubes. The short period of hospitalisation would represent substantial savings; ideally such patients need not be admitted if such a service can be provided.

REFERENCES

1. Miller KS, Sahn SA. Chest tubes. Indications, technique, management and complications. *Chest* 1987; 91: 258-64.
2. Walesby RK. How to insert a chest drain and aspirate a pleural effusion. *Br J Hosp Med* 1981; 25: 198-201.
3. Raja OG, Lalor AJ. Simple aspiration of spontaneous pneumothorax. *Br J Dis Chest* 1981; 75: 207-8.
4. Seremetis MG. The management of spontaneous pneumothorax. *Chest* 1970; 57: 65-8.
5. Home NW. Spontaneous pneumothorax: diagnosis and treatment. *Br Med J* 1966; i: 281-4.
6. Bevelaqua FA, Aranda C. Management of spontaneous pneumothorax with small lumen catheter manual aspiration. *Chest* 1982; 81: 693-4.
7. Hamilton AAD, Archer GJ. Treatment of pneumothorax by simple aspiration. *Thorax* 1983; 38: 934-6.
8. Archer GJ, Hamilton AAD, Upadhyay R, Finlay M, Grace PM. Results of simple aspiration of pneumothoraces. *Br J Dis Chest* 1985; 79: 177-82.
9. Jones SJ. A place for aspiration in the treatment of spontaneous pneumothorax. *Thorax* 1985; 40: 66-7.
10. Riordan JF. Management of spontaneous pneumothorax. *Br Med J* 1984; 289: 71.
11. Rhea JT, DeLuca SA, Greene RE. Determining the size of pneumothorax in the upright patient. *Radiology* 1982; 144: 733-6.
12. Editorial. Spontaneous pneumothorax. *Lancet* 1989; ii: 843-4.
13. Stradling P, Poole G. Conservative management of spontaneous pneumothorax. *Thorax* 1966; 21: 145-9.
14. Editorial. Spontaneous pneumothorax. *Br Med J* 1976; ii: 1407-8.
15. Knuth WP, Wright KJ, Jenko VA. Simple surgical treatment of spontaneous pneumothorax by use of a plastic needle. *JAMA* 1958; 168: 177-8.
16. Editorial. Simple of aspiration of pneumothorax. *Lancet* 1984; i: 434-5.
17. Kircher LT, Swartzel RL. Spontaneous pneumothorax and its treatment. *JAMA* 1954; 155: 24-9.