

ECHOCARDIOGRAPHIC DETECTION OF MOBILE RIGHT ATRIAL THROMBUS

Y S Lau, T S Chee, K L Chua

ABSTRACT

Mobile right atrial thrombus is a rare echocardiographic diagnosis with important implications on further management. We report a case of 50-year-old woman with deep vein thrombosis of her left lower limb, who was found to have a large mobile serpiginous right atrial thrombus on both two-dimensional echocardiography (2DE) and transoesophageal echocardiography (TEE). She developed acute pulmonary embolism within thirty-six hours of diagnosis and subsequently underwent successful pulmonary embolectomy. This case demonstrates the usefulness of echocardiography as a non-invasive tool in the investigation of suspected pulmonary thromboembolism. The detection of right atrial thrombus mandates serious consideration for prompt surgical action.

Keywords: mobile right atrial thrombus, two-dimensional echocardiography (2DE), transoesophageal echocardiography (TEE), pulmonary embolectomy

SINGAPORE MED J 1994; Vol 35: 112-114

INTRODUCTION

Mobile right atrial thrombus is a rare event with potentially fatal consequences. The initial awareness of this condition came from postmortem reports^(1,2), but since the advent of echocardiography⁽³⁻¹³⁾, ante-mortem diagnosis has become greatly facilitated. We report a case of mobile right atrial thrombus diagnosed by two-dimensional echocardiography (2DE) and confirmed on transoesophageal echocardiography (TEE), which subsequently embolised to the pulmonary circulation within thirty-six hours and was surgically removed successfully.

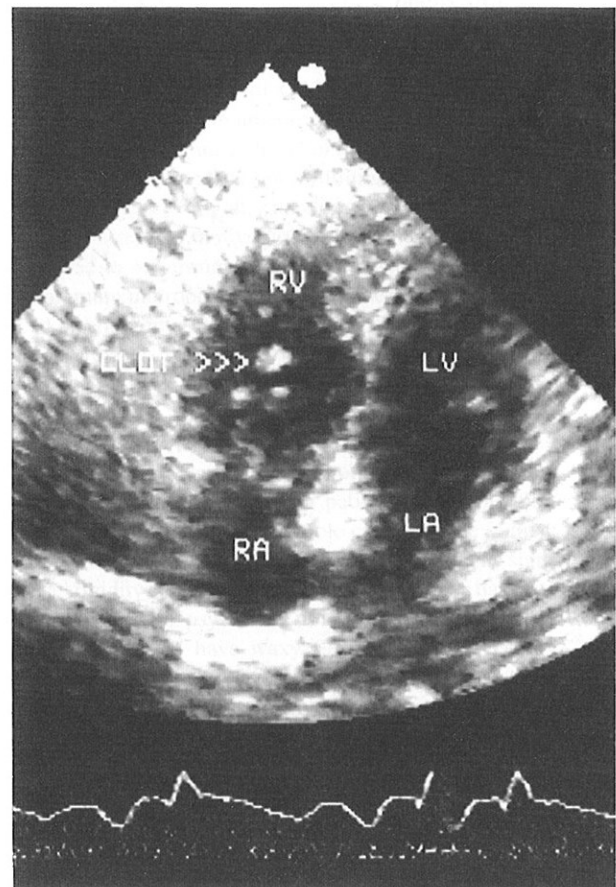
CASE REPORT

OLC, a 50-year-old Chinese female, was admitted to the hospital for shortness of breath associated with central chest discomfort of several days' duration. She had a history of Koch's disease treated 20 years ago. There was no history of predisposing factors for deep vein thrombosis. Physical examination demonstrated tachycardia (104 beats/minute) and an accentuated pulmonic sound. She remained comfortable without evidence of tachypnoea or neck vein distension at rest. Her left leg calf was slightly swollen but it was neither warm nor tender. The ECG showed sinus tachycardia and left axis deviation. The chest X-ray showed old left apical scarring but otherwise appeared within normal limits.

2DE revealed a large highly mobile serpiginous blood clot rotating within the right atrium, giving a 'towel in the washing machine' appearance (Fig 1). There was no definite site of attachment. The right ventricle, right atrium and inferior vena cava were dilated and the right ventricle appeared hypokinetic. The main pulmonary artery was dilated as well but no clot was seen on the transthoracic echo. Doppler study demonstrated moderately severe tricuspid regurgitation with velocity 3.5 ms⁻¹

and estimated pulmonary artery systolic pressure 54 mmHg. Mild mitral regurgitation was present. After informed consent was taken, TEE was performed. This demonstrated the large mobile serpiginous clot in the right atrium, which intermittently projected beyond the tricuspid valve into the right ventricle (Fig 2). In addition, a thrombus was seen in the right pulmonary artery (Fig 3).

Fig 1 – 2DE apical 4 chamber view showing dilated right ventricle. The serpiginous clot in the right atrium is seen protruding across the tricuspid valve into the right ventricle.



Department of Medicine
Toa Payoh Hospital
Toa Payoh Rise
Singapore 1129

Y S Lau, M Med (Int Med)
Senior Registrar

T S Chee, M Med (Int Med)
Visiting Consultant

K L Chua, MRACP (Aust), FAMS, FRACP (Aust)
Senior Consultant and Head

Correspondence to: Dr Y S Lau

Fig 2 – TEE view. The highly mobile clot is clearly seen in the right atrium.

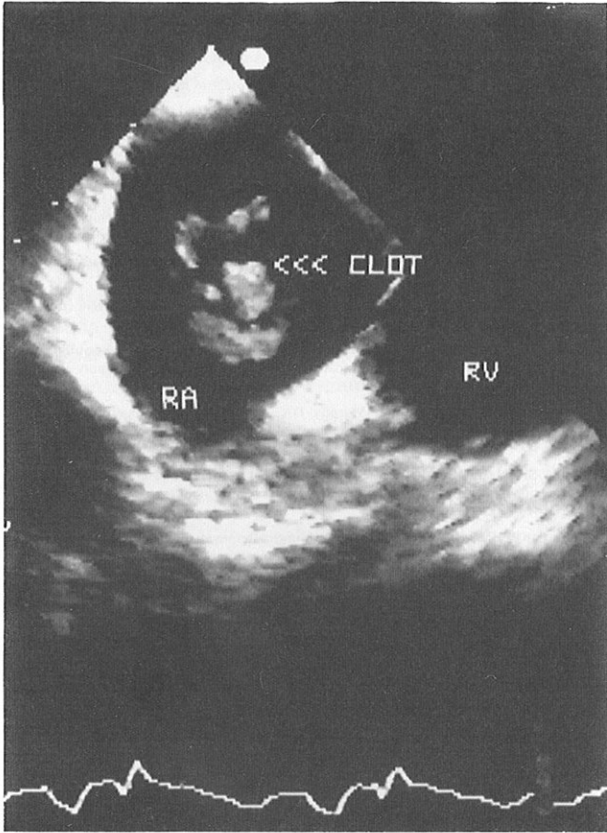
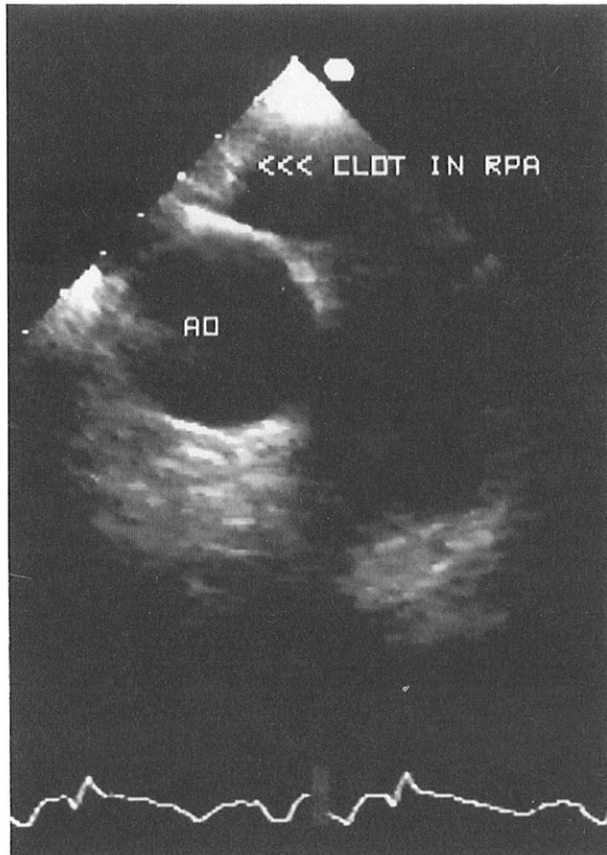


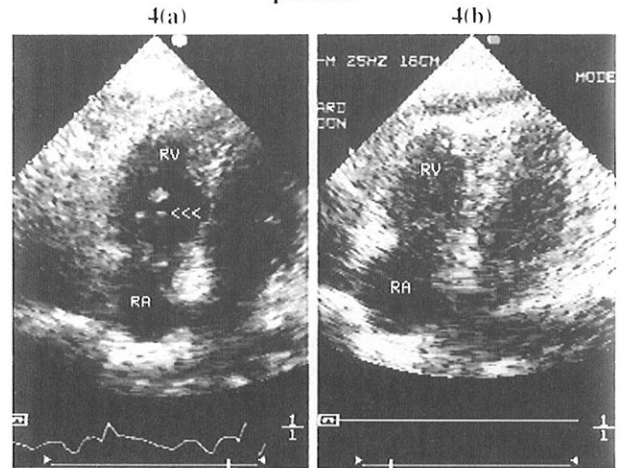
Fig 3 – TEE view showing the clot in the right pulmonary artery



Arterial blood gas suggested a hypoxaemic hyperventilating state (pCO₂ 25.6 mmHg, pO₂ 62.6 mmHg, saturation 93.3%) The Doppler ultrasound of the patient's left lower limb showed deep vein thrombosis of the superficial femoral and popliteal veins. She was promptly anticoagulated and pulmonary embolectomy with removal of the right atrium thrombus was scheduled to be performed the next morning.

One hour before the surgery, the patient became tachypnoeic (25 respirations/minute), tachycardic (100 beats/minute) and hypotensive (90 systolic). A repeat 2DE was performed and this time showed the right atrial clot to have disappeared (Fig 4a and b). The patient underwent an emergency operation and was found to have large amounts of clots in both right and left pulmonary arteries. The right atrium was opened and explored and found to contain no further clot.

Fig 4(a) – 2DE shows the right atrial clot (arrow) protruding partially into the right ventricle. 4(b) 2DE done after patient developed sudden breathlessness and hypotension shows the right atrial clot no longer present.



DISCUSSION

The occurrence of right-sided intracavitary thromboembolism has long been recognised but few cases have been described. The earliest reports were based on post-mortem observations^(1,2). Until the advent of echocardiography, ante-mortem diagnosis was rare. The sudden onset of a systolic murmur or positional-related cyanosis, in the presence of deep vein thrombosis was once said to point to this condition, but deep vein thrombosis, especially of the variety that is associated with pulmonary embolism, is rarely detected clinically⁽¹⁴⁾.

The first report by Covarrubias et al⁽³⁾ described the M-mode echocardiographic appearance of multiple shaggy echoes adjacent to the tricuspid valve in a patient with sudden hypotension, multiple systolic clicks and a systolic murmur at the left sternal edge. The patient died two days after echocardiography and autopsy revealed a saddle embolus in the main pulmonary artery. The authors correctly postulated that the clinical and echocardiographic findings were due to an embolus that was temporarily entrapped at the tricuspid valve and subsequently migrated to the main pulmonary artery.

Since then, there have been case reports in the literature describing detection of right-sided cardiac thrombi by echocardiography⁽³⁻¹³⁾. These attest to its usefulness as an investigative tool in the ante-mortem diagnosis of pulmonary thromboembolism. The technique is rapid, non-invasive and readily available. Its sensitivity however is probably low as a majority of such thromboemboli pass rapidly through the right

heart and lodge in the pulmonary circulation⁽⁹⁾, hence escaping echocardiographic detection.

The differential diagnoses of right atrial masses include tumours, vegetations, tricuspid abnormalities and right heart catheters⁽⁹⁾. Failure to visualise attachment to the atrial wall and the 360 degree rotational motion both favour the diagnosis of a free-floating thrombus. Where technical difficulty is encountered in identifying lesions, TEE may aid in these difficult situations. TEE not only provides better visualisation of the suspected clot in the right atrium, but the detection of clot in the pulmonary artery, as was the case in our patient, virtually establishes the diagnosis.

Whether the identification of right ventricular or right atrial thrombus should be regarded as an indication for the surgical approach is conjectural. Left ventricular thrombus has been known to disappear rapidly with anticoagulation⁽¹⁵⁾, but some have argued that its structure and natural history may be different from the thrombus of venous origin. The report by Starkey et al⁽⁴⁾ described fatal pulmonary embolism after partial dissolution of the right atrial and right ventricular thrombus with streptokinase therapy. Hence in patients with an already compromised pulmonary vascular bed, the presence of intracavitary thrombus should be considered an indication for surgery, especially if the thrombus is a large one.

Ours in the first locally well documented case, using 2DE and TEE, of a mobile right atrial thrombus progressing to pulmonary embolism. Immediate surgical embolectomy resulted in survival and uneventful recovery of the patient. She was later found to

have protein C deficiency and was referred to the haematologist for further management.

REFERENCES

1. Radding RS. Ball thrombus of the right auricle. *Am J Med* 1951; 11: 653-7.
2. Spencer JD, King JF, Grossman AE. Cardiac embolus. *Am Heart J* 1971; 82: 802-4.
3. Covarrubias EA, Sheikh MU, Fox LM. Echocardiography and pulmonary embolism. *Ann Intern Med* 1977; 87: 720-1.
4. Starkey IR, DeBobo DP. Echocardiographic identification of right-sided cardiac intracavitary thromboembolus in massive pulmonary embolism. *Circulation* 1982; 66: 1322-5.
5. DiCarlo LA Jr, Schiller NB, Herfkens RL, Brundage BH, Lipton MJ, et al. Noninvasive detection of proximal artery thrombosis by two-dimensional echocardiography and computerized tomography. *Am Heart J* 1982; 104: 879-81.
6. Redish GA, Anderson AL. Echocardiographic diagnosis of right atrial thromboembolism. *J Am Coll Cardiol* 1983; 1: 1167-8.
7. Rosenzweig MS, Nanda NC. Two dimensional echocardiographic detection of circulating right atrial thrombi. *Am Heart J* 1982; 103: 435-6.
8. Sauer HE, Asinger RW, Daniel JA, Elsperger KJ. Two dimensional echocardiographic detection of right-sided cardiac intracavitary thromboembolus with pulmonary embolism. *J Am Coll Cardiol* 1984; 1294-300.
9. Felner JM, Churchwell AL, Murphy DA. Right atrial thromboemboli: Clinical, echocardiographic and pathophysiologic manifestations. *J Am Coll Cardiol* 1984; 4: 1041-50.
10. Lim SP, Hakim SZ, van der Bel-Kahn JM. Two-dimensional echocardiography for detection of primary right atrial thrombus in pulmonary embolism. *Am Heart J* 1984; 108: 1546-7.
11. Nestico PF, Panidis IP, Kotler MN, Ross J. Surgical removal of right atrial thromboembolus detected by two-dimensional echocardiography in pulmonary embolism. *Am Heart J* 1984; 107: 1278-80.
12. Quinn TJ, Plehn JF, Liebson PR. Echocardiographic diagnosis of mobile right atrial thrombus: Early recognition and treatment. *Am Heart J* 1984; 108: 1548-50.
13. Zaidi SJ. Two-dimensional echocardiographic detection of asymptomatic pulmonary thromboembolism. *Echocardiography* 1992; 1: 17-9.
14. Alexandra RH, Folse R, Pizzoronos J, Conn R. Thrombophlebitis and thromboembolism: results of a prospective study. *Ann Surg* 1974; 180: 883-7.
15. Rensaid J, Blanc P, Viro P. Rapid disappearance of left ventricular mass (presumed thrombus) in a patient with cardiomyopathy. *Br Heart J* 1982; 47: 301-3.