

# ULTRASOUND GUIDED TRANSPERINEAL PROSTATIC ASPIRATION BIOPSY : EXPERIENCE IN HONG KONG

W Cheung, E M T Chau, S T Yuen, L Leong, R J Collins

## ABSTRACT

**Objective:** The purpose of this study is to correlate the result of the ultrasound guided transperineal aspiration biopsy with the clinical findings.

**Materials and Methods:** We retrospectively studied 27 patients who had been subjected to ultrasound guided transperineal prostatic aspiration biopsy in our institution during the period 1990 to 1992. The patients were divided into two groups: Group A – those with clinically palpable nodules on digital examination, and Group B – those without palpable nodule but with clinical evidence of prostatic enlargement and/or bladder outlet obstruction.

**Results:** There were 8 biopsy proven cancers, 4 of them were palpable lesions while the other 4 were clinically non-palpable. The overall positive predictive value was 29.6%; this increased to 40% if the lesions were palpable but decreased to 23.5% if the lesions were non-palpable.

**Conclusion:** The overall positive predictive value of this technique was found to be consistent with other studies using different methods of biopsies. The positive predictive value was increased if the abnormality was clinically palpable. This technique was also found to be safe and no significant complication was observed in these patients.

**Keywords:** prostatic disease, transrectal ultrasound

SINGAPORE MED J 1994; Vol 35: 457-459

## INTRODUCTION

Carcinoma of the prostate is a common neoplasm in elderly males. However, these patients usually present with advanced disease. Previously, this diagnosis had been solely dependent on the detection of a palpable prostatic lesion during rectal examination. Within the last 10 years, transrectal ultrasonography (TRUS) has developed as a safe and easily reproducible method of imaging for the early identification of prostatic cancer<sup>(1,2)</sup>.

## MATERIALS AND METHODS

All patients were referred by physicians, either for suspicious nodules palpable on digital rectal examinations or obstructive symptoms.

All fine needle aspiration biopsies were performed on prostate lesions via the transperineal route with transrectal ultrasound guidance. The TRUS examinations were done in axial projections with an Acuson 128XPE Scanner and a

7.0 MHz axial probe.

The fine needle aspiration biopsies were performed under local anaesthesia (1% lignocaine). The patient was placed in the lithotomy position for most of the procedures; however in some patients who could not maintain this position, a left lateral decubitus position was employed. When a suspicious area was visualised, the needle guide programme of the machine was turned on. A needle path cursor labelled with a number was adjusted to pass through the area of interest for biopsy. A transperineal needle guide was then fixed to the transducer. The projected needle path on the screen corresponded to the slot number on the needle guide. The perineum was sterilised with iodine and alcohol and the region was draped with sterile towels. A 22 gauge skinny needle was inserted through the channel of the decided slot number of the needle guide into the perineum and the movement of the needle tip was monitored on the viewing screen. When the needle tip approached the area to be biopsied, it was seen as a highly reflective echo-dense area (Fig 1a & 1b). Cytological samples were taken from the abnormal areas using a usual fine needle aspiration technique with two or three aspirations performed on each patient. The smear preparation, fixation and preliminary screening for specimen adequacy were performed by a cytotechnologist in the ultrasound suite. All cases were performed on an outpatient basis.

The sensitivity and specificity of transrectal ultrasound could not be calculated because there was no surgical biopsy with histological examination to assess the false positive and negative rates. Therefore, the only parameter we calculated was positive predictive value (PPV) of transrectal ultrasound. The PPV was calculated as follows:

$$\text{Positive predictive value} = \frac{\text{Number of cancers detected by transrectal US}}{\text{Number of patients with positive transrectal US}}$$

---

**Diagnostic Radiology Division**  
**Queen Mary Hospital**  
102 Pokfulam Road  
Hong Kong

W Cheung, MBBS, FRCR  
Senior Medical Officer

E M T Chau, MBBS, DMRD, FRCR  
Consultant

L Leong, MBBS, DMRD, FRCR  
Consultant

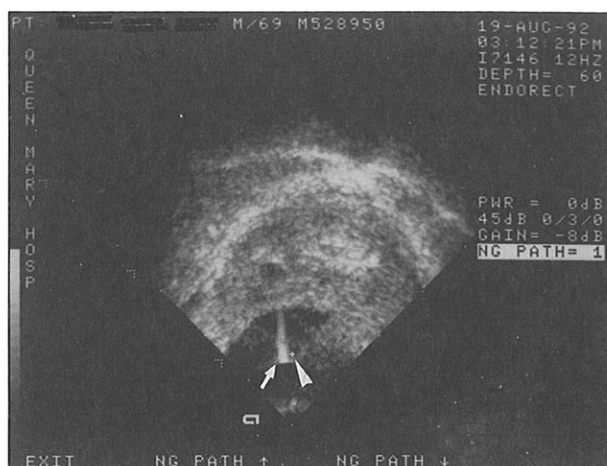
**Department of Pathology**  
**Queen Mary Hospital**

S T Yuen, MBBS, FRCS (Edin)  
Clinical Pathologist

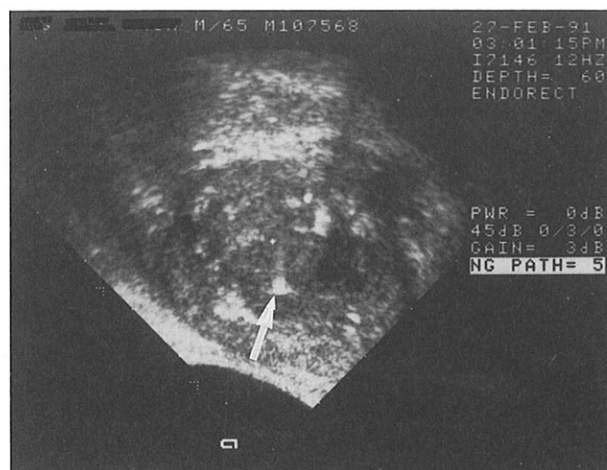
R J Collins, MBBS, FRCPA  
Senior Clinical Pathologist

**Correspondence to:** Dr W Cheung

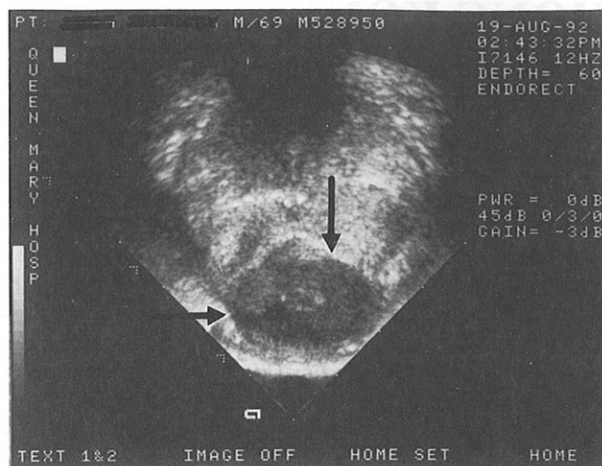
**Fig 1a** – Needle tip is demonstrated as an echogenic focus (arrow) within the region to be biopsied. The cursor (arrowhead) of the needle guide path is next to the needle tip.



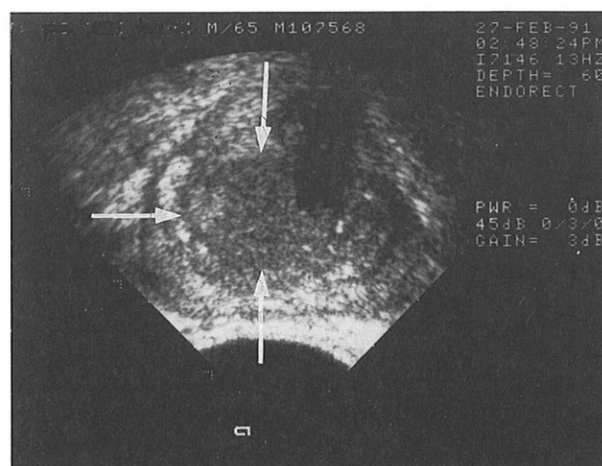
**Fig 1b** – Needle tip is seen as an echogenic focus (arrow) in the lesion.



**Fig 2a** – Axial scan of prostate demonstrating an extensive hypoechoic cancer in the peripheral zone (arrows).



**Fig 2b** – Axial scan of prostate showing an isoechoic cancer in the right transition zone (arrows). Note the asymmetry between the two sides.



## RESULTS

Between September 1990 and September 1992, a total of 27 patients (mean age 70 years) were biopsied using transrectal ultrasound guidance; 25 patients were Chinese, 2 were Caucasians. The patients were divided into 2 groups: Group A – those with clinically palpable nodules admitted for biopsy, and Group B – those without a defined nodule but with clinical evidence of prostatic enlargement or bladder outlet obstruction. There were 10 patients in Group A and 17 patients in Group B.

Biopsy results indicated carcinoma in 8 patients (4 in each group), granulomatous prostatitis in one, dysplasia in one and various benign conditions in 17 (Table I). Of the 8 malignant lesions, 7 were hypoechoic and in the peripheral zones (Fig 2a) and one was isoechoic and in the transition zone (Fig 2b).

The overall positive predictive value (PPV) was 29.6%. The PPV of Group A was 40% while that in Group B was 23.5%.

No infective nor urinary complications were experienced by any of the patients.

The aspiration cytology results are summarised in Table I.

**Table I – Aspiration Cytology Results**

Group	No. of patients	Results	
		Malignant (%)	Benign
A	10	4 (40 %)	6
B	17	4 (23.5%)	13
Total	27	8 (29.6%)	19

## DISCUSSION

Prior to transrectal ultrasound, digital rectal examination was the only method with which to detect early carcinoma of the prostate. While biopsy of a palpable lesion in the prostate with digital guidance is a common procedure performed by urologists, the ability to palpate an abnormality depends on the size, location and consistency of the lesion and the skill of the examiners<sup>(9)</sup>. When prostatic

lesions are subtly palpable or non-palpable, ultrasound-guided biopsy offers an accurate technique to obtain a diagnosis.

A particular attraction of TRUS is that it can identify the zonal anatomy of the prostate. This zonal system of anatomy, initially proposed by McNeal, regards the prostate as an organ composed of glandular and non-glandular tissue; the latter is the anterior fibro-muscular stroma. The glandular tissue is further divided into three major regions: the transition, central and peripheral zones. Morphological analysis has shown that approximately 70% of cancers arise in the peripheral zone, 20% in the transition zone, and 10% in the central zone<sup>(4)</sup>.

Thus classically, prostatic cancers are situated in the peripheral zone. Their margins are irregular and poorly defined. While most are hypoechoic, about 6-24% are isoechoic<sup>(1,2)</sup>. Besides, not all hypoechoic lesions are malignant. For instance atypical glandular hyperplasia, prostate atrophy or granulomatous prostatitis may appear as hypoechoic areas within the gland<sup>(5)</sup>. Therefore, any hypoechoic area should be biopsied under ultrasound guidance.

Endorectal sonographically guided transperineal and transrectal biopsies are the most frequently used approaches to obtain a specimen for assessment by pathology. The transrectal route offers several technical advantages over the transperineal route. The biopsy needle path is shorter and deviation of the needle is less likely to occur. The procedure is quicker because skin preparation and local anaesthesia are not required<sup>(1)</sup> but infective complications including bacteraemia and urinary tract infection are more likely to occur than with the transperineal route<sup>(6)</sup>. Therefore, prophylactic antibiotic cover is usually prescribed. Recently the transrectal approach using a 'Biopsy' gun for needle core therapy has been regarded as the standard approach for ultrasound guided prostatic biopsy<sup>(5)</sup>. However, the use of an 18 gauge or larger needles for core biopsies is not without complications. Such complications include haematuria, perineal haematoma and intravesical clot retention, and a frequency of 2.7% was reported in one study<sup>(7)</sup>. Fine needle aspirations with 22 gauge or smaller needles have fewer adverse effects<sup>(8,9)</sup>. Fine needle aspiration has been advocated by some centres in United States and has been used successfully in Europe<sup>(7,8)</sup>. A correlation of over 90% between aspiration cytology and needle biopsy was found in many studies.

In view of less infective and urinary complications, we favour the use of the transperineal route with aspiration cytology for ultrasound guided prostatic biopsy. The PPV

of sonographically guided biopsies of prostatic hypoechoic lesions has ranged from 0% to 50%<sup>(1,10,11)</sup> in many studies and 20% to 25% was taken as the average by Rifkin<sup>(12)</sup>. In our study, the positive predictive value is 29.6% which is above the average. Therefore, we consider our technique appropriate and the low complication rate justifies the performance of the procedure on an outpatient basis.

In a study performed by Lee et al<sup>(10)</sup>, 256 hypoechoic lesions were biopsied under ultrasound guidance. The PPV for TRUS alone was 41%; this increased to 61% if the patient had a palpable abnormality on digital rectal examination (DRE). If no lesions were palpable, the PPV fell to 24%. Our results also revealed similar findings in which the PPV increased from 29.6% to 40% if DRE was positive and fell to 23.5% if DRE was negative.

We conclude that a hypoechoic lesion of the prostate carries a high risk for cancer and that fine needle aspiration biopsy is indicated. There is close correlation between the findings on palpation and ultrasound in evaluating the prostates of the patients with suspicious lesions.

#### ACKNOWLEDGEMENTS

The authors would like to thank Ms K Kwok and Ms R Chan for their clerical assistance.

#### REFERENCES

1. Clements R, Griffiths GJ, Peeling WB, Ryan PG. Experience with ultrasound guided transperineal prostatic needle biopsy 1985-1988. *Br J Urol* 1990; 65:362-7.
2. Griffiths GJ, Clements R, Peeling WB. The current status of transrectal ultrasonography in the diagnosis and management of prostatic cancer. *Clin Radiol* 1989; 40:337-40.
3. Lee FJ, Bronson JP, Lee F, Torp-Pedersen ST, Sider DB, Tornbury JR, et al. Nonpalpable cancer of the prostate: Assessment with transrectal US. *Radiology* 1991; 178:197-9.
4. McNeal JE. Normal anatomy of the prostate and changes in benign prostatic hypertrophy and carcinoma. *Semin Ultrasound CT MR* 1988; 9:329-34.
5. Clements R, Griffiths GJ, Peeling WB. "State of the Art" transrectal ultrasound imaging in the assessment of prostatic disease. *Br J Radiol* 1991; 64:193-200.
6. Thompson PM, Pryor JP, Williams JP, Evers DE, Dulake C, Scully MF, et al. The problem of infection after prostatic biopsy: The case for the transperineal approach. *Br J Urol* 1982; 54:736-40.
7. Carter HB, Riehler RA Jr, Koizumi JH, Amberson J, Vaughan ED Jr. Fine needle aspiration of the abnormal prostate: A cytohistological correlation. *J Urol* 1986; 135:294-8.
8. Ljung BM, Cherrie R, Kaufunan JJ. Fine needle aspiration biopsy of the prostate gland: A study of 103 cases with histological follow up. *J Urol* 1986; 135:955-8.
9. Chodak GW, Steinberg GD, Bibbo M, Wied G, Straus FS II, Vogelzong NJ, et al. The role of transrectal aspiration biopsy in the diagnosis of prostatic cancer. *J Urol* 1986; 135:299-302.
10. Lee F, Torp-Pedersen S, Littrup PJ, McLeary RD, McHugh TA, Smid AP, et al. Hypoechoic lesions of the prostate: Clinical relevance of tumour size, digital rectal examination, and prostate-specific antigen. *Radiology* 1989; 170:29-32.
11. Tan HH, Chang WY, Foo KT. Transrectal ultrasound of the prostate: The early Singapore experience. *Singapore Med J* 1991; 32: 434-7.
12. Rifkin MD. Prostate ultrasound. *Semin Ultrasound CT MR* 1988; 9:352-68.