

VIDEO-ASSISTED ENDOSCOPIC THORACIC SYMPATHECTOMY IN THE MANAGEMENT OF INTRACTABLE PALMAR HYPERHYDROSIS

J Thomas, P Pillay, P Mack, L L Ooi, M Nachiappan

ABSTRACT

Minimally invasive endoscopic surgical techniques have revolutionised patient management. We present our findings in our first 10 cases of bilateral video-assisted endoscopic thoracic sympathectomy in the management of intractable palmar hyperhydrosis including the first such procedure in Singapore. We have found the procedure to have minimal morbidity, good patient acceptance and all patients have remained with dry palms.

Keywords: endoscopic, sympathectomy, hyperhydrosis

SINGAPORE MED J 1994; Vol 35: 460-463

INTRODUCTION

The earliest reports of the therapeutic use of sympathectomy come from the last decade of the 19th century. Jonnesco, Jaboulay and LeRiche independently reported the use of sympathectomy in the treatment of epilepsy, exophthalmic goiter, angina pectoris and trophic limb ulcers⁽¹⁾. Their results and that of later workers identified its potential in the treatment of hyperhydrosis. The first use of sympathectomy for the treatment of essential hyperhydrosis was described by Kotzareff⁽¹⁾.

Hyperhydrosis may be said to be present when sweating is clinically noticeable under conditions where it would not be expected, or is excessive in response to heat or emotional stimuli⁽²⁾. The incidence may be as high as 0.6% to 1% in certain populations⁽²⁾ but the local incidence is not known. In situations where hyperhydrosis is generalised rather than being confined to the palms it is important to distinguish hyperhydrosis secondary to systemic illness from primary or essential hyperhydrosis. Hyperhydrosis has been reported as a symptom of central nervous system lesions (hypothalamic or pituitary). Excessive sweating is also part of the presentation of chronic inflammatory or infectious disorders, diabetes or hypoglycaemia and is also seen in patients with thyrotoxicosis, phaeochromocytomas or carcinoid tumours. Careful evaluation is required before the diagnosis of essential hyperhydrosis is made.

Essential hyperhydrosis, when severe, can be a very embarrassing problem. It may involve the entire body but is most symptomatic when it involves the upper extremities especially the hands. It can lead the person so afflicted to withdraw from social contact, show reluctance to shake hands or touch other people. It can, especially in the Singaporean context of compulsory military service, contribute to accidents and injuries. The patients often report the problem to have arisen since childhood or early adolescence. More females come forward for treatment.

Hyperhydrosis may be treated either by inhibiting sweat glands from emptying (using aluminium chloride or iontophoresis) or by interfering with their innervation. Iontophoresis is able to give satisfactory relief to about 70% of patients with mild to moderate palmar hyperhydrosis but lifelong regular treatment is required⁽³⁾. Denervation of the sweat glands may be achieved either pharmacologically (with anticholinergic drugs) or surgically. Anticholinergics are a poor option because severe side effects usually appear before effective therapeutic levels are achieved⁽³⁾. Thoracic sympathectomy has been used in the more severely affected patients with good results since 1935.

Conventionally the thoracic sympathetic chain has been exposed via the cervical, axillary and dorsal (posterior thoracic) approaches. The earliest report of the use of endoscopic techniques for thoracic sympathectomy came from Kux⁽⁴⁾. The potential benefits behind the technique were obvious to the surgical community but general adoption of the new approach awaited improvements in instrumentation. The largest series prior to 1985^(5,6) utilised the traditional neurosurgical posterior midline approach first described by Cloward⁽⁷⁾. Tan KK has reported on the local experience with the conventional methods of approach to the thoracic sympathetic chain⁽⁸⁾. The new generation of video-endoscopes, with their vastly improved optics, together with improved instrumentation, have revolutionised the scene. Almost paralleling the adoption of laparoscopic techniques for general surgery, there has been an exponential rise in the reports of successful use of endoscopic sympathectomy in the neurosurgical and general surgical journals. We report our local experience and results with video-assisted endoscopic thoracic sympathectomy including the first patient in Singapore to undergo the procedure.

Department of Neurosurgery
Singapore General Hospital
Outram Road
Singapore 0316

J Thomas, M Med (Surg), FRCS
Registrar

P Pillay, FRCS, FAMS, FRCS(C)
Head and Consultant
Director, Brain Centre, SGH

M Nachiappan, FRCS
Registrar

Department of General Surgery
Singapore General Hospital

P Mack, FRCS, FAMS
Senior Consultant

L L Ooi, FRCSE, FRCSEd
Registrar

Correspondence to: Dr J Thomas

MATERIALS AND METHODS

Patients

Eleven patients were selected to undergo the procedure between November 1992 and December 1993. There were 6 males and 5 females. Their ages ranged from 19 to 39 years with a median age of 31 years. The patients were selected based on their clinical findings and after screening by a dermatologist.

Equipment

The general surgical laparoscopic surgery set was used with the addition of an endoscopic lung retractor and a laser fibre-guide.

Operative Technique

General anaesthesia with endobronchial intubation is required to allow single lung ventilation. The patient is placed in the left lateral position (the right side is usually done first). A temperature probe is placed on the corresponding palm (Fig 1). A laser doppler flowmeter is also used to assess the palmar blood flow (Fig 2). The right lung is collapsed by excluding it from the ventilatory circuit. The pneumothorax is created and maintained by exposure to atmospheric pressure.

Fig 1 – The temperature monitor in the patient's palm.

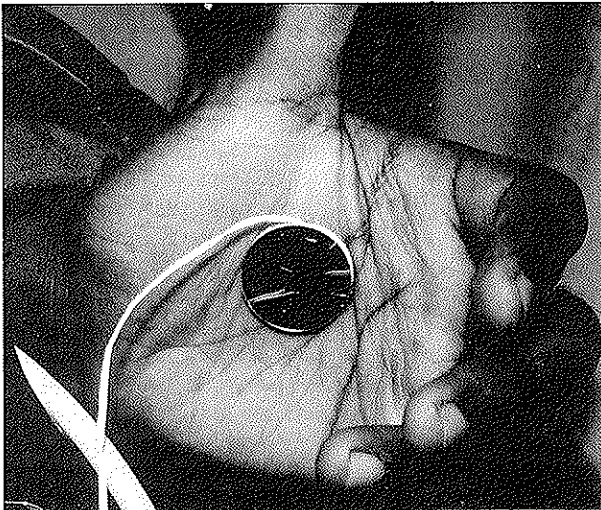
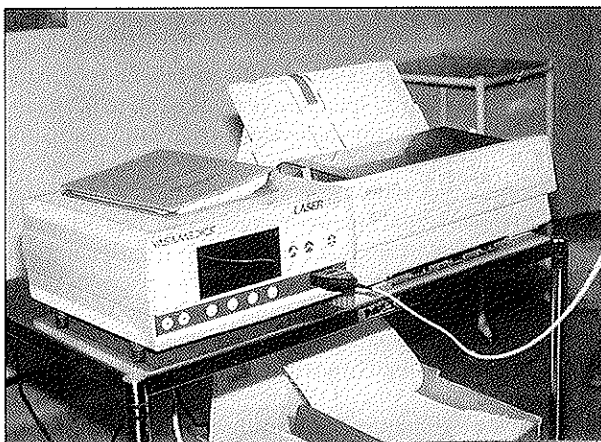
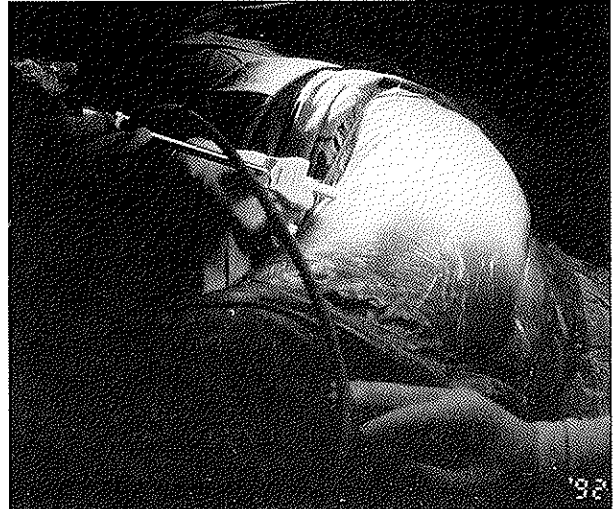


Fig 2 – The laser doppler flowmeter used to assess blood flow to the palms before and after surgery.



Through stab incisions 3 ports are introduced: a 10mm camera port in the 5th intercostal space in the mid-axillary line, 5mm instrument ports in the 3rd and 4th intercostal spaces in the anterior axillary line (Fig 3). The operation is carried out using video monitoring. The sympathetic chain is identified as it runs over the necks of the ribs. The 3rd rib, with the T2 ganglion usually lying on its neck, is identified by counting down from the thoracic apex.

Fig 3 – The patient in the lateral position with the endoscopic ports in place



The parietal pleura over the ganglion is divided to expose it. Ablation is accomplished either by excision or laser coagulation of the ganglion (Fig 4 and 5). Successful ablation is heralded by an immediate rise in the skin temperature of the corresponding hand by up to 1°C. Haemostasis followed by lung re-expansion, placement of a single chest tube and wound closure completes the surgery. The patient is then turned to the right lateral position and the same procedure is carried out on the left side.

The chest tubes are usually removed the next day and the patient mobilised. The patient is usually home by the second or third post-operative day.

RESULTS

We achieved successful surgery in 10 patients. There was one patient, a 34-year-old female, in whom dense adhesions were seen on entering the right pleural cavity. The procedure was abandoned because difficult dissection was anticipated. She had a normal pre-operative chest X-ray. This patient had a past history of ovarian cystectomy and medical treatment of thyrotoxicosis. It is interesting to speculate that the unexpected pleural adhesions were the aftermath of a Meig's syndrome (ovarian cyst with pleural effusion). She was scheduled for open sympathectomy via the dorsal midline approach instead.

The average operating time was one hour for the first side and 45 minutes for the next side. The average hospital stay was 4 days (including one day pre-operatively). There was no significant morbidity. In all cases there was histological confirmation of sympathetic ganglion excision. In all 10 successful cases the patients reported great satisfaction with the results of the procedure. The longest period of follow-up has been one year and there has been no report of any recurrence of hyperhidrosis.

Fig 4 – Endoscopic view of the second thoracic sympathetic ganglion running over the third rib as it is about to be excised.

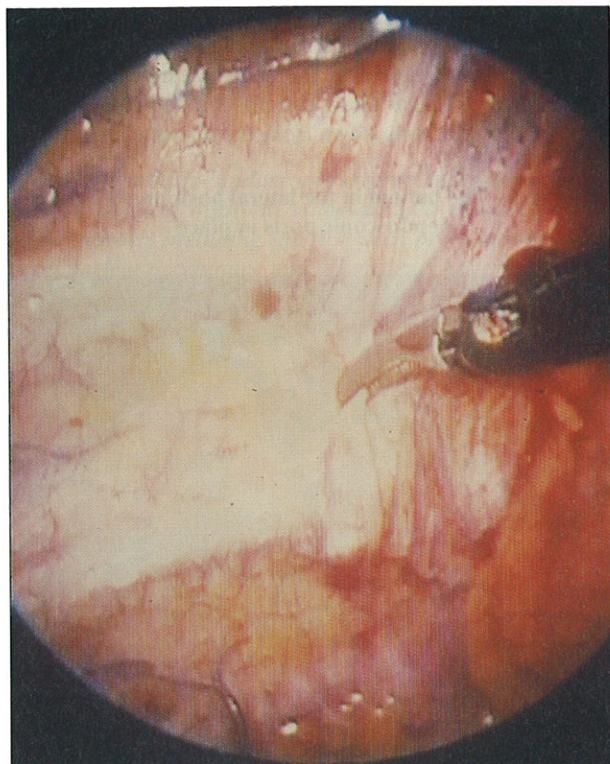
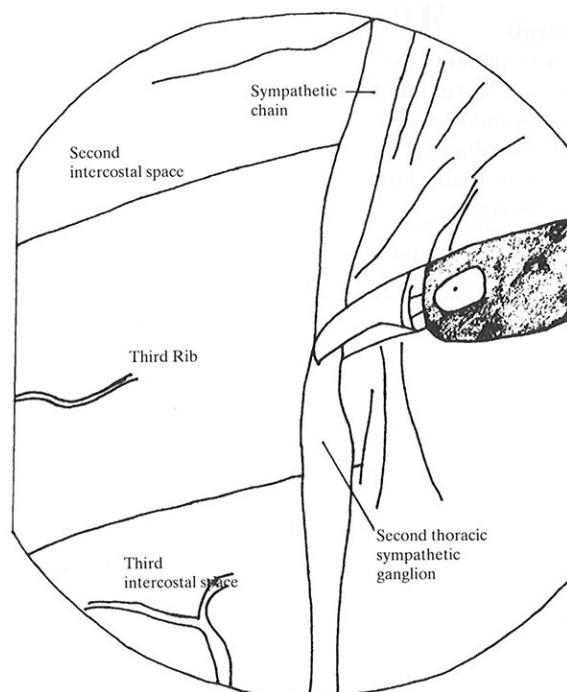


Fig 5 – Illustrative diagram of Fig 4.



DISCUSSION

Indications and contraindications

The most successful use of thoracic sympathectomy to date has been in the relief of intractable palmar hyperhidrosis. It is the most common indication for thoracic sympathectomy worldwide. There has been no truly satisfying medical treatment for it. Thoracic sympathectomy offers a greater than 95% chance of satisfactory amelioration of the problem.

The use of sympathectomy in a number of other conditions such as upper limb causalgia, rest pain of peripheral vascular disease and Raynaud's phenomenon is well recognised in carefully selected patients but has not met with as much success and perhaps two out of every three patients report useful relief of symptoms.

A rare and interesting indication for thoracic sympathectomy is in the treatment of intractable ventricular arrhythmias from the long Q-T syndrome. About 80% of these patients are controlled with medication after an extensive left thoracic sympathectomy.

The endoscopic technique may be used to achieve sympathetic chain ablation in all these conditions. The reasons behind the rapid adoption of this technique aside from its obvious minimally invasive nature (with lower morbidity and greater patient acceptance) are the better visualisation offered and the possibility of carrying out bilateral procedures in a single session.

The endoscopic technique is best avoided in patients in whom difficult dissection is anticipated i.e. patients with previous pulmonary tuberculosis, pleurisy, chest surgery, etc.

Surgical Anatomy and Physiology

The innervation of the sweat glands is by the sympathetic cholinergic nerves. The sympathetic innervation of the

upper extremity arises from the preganglionic fibres leaving the second to tenth thoracic anterior spinal rami (via the white rami communicantes)⁽⁹⁾. These fibres enter and synapse within the sympathetic chain. The postganglionic fibres leave the sympathetic chain from the middle cervical and stellate ganglia. From these ganglia the postganglionic fibres join the roots of the brachial plexus (via the grey rami communicantes) and are distributed to the upper limb⁽⁹⁾.

The aim of surgery is to achieve ablation of the second thoracic (T2) sympathetic ganglion (which usually overlies the neck of the 3rd rib). When axillary hyperhidrosis is also a problem the T3 ganglion is also ablated. The consequence of successful surgery is a warm, dry hand.

Prior to the popularisation of the endoscopic approach, thoracic sympathectomy for palmar hyperhidrosis was known for its efficacy and safety. Two of the largest series of the era^(5,6) reported no mortality and a 2.5% to 5% complication rate. These included wound infections, pneumonia, pneumothorax, cerebrospinal fluid leak, Horner's syndrome, spinal cord injury and empyema. The risk of Horner's syndrome was minimised by avoiding any resection of the Stellate ganglion. On long term follow-up, more than 95% of patients remained satisfied with the surgical result for postoperative periods of up to 6.5 years. Causes for dissatisfaction included compensatory sweating (usually noted on the chest and abdomen due to thermoregulation and seen in up to one-third of patients), intercostal neuralgia, incisional appearance and recurrent sweating (seen in <1% of patients possibly from incomplete resection or neural regeneration).

The initial efforts at endoscopic sympathectomy were made with single puncture techniques where the telescope had a single working channel through which the surgeon looked while passing the diathermy probe, suction apparatus and grasping forceps separately. Although adequate for safe

and effective surgery in experienced hands the ergonomics were not ideal. The present generation of video-endoscopes has allowed the development of a two-handed operating technique where there are separate ports for the video-endoscope (operated by the assistant), suction/diathermy and other instruments (handled by the surgeon who operates while looking at the video-monitor) which mimics the conditions of open surgery best and allows the surgeon the optimal control of exposure, dissection and haemostasis. This has been our experience and that of other workers using the latest equipment. The minimal morbidity of the additional small incisions is well worth the better anatomic identification and safer surgery that comes with the improved visualisation.

Along with the newer techniques of minimal access surgery have come simpler methods of ablation of the sympathetic ganglia. The sympathetic ganglia were excised during the era of open surgery. With the use of the endoscope, most workers have resorted to simple diathermisation of the relevant ganglion with the electrocautery unit. Others have reported using lasers (both Nd-YAG and CO₂)^(10,11), radiofrequency probes⁽¹²⁾ and chemical sympathectomy (using phenol injections). Although all the reports claim good initial results, there are no long term results available for comparison of the various techniques. The question of possible sympathetic neuron regeneration has also not been addressed in the situations where the sympathetic chain, although diathermised, is still in anatomic continuity. One of the aims of our study is to address this issue by excising the ganglion on one side and diathermising it on the contralateral side.

Although we have employed prophylactic post-operative chest drainage in our initial series of patients, we have not seen any cases of haemothorax. Our experience suggests that visual confirmation of haemostasis and a post-operative chest radiograph to exclude a post-operative pneumothorax may be all that is necessary and that chest intubation may be dispensed with for the majority of patients. This has also been the experience of other workers in the field.

At the last review there are close to 1,000 cases of endoscopic thoracic sympathectomy for hyperhidrosis reported in the recent literature. All these reports confirm that it is as effective as open surgery with more than 95% of patients reporting satisfactory relief of symptoms. The main post-operative side-effect was compensatory and gustatory sweating. No mortality was reported and all reported low morbidity. Claes et al in their series of 450 patients reported 2 post-operative pneumothoraces, one haemothorax and one Horner's syndrome. The median hospital stay was one

day (range 1 to 8 days), and return to work was 4 days (range 1-40 days)⁽³⁾. Chou et al in their series of 112 patients reported 5 patients requiring chest drainage. The average hospital stay for their patients was 3 days⁽¹³⁾. Bryne et al in their review of the first 112 patients found transient Horner's syndrome in 3, surgical emphysema in 3 and pneumothorax requiring chest drainage in one. The mean hospital stay was 3 days (range 1-7 days)⁽¹⁴⁾.

The results in our initial 10 patients undergoing endoscopic sympathectomy are similar to the reported series. All patients reported satisfactory amelioration of their symptoms. There was no significant morbidity. Three of the 10 have reported compensatory sweating over the chest and thighs but are not bothered by it.

CONCLUSION

In conclusion, the endoscopic technique represents a significant advance over open surgery. With the present state-of-the-art equipment, very good relief of hyperhidrosis can be achieved at minimum disturbance to the patient and at minimal cost. It has become the route of first choice for thoracic sympathectomy at our institution and this reflects the trend worldwide.

REFERENCES

1. Hardy RW, Bay JW. Surgery of the sympathetic nervous system. In: Schimidt HH, Sweet WJ, eds. Operative neurosurgical techniques. 2nd ed. Florida: Grune and Stratton. 1988:1271-4.
2. Edmonson RA, Banerjee AK, Rennie JA. Endoscopic transthoracic sympathectomy in the treatment of hyperhidrosis. *Ann Surg* 1992; 215:289-93.
3. Claes G, Drott C, Gotlberg G. Endoscopic electrocautery of the thoracic sympathetic chain. A minimally invasive way to treat palmar hyperhidrosis. *Scand J Plast Reconstr Surg Hand Surg* 1993; 27:29-33.
4. Kux E. Thorakoskopische Eingriffe am Nervensystem. Stuttgart: Georg Thieme Verlag. 1954.
5. Shih C, Wang Y. Thoracic sympathectomy for palmar hyperhidrosis: report of 457 cases. *Surg Neurol* 1978; 10:291-6.
6. Pillay PK, Awad IA, Little JR, Dohn DF, Bay JW. Upper thoracic sympathectomy for essential palmar hyperhidrosis: Cleveland Clinic experience with 440 cases. Proceedings of the 39th Annual Meeting of the Congress of Neurological Surgeons. Atlanta, Georgia. 1989:217.
7. Cloward R. Hyperhidrosis. *J Neurosurg* 1969; 30: 545-51.
8. Tan KK. Sympathectomy for wet, dripping palms. *Singapore Med J* 1991; 32:119-20.
9. Pick J. The autonomic nervous system. Philadelphia: JB Lippincott. 1970.
10. Chung HY, Seo CG, Lee SG. Video endoscopic sympathectomy using a fiberoptic CO₂ laser to treat palmar hyperhidrosis [letter]. *Neurosurgery* 1993; 32:327-9.
11. Kao MC. Laser endoscopic sympathectomy for palmar hyperhidrosis. *Lasers Surg Med* 1992; 308-12.
12. Massad M, LoCicero J, Matano J, Oba J, Greene R, Gilbert J, et al. Endoscopic thoracic sympathectomy: evaluation of pulsatile laser, non-pulsatile laser and radiofrequency generated thermocoagulation. *Lasers Surg Med* 1991; 11:18-25.
13. Chou SH, Lee SH, Kao EI. Thoracic endoscopic T2-T3 sympathectomy in palmar hyperhidrosis: experience of 112 cases. *Surg Today* 1993; 23:105-7.
14. Byrne J, Walsh TN, Hederman WP. Endoscopic transthoracic electrocautery of the sympathetic chain for palmar and axillary hyperhidrosis. *Br J Surg* 1990; 77:1046-9.