

FATAL HAEMOPTYSIS IN *SALMONELLA* *TYPHIMURIUM* SEPTICAEMIA – A CAUTIONARY TALE

H C Tan, R K T Chan, W C Tan

ABSTRACT

Septicaemia and mycotic aneurysm may occur in a patient who is an enteric-carrier of Salmonella typhimurium. We report such a case of an elderly man who presented with chest pain and fatal massive haemoptysis from a likely mycotic thoracic aneurysm. This report underscores the importance of increased awareness of the disease which may allow more frequent and earlier diagnosis.

Keywords: *Salmonella septicaemia, massive haemoptysis, mycotic thoracic aneurysm, enteric-carrier.*

SINGAPORE MED J 1994; Vol 35: 525-526

INTRODUCTION

Arteritis with or without mycotic aneurysm is a known complication of *Salmonella* septicaemia⁽¹⁾. These are usually found in the abdominal aorta. In those cases of aortitis involving the thoracic aorta, the lower thoracic aorta is more frequently involved⁽²⁻⁴⁾. We report a case of fatal haemoptysis from a likely upper aortic aneurysm in an elderly patient who was a chronic enteric-carrier of *Salmonella typhimurium*.

CASE REPORT

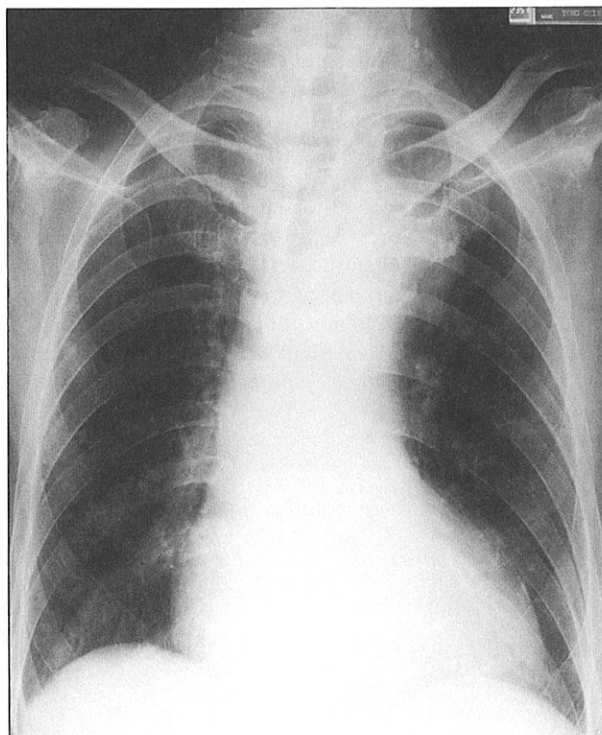
A 90-year-old Chinese man was admitted with a two-week history of constant dull ache in the left upper chest radiating to the left shoulder, and aggravated by shoulder movements. This was associated with a 1-week history of occasional blood-stained sputum.

The patient suffered from ischaemic heart disease and had a previous history of congestive cardiac failure. Six months before the current admission, he had been investigated for acute non-febrile, lower abdominal pain with watery diarrhoea, which was relieved promptly with symptomatic treatment. Three subsequent stool cultures two months apart had grown *Salmonella typhimurium*. The patient was then treated with a 1-week course of trimethoprim-sulfamethoxazole and a repeat stool culture was reported to be clear of the organism.

On admission the patient was alert, cheerful and afebrile. Examination revealed mild tenderness over the anterior left upper chest, and bilateral basal crepitations. Respiratory rate was 20 per min; heart rate was 90/min; blood pressure was 155/93; radial and femoral pulses were felt to be equal. No murmur or pleural rub was heard. ECG tracing was within normal limits. A chest radiograph showed a

homogenous opacity in the left lung apex which was absent in a previous chest X-ray (Fig 1). A likely diagnosis of bronchogenic tumour was made. Five days after admission, the patient became febrile with axillary temperature of 38°C, and frequent expectoration of blood-stained sputum. He became intermittently confused. Blood samples were taken for culture and treatment for septicaemia initiated empirically with intravenous ceftriaxone and gentamicin. A repeat chest X-ray showed that the left apical mass had enlarged (Fig 2). Over the next few days the patient continued to have small amounts of haemoptysis and remained ill. On the morning of the fourth day after the start of antibiotic therapy, he suddenly had massive haemoptysis and expired. A litre of fresh blood was aspirated from the oropharynx during resuscitation. Consent for post-mortem examination was not given. Blood culture reports, available after the death of the patient, showed a

Fig 1 – Chest radiograph of the patient on admission, showing a left apical opacity.



Department of Medicine
National University Hospital
Lower Kent Ridge Road
Singapore 0512

H C Tan, M Med (Int Med)
Registrar

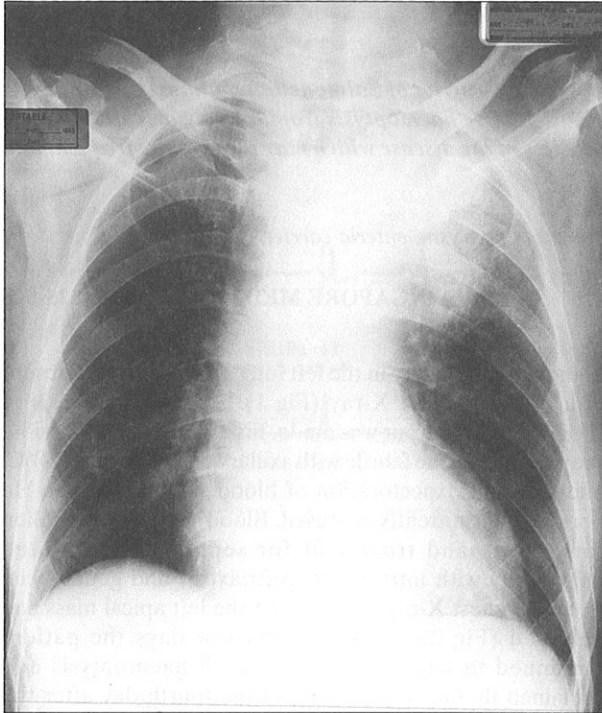
R K T Chan, MRCP (UK)
Resident

W C Tan, FRCP (Edin), FRACP
Professor

Correspondence to: Prof W C Tan

growth of *Salmonella typhimurium* with in-vitro sensitivities to ceftriaxone and gentamicin.

Fig 2 – Chest radiograph 6 days after admission, showing a marked enlargement of the apical mass.



DISCUSSION

Three potential diagnoses, namely ruptured mycotic aneurysm, septic pulmonary infarction and necrotising pneumonia, could explain the persistent haemoptysis in this patient. However the clinical presentation; the site, appearance and subsequent development of the radiological lesion; the bacteriological findings; and the dramatic fatal outcome of this case strongly support the diagnosis of *Salmonella* septicaemia with rupture of a mycotic aneurysm of the thoracic aorta, despite the absence of a definitive diagnosis by arteriography or post-mortem examination.

The presence of a persistent fever, localised chest pain, haemoptysis and a rapidly enlarging pulmonary shadow should have alerted the physician to the possibility of a mycotic aneurysm of the thoracic aorta although this is a rare event⁽³⁻⁵⁾. Serial chest X-rays of this patient had revealed an expanding homogenous, left apical mass which was contiguous with and radiating from the aortic arch. A high level of suspicion should have been applied particularly in this setting of an elderly patient with atherosclerosis and a previous history of being a *Salmonella* stool carrier.

Massive haemoptysis is a well recognised life-threatening complication of bacterial endocarditis. Bleeding originates most often from mycotic aneurysms of the pulmonary artery, or embolic septic pulmonary infarcts but rarely from the subclavian artery⁽⁵⁾. Mycotic aortic aneurysms secondary to bacterial endocarditis usually occur in the ascending aorta⁽⁶⁾. In contrast, the mycotic aneurysms associated with *Salmonella* bacteraemias are found mostly in the abdominal aorta^(1,7). Mycotic aneurysm of the thoracic aorta due to *Salmonella* species is uncommon and is predominantly located in the lower thoracic aorta^(2,3). To our knowledge, haemoptysis from aortobronchial fistula has been reported in only two previous cases⁽³⁾.

Angiography remains the mainstay of investigation for aneurysms although non-invasive ultrasonography and computerised tomography have been useful in confirming a clinical suspicion of mycotic aneurysm⁽⁸⁾. The definitive treatment is surgical resection of the aneurysm coupled with the administration of appropriate and high dose bactericidal antibiotic^(7,8).

This case raises two important lessons. First, mycotic aneurysm of the aorta is a potentially fatal condition. Persistent haemoptysis in a febrile patient with a rapidly enlarging radiological opacity should raise the clinical suspicion of a mycotic aneurysm. The only hope of averting a tragic outcome lies in prompt clinical recognition and confirmation followed by definitive treatment. Appropriate antibiotic without surgery was inadequate in this case. Second, eradication of the *Salmonella* carrier state is difficult and requires much extensive search for a potential source of infection such as the gall-bladder. A single negative stool culture after one course of antibiotic therapy is no proof of such eradication⁽⁹⁾. Close surveillance of this high-risk patient should have remained as long as the enteric-carrier status persisted.

REFERENCES

1. Cohen PS, O'Brien TF, Schoenbaun SC, Medeiros AA. The risk of endothelial infection in adults with *salmonella* bacteraemia. *Ann Intern Med* 1978; 89:931-2.
2. Colledge CL, McGeachie DB. Mycotic aneurysm of the thoracic aorta by *salmonella typhimurium*. *Med J Aust* 1988; 149:94-5.
3. Oskoui R, Davis WA, Gomes MN. *Salmonella* aortitis. A report of a successfully treated case with a comprehensive review of the literature. *Arch Intern Med* 1993; 153:517-25.
4. Johansen K, Devin J. Mycotic aortic aneurysm – a reappraisal. *Arch Surg* 1983; 118:583-8.
5. Cosmos LY, Risi G, Nelson S, Subramanian P, Martin D, Haponik EF. Fatal haemoptysis in acute bacterial endocarditis. *Am Rev Respir Dis* 1988; 137:1223-6.
6. Castaneda-Zuniga WR, Noth PH, Zollikofer C, Velasquez G, Valdez-Davilla O, Edwards E. Mycotic aneurysm of the aorta. *Cardiovasc Intervent Radiol* 1980; 3:144-9.
7. Kains J, Dereume JP, Jacobs F, Legrand JC, Wantrecht JC, Thys JP. *Salmonella* endarteritis, about two cases and their management. *J Cardiovasc Surg* 1987; 28:538-41.
8. Gonda RL, Gutierrez OH, Azodo MVU. Mycotic aneurysms of the aorta: radiologic features. *Radiology* 1988; 168:343-6.
9. Hook EW. *Salmonella* species. In: Mandell GE, Douglas RG, Bennett JE. ed. *Principles and Practice of Infectious Disease* 3rd ed. United Kingdom: Churchill Livingstone, 1990:1713.