

# THE NEW TITANIUM GREENFIELD VENA CAVA FILTER: INITIAL EXPERIENCE AND REVIEW

M C L Lim, H C Tan, M H Choo

## ABSTRACT

*The Greenfield vena cava filter is an established therapeutic option in the prevention of pulmonary embolism. The development of a 12 French modified titanium Greenfield filter (TGF) has made it possible to insert the filter percutaneously and to have a low complication rate. We report our initial experience with percutaneous insertion of the 12-French titanium Greenfield vena cava filter for 6 patients who all had major extensive deep venous thrombosis (DVT) and contraindications to anticoagulation.*

*The inferior vena cava (IVC) filters were inserted in all the 6 patients via the internal jugular route without difficulty. There was no bruising, haematoma or bleeding complications despite the use of the 12 French system. The IVC filter was opened without cross-snaring of the filter legs in all 6 patients. This was confirmed with cranio-caudal, left anterior oblique and right anterior oblique views of the deployed filter. There was however some asymmetry of the filter leg positions but it did not cause any significant angulation of the filter in relation to the IVC. The IVC filters were firmly secured with no filter migration immediately post-procedure.*

*The 12-French titanium Greenfield vena cava filter was safely deployed percutaneously with no complications in our small series of patients. With the use of titanium in the design of Greenfield filter, the clinical effectiveness and performance is maintained while providing for easier insertion and reduction of patient discomfort. Although anticoagulation remains the choice of treatment in DVT, the safety profile and efficacy of the modified TGF makes it an important therapeutic option in those with significant DVT who cannot be anticoagulated or have recurrent pulmonary embolism (PE).*

**Keywords:** vena cava filter, deep vein thrombosis, pulmonary embolism, titanium

SINGAPORE MED J 1994; Vol 35: 622-625

## INTRODUCTION

Pulmonary embolism (PE) has remained a significant medical cause of mortality and morbidity. Retrospective studies show a high association between embolism and venous thrombosis of the lower limbs and prospective studies have gone on to demonstrate that patients with venous thrombosis are at high risk of developing pulmonary embolism<sup>(1,2)</sup>.

Anticoagulation remains the primary therapy for deep venous thrombosis (DVT) and PE. It has been shown to reduce the rate of lethal PE to between 0.14% and 0.3% in patients with DVT and reduces the risk of recurrent lethal PE to between 0.9% and 1.3%<sup>(3,4)</sup>.

However, in specific patients with documented PE or DVT, anticoagulation may be contraindicated, may fail to control the thrombotic process or may offer inadequate protection against lethal PE. In these instances, a mechanical method of vena caval interruption is required to reduce the incidence of PE.

We report our initial experience with percutaneous insertion of the 12-French titanium Greenfield vena cava filter (TGF) for 6 patients who all had major extensive DVT and contraindications to anticoagulation. This is the first reported experience with this IVC filter in South-East Asia.

## PATIENTS AND METHODS

There were 3 males and 3 females with an age range of 37 to 63

---

Cardiac Department  
National University Hospital  
Lower Kent Ridge Road  
Singapore 0511

M C L Lim, M Med(Int Med), MRCP(UK), FAMS  
Senior Registrar

H C Tan, M Med(Int Med), MRCP(UK)  
Registrar

M H Choo, MD, M Med(Int Med), FRCP(UK)  
Professor and Chief

Correspondence to: Dr M C L Lim

---

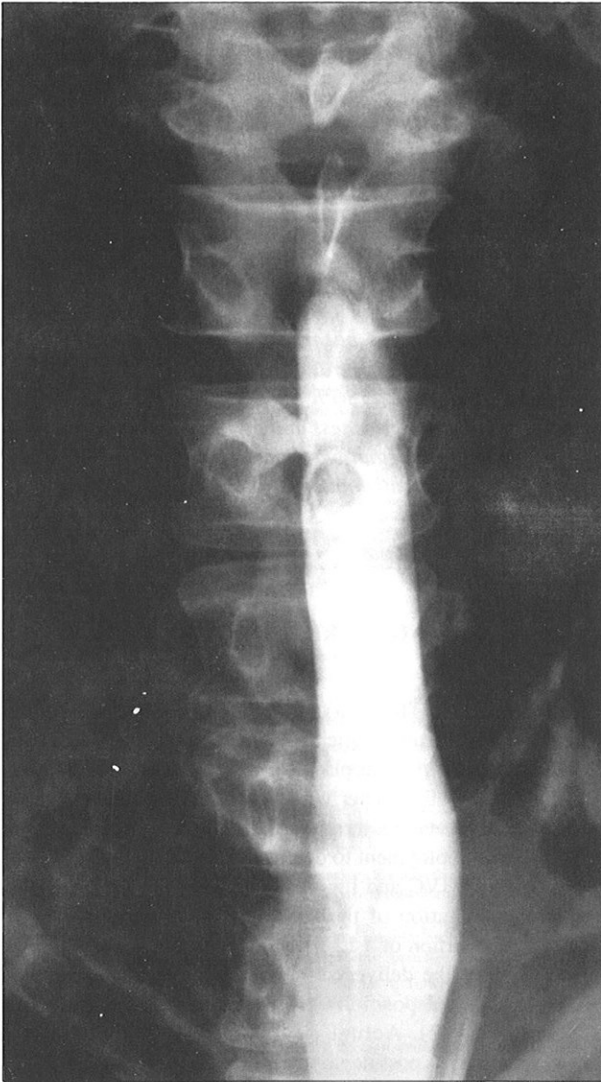
years in our series. The right internal jugular route was used for percutaneous insertion of the filter. Following venous access, a 0.038 inch J guidewire was placed in the inferior vena cava (IVC). A 5 French pigtail catheter was then placed in the distal IVC proximal to the venous thrombus. An inferior vena cavogram was done pre-deployment to determine the size of the IVC, the anatomy of the IVC and the origin of the renal veins (Fig 1). Sequential dilatation of the access site was performed with subsequent insertion of a 12 French sheath. This was followed by insertion of the delivery system containing the IVC filter. When the optimal position was obtained, the IVC filter was deployed (Fig 2). Actual deployment was recorded on cineangiography. A post-deployment inferior vena cavogram was performed to check the position of the IVC filter. All patients were sent to a general ward after the procedure.

## CASE REPORTS

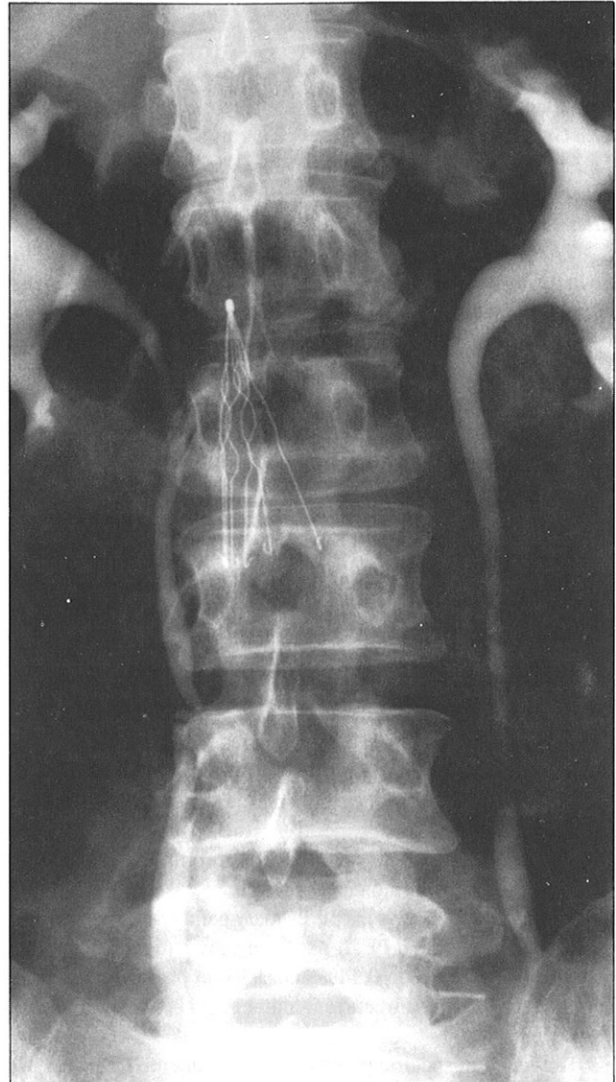
### Case 1

A 38-year-old mentally retarded Chinese woman, NML, was admitted for left lower limb swelling. She had a background history of menorrhagia from a large uterine fibroid measuring 22-week gravid uterus in size. Venogram and CT scan of pelvis confirmed extensive DVT in both lower limbs, with a large uterine fibroid causing bilateral ureteric obstruction. She was started on subcutaneous heparin but showed no improvement after 2 months. Surgical removal of the uterine fibroid was planned to relieve its venostatic effect on lower limb veins which perpetuate the thrombotic process. Duplex ultrasound of the lower limbs showed extensive bilateral lower limb DVT extending proximally to the iliac veins, rendering the patient at high risk for pulmonary embolism during the elective total abdominal hysterectomy and bilateral oophorectomy. As a prophylactic measure against massive pulmonary embolism, a modified Greenfield (Titanium) inferior vena caval filter was inserted via the right internal jugular route using a 12 French delivery system pre-operatively. The patient was started on oral warfarin after she recovered from the surgery. Follow-up of this patient 6 months later showed no complications.

**Fig 1 – A pre-deployment inferior vena cavogram showed thrombus extending to the distal inferior vena cava**



**Fig 2 – The titanium Greenfield filter is deployed in the inferior vena cava proximal to the thrombus.**



### Case 2

A 47-year-old Japanese man, HS, was admitted following a serious road traffic accident. He suffered multiple injuries including intra-abdominal injuries consisting of retroperitoneal haematoma, bladder haematoma, laceration of splenic tip and serosal tear to caecum and small bowel mesentery; orthopaedic injuries consisting of laceration of right occiput, severe comminuted fracture of the left superior and inferior pubic rami, fracture of the right iliac wing and superior pubic rami with a floating fragment and fractured sacrum with injury to the pelvic viscera; and lumbar plexus injury with bilateral lower limb paralysis. Emergency laparotomy was performed with splenorrhaphy and securing of haemostasis. One week after admission, he developed swelling and tenderness in his right lower limb. Duplex venous scan showed DVT in the right external iliac and common femoral veins. As anticoagulation was contraindicated and the risk of pulmonary embolism high, an IVC filter was inserted. He was given anti-embolic stockings and was started on anticoagulation when there was no surgical contraindication. He was hospitalised for 2 months during which he underwent intensive rehabilitation with subsequent recovery of his bladder and left lower limb function, with residual right lower limb weakness. Follow-up of the patient 12 months after

the accident showed resolution of leg swelling and no evidence of pulmonary embolism.

### Case 3

A 57-year-old Chinese man, NKT, was diagnosed to have brain tumour at another hospital. He went on to receive radiotherapy for his condition. During the course of hospitalisation, he developed deep venous thrombosis of his right lower limb extending proximally to the iliac veins for which anticoagulation was started. He was discharged relatively well. However, he was readmitted to our hospital with passage of fresh melaena and an International Normalised Ratio (INR) of 7.5. Subsequent gastroscopy revealed a bleeding antral ulcer and haemostasis was secured with intralesional injection of adrenaline and maintenance with intravenous omeprazole. Venous scan of his right lower limb showed thrombi in the right superficial femoral and popliteal veins. As anticoagulation was contraindicated, an IVC filter was inserted percutaneously as a prophylactic measure against PE. The patient subsequently developed signs of coning and an urgent computerised tomographic (CT) scan of the brain showed a 4 x 5cm tumour in the left parietal lobe with surrounding oedema. Craniotomy and excision of tumour was immediately performed and histology showed malignant oligoastrocytoma.

He responded well initially to steroid therapy and rehabilitation and was able to ambulate with support at one stage. He did not have any complications resulting from the IVC filter. However, he subsequently developed *Streptococcal fecalis* septicaemia from his sacral ulcer and succumbed a month after admission.

#### Case 4

A 47-year-old male Indian motorcyclist, MJE, was admitted following a road traffic accident. He sustained multiple injuries which included fracture-diastasis of right pelvis, diastasis of pelvic symphysis, fractured right superior ramus, fractured right 2nd to 6th rib, dislocated right shoulder, degloving injury of perineum, lung contusion and retroperitoneal haematoma. He underwent exploration of the perineal wound with transverse colostomy performed followed by external fixation of fractured pelvis and reduction of dislocated shoulder. On the 3rd week of his admission, he developed right lower limb swelling and a duplex ultrasound venous scan showed thrombus extending from the right superficial femoral vein to the popliteal vein. As anticoagulation was contraindicated, an IVC filter was inserted. His post-operative course was complicated by osteomyelitis of right posterior iliac bone and methicillin-resistant *Staphylococcus aureus* (MRSA) infection of the sacral wound with sinus formation. This was treated with intravenous vancomycin. During the later part of his hospitalisation, he received intravenous heparin and oral warfarin. After a prolonged course of treatment and rehabilitation, he was finally discharged 2 months after his admission with residual right foot drop from sacral plexus injury and colostomy for closure later on. There were no complications resulting from the IVC filter.

#### Case 5

A 46-year-old Chinese woman, TC, was found to have a sigmoid polyp following admission for complaint of bleeding per rectum. Surgical removal of the polyp was performed. The histology of the polyp was reported as benign. While in the ward, she developed swelling of the left lower limb and a duplex ultrasound scan revealed extensive DVT in the left iliac and lower limb veins. Because of recent surgery performed, anticoagulation was contraindicated and an IVC filter was inserted. The patient was subsequently started on warfarin as an outpatient. After 3 months of oral warfarin, a repeat duplex ultrasound scan showed that there was residual DVT in the left common and superficial femoral veins. She was subsequently continued on warfarin.

#### Case 6

A 63-year-old Chinese lady, NGE, with hypertension was admitted with sudden onset of aphasia and right-sided weakness. A CT scan of the brain showed a right parietal haemorrhage. Her stay in the hospital was complicated by acute renal failure secondary to an atonic bladder, urinary tract infection and subacute intestinal obstruction. Two weeks after admission, the patient developed right lower limb swelling. A duplex ultrasound scan showed extensive DVT of the right lower limb extending to the iliac veins. A repeat CT scan showed extension of haemorrhage at the site of the initial parietal haemorrhage. As anticoagulation was contraindicated, an IVC filter was inserted as a prophylactic measure against massive pulmonary embolism. The patient was discharged after 4 weeks of hospitalisation. She was commenced on warfarin therapy as an outpatient and had no complication resulting from the IVC filter on review 2 months after discharge from the hospital.

## RESULTS

The IVC filters were inserted in all the 6 patients via the internal

jugular route without difficulty. There was no bruising, haematoma or bleeding complications despite the use of the 12 French system. No pressure bandage was required.

The site of the lowest renal vein was at mid L2 in 2 patients, mid L1 in one patient and L1-L2 intervertebral space in 3 patients. The IVC filter was deployed with its proximal end between the lower border of L1 and L2-L3 intervertebral space in the 6 patients under fluoroscopic guidance. At these positions, the proximal ends of the IVC filters were at or distal to the renal vein origin. The IVC filter was opened without cross-snaring of the filter legs in all 5 patients. This was confirmed with cranio-caudal, left anterior oblique and right anterior oblique views of the deployed filter. There was however some asymmetry of the filter leg positions but it did not cause any significant angulation of the filter in relation to the IVC. The IVC filters were firmly secured with no filter migration immediately post-procedure. There were no bleeding complications at the right internal jugular puncture site.

## DISCUSSION

Although most patients with DVT or PE can be managed by anticoagulation alone, it may be necessary to provide mechanical protection in the form of vena caval filter in certain situations. Some of the common indications for vena caval filter include patients who have contraindications to anticoagulation (preexisting bleeding disorders, active or recent neurologic, pulmonary, gastrointestinal or urologic bleeding, recent ophthalmic or neurologic surgical procedures, after major trauma), complications of anticoagulation warranting discontinuation, failed anticoagulation (documented recurrent pulmonary embolism, progressive DVT), embolectomy patients (at high risk of recurrent PE in spite of anticoagulation), prophylaxis against PE (eg free-floating or poorly adherent proximal thrombus on venogram, chronic pulmonary hypertension or impaired respiratory reserve) and treatment of septic thromboembolic disease as an important adjunct to appropriate systemic antibiotic therapy<sup>(5)</sup>.

The history of vena caval interruption dates back to the late eighteenth century when Hunter first performed femoral vein ligation on a patient with DVT to prevent pulmonary embolism. In 1934, Homan advocated ligation of the common femoral vein below the saphenous veins as the procedure of choice to improve results. However, recurrent PE still occurred in spite of bilateral common femoral vein ligation. In the mid-1940s, Oschner and DeBakey tried complete ligation of the IVC with reduction of incidence of recurrent PE but with a high level of postoperative morbidity and mortality. Partial interruption using suturing, clipping or stapling through operative means was still met with high level of postoperative complications because these patient were often seriously ill to begin with.

Transvenous techniques of introducing caval interruptor emerged with the implantation of Mobin-Uddin umbrella and Hunter balloon. These implants however have several disadvantages, notably failure to promote clot lysis, predisposition to development of caval thrombosis with disastrous consequences and reports of migration of umbrella to lungs with fatal outcome.

The Greenfield vena cava filter (SGF) became the preferred choice in prevention of pulmonary embolism with its first use in 1972. Its established record safety and effectiveness with long term patency rates in excess of 95% in the experience of some institutions<sup>(6)</sup>, has consolidated its predominance among the mechanical caval interruptors. SGF has become the 'gold standard' for safety and efficacy for which future mechanical devices are compared to. The predictable patency is a result of

the cone-shaped design that allows emboli to be trapped without occlusion of the IVC, thereby providing subsequent spontaneous thrombolysis independent of anticoagulation.

A modification of the original SGF, which was made of stainless steel, in the form of a titanium alloy model (TGF) permits the percutaneous insertion of the device through a 12 French sheath. This minimises the risk of post-insertion venous thrombosis and obviates the need for surgical insertion as required in the 24 French delivery system used for the SGF.

In all 6 of the patients here, TGF was inserted successfully using the percutaneous introducer system. The internal jugular route appears to be a convenient route without the potential risk of dislodging thrombus from the IVC or the iliac veins if the femoral venous route was used. There were no complications related to the insertion technique. One of the patients died postoperatively from progression of underlying disease. No pulmonary embolism episodes were documented following the deployment of the filter.

Despite its high safety profile, one still has to adhere to certain principles and precautions in the prevention of complications. Firstly, preoperative venography must be done to define the IVC anatomy and avoid misplacement of the IVC filter especially where there are anatomic variations<sup>(7)</sup>. Secondly, the use of a guide wire is required to facilitate passage of the introducer and for accurate intracaval position. Thirdly, intra-procedural technical errors must be quickly recognised and promptly corrected. Finally, meticulous postoperative follow-up is mandatory<sup>(8)</sup>.

The complications, albeit rare, that may arise from SGF insertion include those occurring due to venous anomalies (eg double vena cava), during filter insertion (malpositioning, failure to open) and postoperative complications (caval perforation with retroperitoneal haematoma, filter migration, bowel obstruction)<sup>(9-17)</sup>. The incidence of pulmonary embolism has been consistently quoted as 4% in a few reports<sup>(6,18)</sup>.

TGF is ideally placed at the level of the lowest renal vein where the venous haemodynamics in that portion of the IVC enhances natural lysis of entrapped embolus. Compared to SGF, TGF enjoys the same advantages of high caval patency, effective filtration, enhancement of clot resolution, durability, non-thrombogenicity, corrosion-resistance but is superior in withstanding extensive flexion stress and has greater lateral force allowing for wall fixation. The initial TGF was complicated by IVC perforation and injury to pericaval organs and blood vessel and significant filter migration<sup>(19)</sup>. The hooks of the TGF were subsequently modified and experience has shown the use of the modified TGF to be associated with low complication rates; 0.8% of the patients showed evidence of caval penetration<sup>(20)</sup>.

## CONCLUSIONS

The 12-French titanium Greenfield vena cava filter was safely deployed percutaneously with no complications in our small series of patients. With the use of titanium in the design of Greenfield filter, the clinical effectiveness and performance is maintained while providing for easier insertion and reduction of patient discomfort. Although anticoagulation remains the choice of treatment in DVT, the safety profile and efficacy of the modified TGF makes it an important therapeutic option in those with significant DVT who cannot be anticoagulated or have recurrent PE.

## REFERENCES

1. Hunter WC, Sneed VD, Robertson TD, Synder GAC. Thrombosis of deep veins of the leg: its clinical significance as exemplified by three hundred and fifty-one autopsies. *Arch Intern Med* 1941; 68:1-17.
2. Browse NL, Thomas LM. Source of nonlethal pulmonary embolism. *Lancet* 1974; i:258-9.
3. Heath FK. Combined Staff Clinic on thromboembolism. *Am J Med* 1947; 3:753-68.
4. Coon WW, Willis PW, Symons MJ. Assessment of anticoagulant treatment of venous thromboembolism. *Ann Surg* 1969; 170:559-67.
5. Jones TK, Barnes RW, Greenfield LJ. Greenfield vena caval filter: rationale and current indications. *Ann Thorac Surg* 1986; 42:48-55.
6. Greenfield LJ, Michna BA. Twelve year clinical experience with the Greenfield vena cava filter. *Surgery* 1988; 104:706-12.
7. Martin KD, Kempczinski RF, Fowl RJ. Are routine inferior vena cavograms necessary before Greenfield filter placement? *Surgery* 1989; 106:647-50.
8. Carabasi RA, Moritz MJ, Jarrell BE. Complications encountered with the use of the Greenfield filter. *Am J Surg* 1987; 15:163-8.
9. Collins DN, Barnes CI, McCowan TC, Nelson CL, Carver DK, McAndrew MP, et al. Vena caval filter use in orthopaedic trauma patients with recognised preoperative venous thromboembolic diseases. *J Orthop Trauma* 1992; 6:135-8.
10. Kupferschmid JP, Dickson CS, Townsend RN, Diamond DL. Small bowel obstruction from an extruded Greenfield filter strut: an unusual late complication. *J Vasc Surg* 1992; 16:113-5.
11. Burandt TM, Jarski RW. Small-bowel obstruction by adhesions secondary to caval perforation by Greenfield vena cava filter. *J Am Osteopath Assoc* 1988; 88:1239-41.
12. Geisinger MA, Zelch MG, Risius B. Recurrent pulmonary embolism after Greenfield filter placement. *Radiology* 1987; 165:383-4.
13. Otchy DP, Elliot BM. The malpositioned Greenfield filter, lessons learned. *Am Surg* 1987; 53:580-3.
14. Taheri SA, Kulayat MN, Johnson E, Hoover E. A complication of the Greenfield filter; fracture and distal migration of 2 struts - a case report. *J Vasc Surg* 1992; 16:96-9.
15. Appleberg M, Crozier JA. Duodenal perforation by a Greenfield caval filter. *Aust N Z J Surg* 1991; 61:957-60.
16. Mewissen MW, Erickson SJ, Foley WD, Lipchik EO, Olson DL, McCann KM, et al. Thrombosis at venous insertion sites after inferior vena cava filter placement. *Radiology* 1989; 173:155-7.
17. Dorfman GS, Cronan JJ, Paoletta LP, Lambiase RE, Haas RA, Scola FH, et al. Iatrogenic changes at the venotomy site after percutaneous placement of the Greenfield filter. *Radiology* 1989; 173:159-62.
18. Greenfield LJ. Current indications for and results of Greenfield filter placement. *J Vasc Surg* 1984; 1:502-4.
19. Teitelbaum GP, Jones DL, Breda AV, Matsumoto AH, Fellmeth BD, Chespak LW, et al. Vena cava filter splaying: potential complications of use of the Titanium Greenfield filter. *Radiology* 1989; 173:809-14.
20. Greenfield LJ, Cho KJ, Proctor M, Bonn J, Bookstein JJ, Castaneda-Zuniga WR, et al. Results of a multicenter study of the modified hook-titanium Greenfield filter. *J Vasc Surg* 1991; 14:253-7.