

INTRAHERNIAL TUMOUR – A CASE REPORT

M Y P Chan, B K Ng

ABSTRACT

Intrahernial tumour is an uncommon entity. Up to 1980, there are 23 reported cases of primary intrahernial tumours. Suspicion should arise when a longstanding hernia has recently become incarcerated. This is the first reported case of primary tumour of the transverse colon found within a paraumbilical hernia presenting with obstruction.

Keywords: paraumbilical hernia, tumour

SINGAPORE MED J 1994; Vol 35: 646-647

INTRODUCTION

Since the first report of intrahernial tumour by Arnaud in 1749⁽¹⁾, there have been few documented cases of this nature. Review by Roslyn⁽²⁾ in 1980 showed 23 cases of primary tumours in groin hernias. This is despite the fact that although both intra-abdominal cancers and external hernias are common occurrences, the two are rarely linked together⁽³⁾. This is the first reported case of primary tumour of the transverse colon presenting in a paraumbilical hernia.

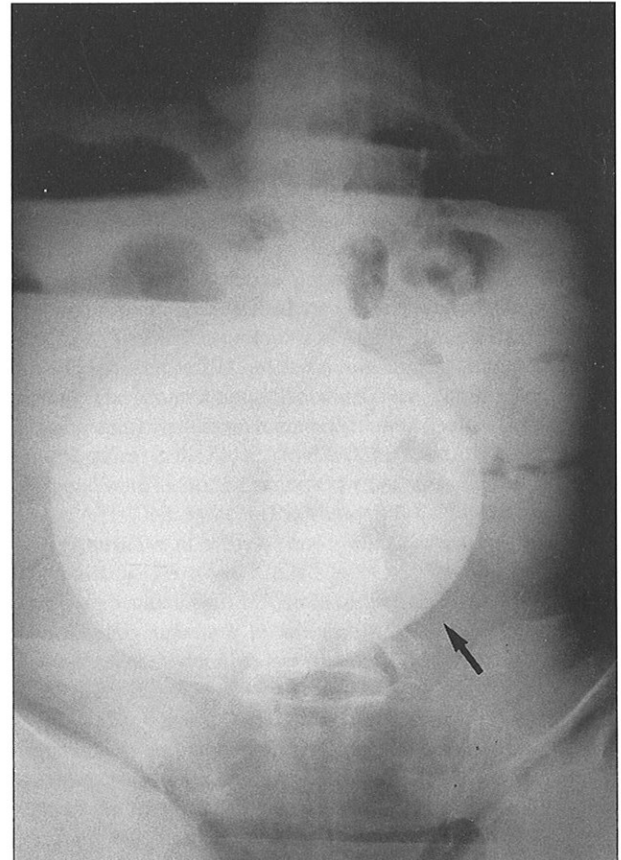
CASE REPORT

A 83-year-old lady was admitted for tenderness in the paraumbilical hernia which had been present for the past 10 years and had only recently become irreducible. She had vomiting and constipation for one day. She had no recent weight loss or change in bowel habits. Clinically she was dehydrated and in atrial fibrillation. There was a large tender paraumbilical hernia with no cough impulse. Abdomen was distended and bowel sounds were hyperactive. Abdominal X-ray (Fig 1) showed dilated small bowel loops with multiple fluid levels and a large paraumbilical hernia. Preoperative diagnosis of obstructed paraumbilical hernia with impending strangulation was made and emergency operation was carried out. At operation an obstructing tumour of the transverse colon was found in the hernia. Extended right hemicolectomy was performed with ileocolic anastomosis. Histology confirmed a Duke's B moderately differentiated adenocarcinoma of the transverse colon. The patient developed a massive stroke six hours later and required ventilatory support. Seven days later, faecal discharge was noted from the drain site and laparotomy was performed which showed gangrene of the terminal ileum of 40 cm long. It was resected and end ileostomy and colostomy was performed. She died 35 days after the second operation of aspiration bronchopneumonia.

DISCUSSION

Tumours in hernia can be either metastatic or primary, the former being commoner. Metastatic tumour seedings in hernial sac is reported as 0.4% in one series⁽⁴⁾. It is recommended that grossly abnormal hernial sac be sent for frozen section and if there is

Fig 1 – Abdominal X-ray showing dilated loops of bowel with fluid levels and hernia in the middle.



malignancy, minilaparotomy or laparoscopic evaluation should be carried out via the hernial orifice on the table⁽²⁾. Grossly normal hernial sacs should be sent for microscopic examination.

A modified classification divides primary hernia sac tumour into saccular and intrasaccular types, the former referring to tumours of the hernial sac whilst the intrasaccular type refers to tumour of the viscera within the hernia⁽²⁾. Roslyn⁽²⁾ in 1980 collected 17 intrasaccular tumours, involving mainly the sigmoid colon, appendix or mesentery appearing in groin hernias. There was a report of transverse colonic carcinoma appearing within an incisional hernia⁽⁵⁾. Our case is the first reported case of intrahernial tumour in a paraumbilical hernia. Saccular tumours were mainly sarcomatous changes in the hernial sacs or spermatic cord.

Longstanding hernia that recently became incarcerated is a common feature in intrahernial tumours. This is attributed to the growth of the tumour preventing reduction of the hernia, adherence to the hernial sac or direct invasion of the hernial

Department of Surgery
Alexandra Hospital
Alexandra Road
Singapore 0314

M Y P Chan, MBBS, FRCS(Edin)
Registrar

B K Ng, MBBS, FRCS
Head and Senior Consultant

Correspondence to: Dr M Y P Chan

sac^(2,6). Barium examination should be considered before repair of these hernias⁽⁶⁾. In the absence of preoperative investigations it is important to examine the hernial contents carefully. If obstruction was present preoperatively, this condition must be kept in mind and recognised during operation. Presence of both dilated and nondilated loops of bowel in the hernia indicates that the obstruction is not at the level of the hernial neck but within the hernia, in our case, a tumour.

REFERENCES

1. Arnaud G. *Traite des hernies on descentes*, Vol 2. Paris: Le Mercier, 1749.
2. Roslyn J, Stabile B, Rangenath C. Cancer in inguinal and femoral hernias. *Am Surg* 1980; 46:358-62.
3. Brendel TH, Kirsh IE. Lack of association between inguinal hernia and carcinoma of the colon. *N Engl J Med* 1971; 284: 369-70.
4. Yoell JH. Surprises in hernia sacs. *Calif Med* 1959; 91:146.
5. Johnson WC. Colonic carcinoma in an incarcerated ventral hernia treated with preoperative progressive pneumoperitoneum. *Am Surg* 1973; 39:331-2.
6. Silbermann MD. Cecal carcinoma incarcerated in an inguinal hernia. *Int Surg* 1969; 51:515-9.