

# SEVERE AORTIC REGURGITATION DUE TO *NEISSERIA MUCOSA* ENDOCARDITIS

Y T Lim, M C L Lim, M H Choo, K Gamini

## ABSTRACT

*A rare occurrence of Neisseria mucosa endocarditis on a native aortic valve not known to be diseased is reported. Despite vigorous antibiotic therapy, severe aortic regurgitation developed necessitating aortic valve replacement. At operation, the right coronary cusp was retracted with two small nodules attached to its edge and the non-coronary cusp was perforated.*

*Neisseria mucosa endocarditis is very rare, and involves abnormal mitral or prosthetic valves predominantly. Infection of a native aortic valve, with no known history of disease, is exceptional.*

**Keywords:** *Neisseria mucosa, endocarditis, aortic regurgitation, valve*

SINGAPORE MED J 1994; Vol 35: 650-652

## INTRODUCTION

*Neisseriae*, other than *N. meningitidis* and *N. gonorrhoeae*, are normal inhabitants of the mucosa surfaces of the upper respiratory tract. Over the years, there have been occasional case reports of these organisms causing serious systemic infections<sup>(1)</sup>. The endocarditis in previous case reports occurred mainly on the mitral valves<sup>(2-4)</sup> or patients with prosthetic heart valve<sup>(5)</sup>. The reported cases were associated with Marfan's syndrome<sup>(3)</sup>, intravenous drug abuse<sup>(6,7)</sup> or with a history of prior dental procedures<sup>(2)</sup>. We report a case of *Neisseria mucosa* endocarditis of the aortic valve in a patient with no known history of valvular heart disease.

## CASE REPORT

A 35-year-old Chinese male who works as a welder was first admitted to our hospital for fever associated with chills and rigors for 5 days in September 1990. There was a preceding history of rhinitis and diarrhoea but these had resolved on the day of admission. There were no localising symptoms to suggest the source of infection. This was his first hospital admission and there was no significant past medical or surgical history of note. He denied any past history of rheumatic fever or valvular heart disease. He is not a drug user and there was no prior history of dental manipulation or surgical instrumentation. His temperature was 38°C on admission. There were no abnormal physical signs. The cardiovascular examination was normal. The blood pressure was 120/80 mmHg. His haemoglobin was 14 g/dl. The total white count was  $8.17 \times 10^9$  with 77% polymorphs. Erythrocyte sedimentation rate (ESR) was 84 mm/hr. The liver enzymes were mildly elevated, at 1.5–2 times normal. Urine microscopy was normal. He was treated with oral ampicillin 500 mg 6 hourly.

The fever settled gradually over the next few days and he was discharged well after 7 days. Preliminary report of two of the three blood culture specimens came back on the day of discharge. *Neisseria mucosa* was isolated. This was not given much attention as the patient's temperature had resolved and he was clinically well with no abnormal physical signs.

His fever recurred 3 days after discharge and he was readmitted 4 days later to our department complaining of fever and palpitations. Clinically he had a low grade temperature of 37.5°C. His pulse was collapsing and the blood pressure was 120/60 mmHg. There was no digital clubbing, splinter haemorrhages, Osler's nodes, Janeway lesions or Roth spots. The apex beat was undisplaced but there was a grade 3/6 early diastolic murmur best heard over the left sternal border on auscultation. The third heart sound was not present and he was not in cardiac failure. The haemoglobin had dropped to 11.9 g/dl and the total white count was then  $12.38 \times 10^9$  with 79.3% polymorphs. ESR was 87 mm/hr. Urine microscopy showed 6-8 leucocytes and 10-15 erythrocytes per high power field. His ECG was within normal limit. Chest X-ray showed a top normal heart size with no pulmonary congestion. Echocardiography showed a small vegetation on the right coronary cusp of the aortic valve (Fig 1) and the presence of moderate aortic regurgitation. The left ventricle was mildly dilated (60 mm) but the systolic function was good (end systolic diameter was 37 mm). *Neisseria mucosa* was isolated in 10 of the 12 blood culture specimens sent. The isolates were sensitive to penicillin, ampicillin, cephalexin, gentamicin, tetracycline, bactrim and erythromycin. The portal of entry for the organisms was believed to be the oral cavity as he had poor dental hygiene. He was started on intravenous crystalline penicillin of up to 24 mega units per day for 6 weeks and gentamicin 60 mg 8 hourly for a total of about 4 weeks. Both the Minimum Inhibitory Concentration (MIC) and Minimum Bactericidal Concentration (MBC) for penicillin was 0.5 mg/L and the serum bactericidal level was 1:40. He was also treated by a dental surgeon. The endocarditis was uncomplicated. Repeat blood cultures both during and after the antibiotics therapy were negative. He was discharged 2 days after completion of the antibiotic treatment.

He remained afebrile and well after discharge. His effort tolerance was initially NYHA I but gradually deteriorated after about 6 months. Repeat echocardiography showed that the left ventricle end diastolic diameter had dilated to 70 mm and the end systolic diameter was 51 mm and that the aortic regurgitant jet had become severe, both by colour flow mapping and pressure half-time measurement ( $P_{1/2}$  time was 206 msec, Fig 2). He had surgical replacement of his aortic valve in March 1992 with a

---

Cardiac Department  
National University Hospital  
Lower Kent Ridge Road  
Singapore 0511

Y T Lim, MRCP(UK), MMed (Int Med)  
Consultant

M C L Lim, MRCP(UK), MMed (Int Med)  
Senior Registrar

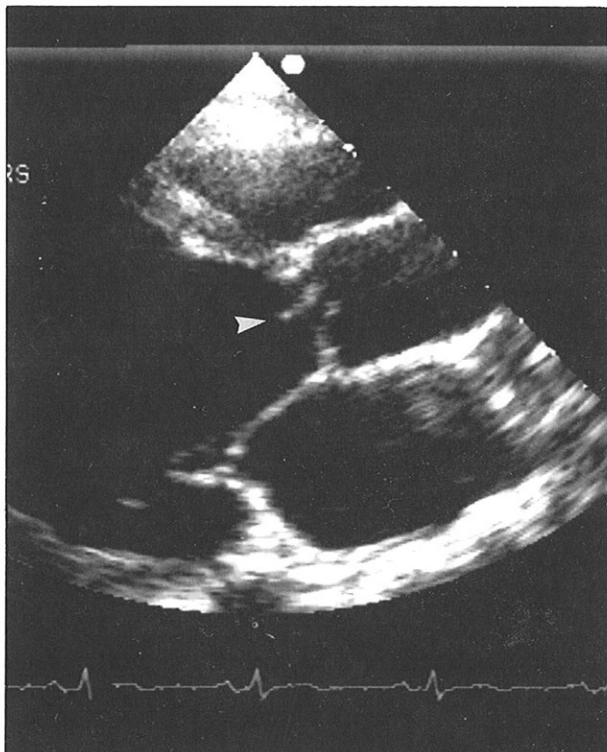
M H Choo, FRCP(Edin), MD  
Professor and Chief

Gamini K, DPath (UK), MRC Path (UK)  
Consultant

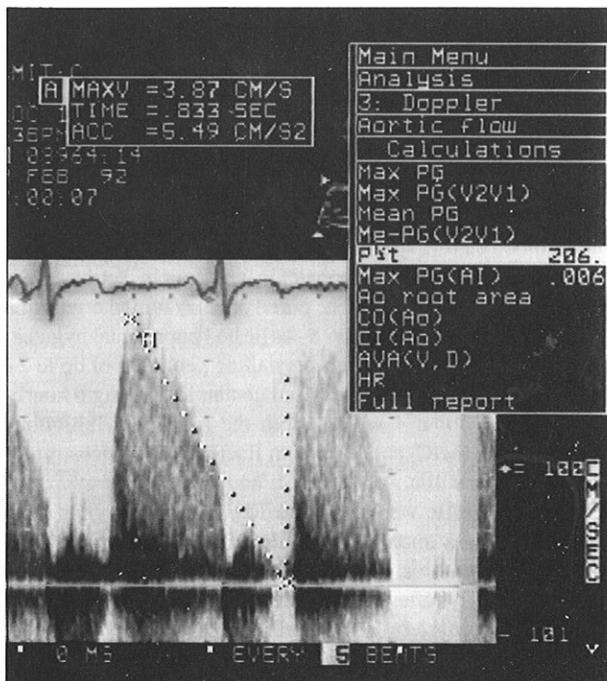
Correspondence to: Dr Y T Lim

---

**Fig 1 – Parasternal long axis view of the heart showing a vegetation on the right coronary cusp of the aortic valve (arrow head).**

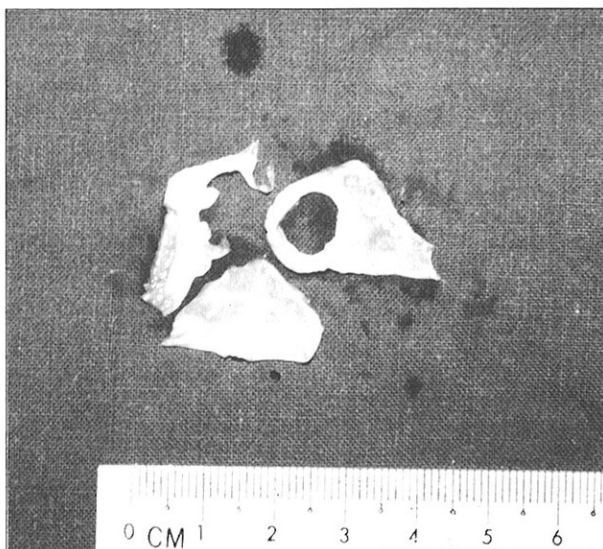


**Fig 2 – Doppler tracing of the aortic regurgitant jet using apical five chamber view. The deceleration slope of the jet envelop was steep and the calculated pressure half-time was 206 msec.**



prosthetic mechanical Carbomedic valve. During surgery, the trileaflet aortic valve was noted to have a normal left coronary cusp but the right coronary cusp was retracted with two small nodules attached to its edge. There was a large perforation in the centre of the non-coronary aortic cusp (Fig 3). Post-operatively,

**Fig 3 – This is a picture of the dissected aortic valve. The right coronary cusp was retracted and had 2 nodules attached to its edge. The non-coronary cusp had a perforation in the centre. The left coronary cusp (placed at the bottom in this picture) was normal in appearance.**



he was only on warfarin. His functional status has returned to NYHA I. A 2-dimensional echocardiogram performed one year later showed that the left ventricular function and dimensions have returned to normal.

## DISCUSSION

*Neisseria mucosa* is a normal inhabitant of the nasopharynx. In the past, it has often been regarded as non-pathogenic. However, like the other “normal flora” of the upper respiratory tract, it may act as an opportunistic pathogen. The number of confirmed *Neisseria mucosa* infections are few. Previous reports have linked it to serious infections eg meningitis, pneumonia and endocarditis<sup>(1)</sup>. A search through the literature showed that there were only 8 cases of cardiac involvement reported so far<sup>(2,4-10)</sup>. Most of the reported cases were associated with abnormal mitral valve or implanted prosthetic valves. They also occurred in the setting of intravenous drug usage or had a prior history of dental manipulations. To the best of our knowledge, de novo infection of the native aortic valve in a patient with no known prior valvular heart diseases has not been previously reported.

It is possible that our patient's aortic valve may not be normal despite the absence of history. However, his absence of symptoms prior to the infection, normal cardiovascular examination documented during the first admission to the hospital and the normal baseline cardiovascular investigation exclude the presence of any significant valvular disorder.

The portal of entry for infection is likely to be the oral cavity as a result of poor dental hygiene. The diagnosis of endocarditis was made by the combination of clinical findings, echocardiographic evidence of vegetation on the aortic cusps and positive blood culture in 10 out of the 12 specimens sent. The identification of the isolates as *Neisseria mucosa* was based on the growth of gram-negative, oxidase positive, catalase positive *diplococci* that produce pale yellow mucoid colonies on blood and chocolate agar plates. The differential use of carbohydrates formed the basis of the final identification.

The significance of a positive blood culture for nongonococcal and nonmeningococcal *Neisseria* has been studied previously by Feder et al<sup>(11)</sup>. Over a 10-year period, they

found only eight patients with *Neisseria* isolated from the blood. Four were associated with serious infections. Hence, when *N. mucosa* is isolated from blood culture, one should evaluate the patient carefully instead of regarding the finding as possible 'contamination by normal flora' in the correct clinical setting (as exemplified by our patient on his initial presentation).

What constitutes the most appropriate treatment for *N. mucosa* infection remains unclear. While most cases have been treated with the penicillin group of antibiotics, some have treated patients with aminoglycosides, vancomycin or cephalosporins<sup>(6)</sup>. The MIC and MBC for penicillin in our isolate was reported to be 0.5 mg/L. However, many strains of *N. mucosa* have been reported to be less susceptible<sup>(3)</sup>. Thus, although penicillin is frequently used, the susceptibility of every isolate of *Neisseria mucosa* to penicillin should be measured during the treatment period. Our patient's serum bactericidal titres (SBT) of 1:40 indicated that our dosage of penicillin was adequate. Gentamicin was used during the first month of treatment and care was taken to measure the serum level and monitor the renal function during the period of therapy.

*Neisseria mucosa* infection of the aortic valve in our patient led not only to cuspal damage, but also perforation of the non-coronary cusp. Our patient's cardiovascular assessment was normal on the first admission. Hence, the aortic regurgitation that was detected when he was readmitted must be of acute onset. He did not decompensate or develop any symptoms or signs of congestive cardiac failure which would be expected if the acute aortic regurgitation was severe. However, over the subsequent

months of follow-up, the aortic regurgitation progressively worsened. He developed symptoms and left ventricular dilatation and eventually underwent aortic valve replacement. A previous case report had also described myocardial abscess as a complication of *Neisseria mucosa* infection<sup>(9)</sup>. Hence, this commensal organism of the respiratory tract may cause potentially serious cardiac complications.

#### REFERENCES

1. Herbert DA, Ruskin J. Are the "nonpathogenic" *Neisseriae* pathogenic? *Am J Clin Pathol* 1981; 75:739-42.
2. Weinstein AJ, McHenry MC. Bacterial endocarditis in a patient with mitral valve prolapse. *Arch Intern Med* 1979; 139:1191-2.
3. Dowling JN, Lee WS, Sacco RJ, Monto HO. Endocarditis caused by *Neisseria mucosa* in Marfan's syndrome. *Ann Intern Med* 1974; 81:641-3.
4. Brodie E, Adler JL, Daly AK. Bacterial endocarditis due to an unusual species of encapsulated *Neisseria*. *Am J Dis Child* 1971; 122:433-7.
5. Hennessey BS, Reinhart JH, McGurkin MB. Endocarditis caused by *Neisseria mucosa* in a patient with a prosthetic heart valve. *Am J Med Technol* 1981; 47:909-11.
6. Davis CL, Towns M, Henrich WL, Melby K. *Neisseria mucosus* endocarditis following drug abuse. *Arch Intern Med* 1983; 143:583-5.
7. Giles MW, Andrew JH, Tellus MM. A case of polymicrobial infective endocarditis involving *Neisseria mucosa* occurring in an intravenous drug abuser. *Aust NZ J Med* 1988; 18:874-6.
8. Fernandez-Guerrero ML, Barros C, Rodriguez-Tudela JL, Villacastin J, Gomez Graces JL. Endocarditis due to *Neisseria mucosa* complicated by myocardial abscess. *J Infect* 1989; 18: 294-5.
9. Matsuda S, Nakamura I, Yoshinaka H. [A case of bacterial endocarditis due to *Neisseria mucosa*]. *Kunsenshogaku-Zassho* 1978; 52:87-91.
10. Coeurderoy A, Avril JL, Abdre P, Cartier F. Prosthetic valve endocarditis due to *Neisseria mucosa*. *J Infect* 1986; 12:87-8.
11. Feder HM Jr, Garibaldi RA. The significance of nongonococcal, nonmeningococcal *Neisseria* isolates from blood cultures. *Rev Infect Dis* 1984; 6:181-8.