

THE ANATOMY OF THE BASAL GANGLIA AND PARKINSON'S DISEASE: A REVIEW

T K Y Lee, R Chau, S K Leong

ABSTRACT

The present understanding of the anatomy of the basal ganglia has been updated. Recent work has produced a primate model of Parkinson's disease for study of its pathogenesis and treatment. In the last two decades, administration of dopamine agonist has been the mainstay of treatment of Parkinson's disease in the humans. However, recent use of dopamine-rich tissue such as adrenal gland or human foetal cells is opening up a new frontier for the treatment of more severe Parkinsonism. Nevertheless, there is still much to be learned at the basic neuroscience level before such procedure could be used widely in clinical practice.

Keywords: basal ganglia, anatomy, Parkinson's disease, transplantation

SINGAPORE MED J 1995; Vol 36: 74-76

INTRODUCTION

"The Royal road of the sensations of the body to the soul is through the corpora striata and all determinations of the will also descend by that road." – Swedenborg, "Oeconomia Regni Animalis", 1740⁽¹⁾.

Though clinicians have learned the anatomy of the basal ganglia during their student days, they still find the term nebulous as it has been used by different authors to include different structures. A simplified concept of the term basal ganglia is shown in Fig 1. The following features should be noted:

1. Neostriatum or simply, striatum: putamen and caudate nucleus

The putamen and caudate nuclei display similar histological features and fibre connections. They are both highly cellular and well-vascularised with finely-myelinated or non-myelinated fibres. The striatum is so called because strands of gray matter connecting the putamen to the head of the caudate nucleus transverse the anterior limb of the internal capsule, giving it a striped appearance.

2. Paleostriatum or simply, pallidum or globus pallidus. This is so called because it appears rather pale in fresh section due to the presence of large well myelinated fibres.
3. Lentiform nucleus: globus pallidus and putamen.
4. Substantia nigra in the midbrain and the thalamus form

Department of Surgery
National University Hospital
Lower Kent Ridge Road
Singapore 0511

T K Y Lee, MBBS, FRCS(Edin), FRCS(Surgical Neurol), FAMS
Consultant Neurosurgeon and Senior Lecturer

Department of Anatomy
University of Hong Kong

R Chau, B Sc, PhD
Lecturer

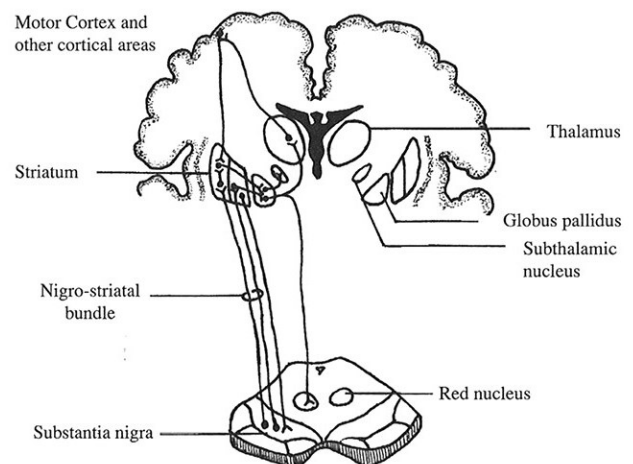
Department of Anatomy
National University of Singapore
Kent Ridge Crescent
Singapore 0511

S K Leong, BDS, PhD
Acting Head

Correspondence to: Dr T K Y Lee

important connections with the basal ganglia. Amygdaloid body is best considered as part of the limbic system⁽²⁾. Claustrum is regarded by some as part of the insular cortex, although some would consider it as part of the basal ganglia.

Fig 1 – Diagrammatic representation of the principal connections of basal ganglia



The understanding of the anatomy of the basal ganglia has undergone much changes over the last two decades. Before the 1970s, it was regarded as the main structure in the extrapyramidal pathway because it was thought to form polysynaptic relays onto the final common pathway as the pyramidal system, that is, the anterior horn cell in the spinal cord and motor nuclei in the brain stem⁽³⁾.

With the use of the Golgi technique, electron microscopy and new tracing methods in the 1970s, the connections of the basal ganglia were studied and such has given rise to important concepts about the function of these neuronal groups. In describing the connections of the basal ganglia, it is important to remember that the striatum is the recipient zone and the pallidum the efferent zone.

Afferent pathways to the striatum are predominantly from the cerebral cortex, thalamus and most importantly, the substantia nigra:

(a) Cortico-striate fibres

The fibres are topically organised and converge from all parts of the cerebral cortex via the internal capsule. Some enter the putamen across the external capsule.

(b) Thalamostriate fibre

The main input from the thalamus to the striatum is the intralaminar nuclei, especially the centromedian nucleus (one of the intralaminar group).

(c) Nigrostriate fibre

Although there was at one time some doubt about the existence of a nigrostriatal connection, recent neuroanatomical techniques have firmly established its existence. This connection has also assumed great importance in an understanding of the pathology of Parkinson's disease. The fibres originate mainly from the pars compacta of the substantia nigra and end largely in the caudate nucleus and putamen and to a much smaller extent, the globus pallidus. By causing a lesion in the substantia nigra (for example, by injecting the neurotoxin 6-hydroxydopamine) in experimental animals, one can produce degeneration of the nigrostriatal neurones resulting in the development of functional deficits similar to Parkinson's disease.

Another neurotoxin, 1-methyl-4-phenyl-1,2,3,6-tetrahydropyridine (MPTP), when given intravenously or intraperitoneally to primates, produces almost identical pathological features as the human counterpart. By sequential intracarotid injection of MPTP, we have successfully produced a bilateral Parkinsonian model with little systemic toxic effect^(4,5).

As stated earlier, the striatum sends its efferents to the globus pallidus. In addition, there are also a few fibres projecting to the thalamus and substantia nigra. Afferent pathway to the pallidus originates mainly in the striatum although a few fibres from the thalamus also enter it through the subthalamic fasciculus.

Efferent fibres from the pallidus are thick and well myelinated. They form a complex system of pathways which diverge to a number of destinations as shown below:

- (1) thalamus (esp. nucleus ventralis anterior and vastralis intermedius via both the fasciculus lenticularis and ansa lenticularis)
- (2) subthalamic nucleus
- (3) substantia nigra
- (4) red nucleus
- (5) midbrain reticular formation
- (6) inferior olivary nucleus

In the 1970s, the striatum was viewed as serving to integrate inputs from widespread cortical areas and then to funnel this output via the globus pallidus back to the motor cortex. Though this is largely correct, recent findings in non-human primates however show that inputs from different areas in fact remain anatomically and functionally segregated throughout the basal ganglion-thalamocortical circuitry and 5 such distinct circuits have been identified ie (1) motor, (2) oculomotor, (3) dorsolateral prefrontal, (4) orbitofrontal, and (5) anterior cingulate circuits⁽⁶⁾.

PARKINSON'S DISEASE

The clinical condition was first described by James Parkinson from Queen Square, London who reported the triad of akinesia, rigidity and rest tremor in 1817⁽⁷⁾. The pathology has been well studied. There is extensive loss of the dopaminergic cell body in the substantia nigra (in particular, the zone compacta) and dopaminergic fibres in the striatum. The aetiology has remained obscure but the recent chance discovery of a neurotoxin MPTP has raised the possibility of chronic toxication. In the early 1980s a synthetic drug, 1-methyl-4-phenyl-4-propionoxy-piperidine (MPPP), was not listed as a controlled drug in the United States and some chemists made it up to sell to drug addicts. Because of the lack of stringent purification procedures, a contaminant

MPTP was produced and this caused severe Parkinsonian features in young addicts. The first clinician who observed this wrote a case report which was rejected by major journals. He finally managed to publish it in a new journal⁽⁸⁾. Four years later, doctors in another hospital found a series of young Parkinsonian patients, all of whom were drug addicts. Subsequent epidemiological studies traced them to the same chemist and this led to the discovery of MPTP⁽⁹⁾ in 1983. MPTP, when given to monkey, also causes Parkinsonism features and destruction of dopaminergic neurones in the substantia nigra and the striatum.

The treatment of Parkinson's disease has undergone much changes over the last few decades. Stereotactic surgery was used before 1967 to treat the rest tremor⁽¹⁰⁾. With the discovery of L-dopa (L-dihydroxyphenylalanine, a precursor of dopamine), dopaminergic agonist, together with a peripheral decarboxylator to minimise side effects outside the central nervous system, became the mainstay of therapy. While mild and moderate cases can often be controlled medically, some patients do progress. In severe cases, the dosage of L-dopa often needs to be stepped up progressively until the side effects produced become intolerable. Many such patients experienced the "on-off" phenomenon, alternating between freezing up and hyperkinetic phases.

Recently, transplants of dopamine-rich tissues into the striatum has stirred up much excitement and interest. The proclamation of dramatic improvement in two severe Parkinsonian patients by a Mexican neurosurgeon, using autologous adrenal transplant, was published in the New England Journal of Medicine in 1987⁽¹¹⁾. Subsequently a number of American neurosurgeons learnt the technique and tried it on their patients. The result was disappointing with minimal improvement and significant morbidity and some mortality. Post-mortem of some patients who died after the procedure revealed little living adrenal tissues⁽¹²⁾. This procedure has now been largely abandoned.

Since 1980, a Swedish group has concentrated on experiments of transplantation of foetal cell from the ventral mesencephalon, which develops into the substantia nigra normally. They started with rodents to determine the amount of foetal tissues, the optimal site of injection as well as the best protocol for handling the foetal cells. In rodents and subsequently in monkeys, they demonstrated improvement of the animal histologically, biochemically and behaviourally. Based on the encouraging results in animals, foetal cell transplants were carried out in two patients. They subsequently published in Science reporting that in one of the 2 patients there was increased dopamine metabolism on the transplanted side, using Positron Emission Transmission Scanner. This was paralleled with clinical improvement⁽¹³⁾.

While neurotransplantation is an exciting area, the use of foetal material poses some ethical dilemma, and was discouraged in the United States for such may encourage more abortions. Also, because of the experience in the 1940s and 1950s when humans were used as experimental subjects without adequate animal studies, stringent ethical committee review became necessary so that novel treatment modality has to go through proper trial procedures. Therefore, human foetal transplants should probably be limited to several large centres only where clinical and experimental trials are being carried out until the ideal transplant protocol, data on long term success and risks have become available. One such trial is going on in Birmingham, UK and has involved more than 36 patients and early results are encouraging (personal communication).

Besides the clinical questions such as the best sites for transplant and the optimal age of foetus, there are also many basic neuroscience issues unresolved at the moment. The need

for immunosuppressant is uncertain because the brain has long been regarded as an immunologically privileged organ. Should this be necessary, immunosuppression would incur significant risk in elderly Parkinsonian patients. While it was used routinely by the Swedish group, immunosuppression was not used at all in the Birmingham study. The mechanism of how foetal cell transplant brings about the improvement is uncertain. They may do so by: (1) forming new connections with the host neurones, (2) secreting neurotrophic factors which cause sprouting of remnant fibres or regeneration of degenerating fibres, or (3) secreting dopamine, which would replenish the depleted striatum. There is some evidence that neurotrophic factor may play an important role because in a primate study, unilateral placement of graft caused regeneration bilaterally⁽¹⁴⁾. It is therefore possible that the use of genetically engineered cell lines secreting dopamine or neurotrophic factors would obviate the need for foetal material. But without basic neuroscience research, such will still be a far cry.

REFERENCES

1. Reid MS. Neuropharmacological circuitry of the basal ganglia studied by in vivo microdialysis. Stockholm, Sweden: Kongl Carolinska 1990.
2. William PL, Warwick R, Dyson M, Bannista LH. Neurology: Basal nuclei. In: Gray's Anatomy. 37th ed. Edinburgh: Churchill Livingstone 1989:1073-5.
3. Johnston TB, Whills J. Neurology: The brain or encephalon. In: Gray's Anatomy, descriptive and applied. 13th ed. London: Longmans, Green and Co. 1949:1030.
4. Lee T, Leong SK, Rauff A, Yue D, Po L, Wong P, et al. A bilateral Parkinson model in non-human primates by sequential intracarotid MPTP injection. Presented at the 4th International Symposium of Neural Transplantation, Washington DC 13th-16th July 1992.
5. Lee T, Leong SK, Rauff A, Yue D, Po L, Wong P, et al. A bilateral Parkinson model in non-human primates by sequential intracarotid MPTP injection. *J Restorative Neuro Neurosci* 1992; 4:170.
6. Delong MR, Alexandra GE, Miller WC, Crutcher MD. Anatomical and functional aspects of basal ganglia – thalamocortical circuits. In: Franks AJ, Ironside JW, Mindham RHS, Smith RJ, Spokes EGS, Winton W. eds. *Function and dysfunction in the basal ganglia*. Manchester: Manchester University Press, 1990:3-32.
7. Parkinson J. An essay on the shaking palsy. London: Whittingham and Rowland, 1817.
8. Davis GC, Williams AC, Markey SP, Ebert MH, Caine ED, Reichert CM, et al. Chronic Parkinsonism secondary to intravenous injection of meperidine analogues. *Psychiatry Res* 1979; 1:249-54.
9. Langston JW, Ballard PA, Tetrud JW, Irwin I. Chronic Parkinsonism in humans due to a product of meperidine-analog synthesis. *Science* 1983; 219:979-80.
10. Cooper IS. Surgical treatment of Parkinsonism. *Ann Rev Med* 1965; 16:309-30.
11. Madrazo I, Drucker-Colin, R, Piaz V, Martinez-Mata J, Torres C, Becerril JJ. Open microsurgical autograft of adrenal medulla to the right caudate nucleus in two patients with intractable Parkinson's disease. *N Engl J Med* 1987; 316:813-4.
12. Hurtig H, Joyce J, Sladele JR, Trojanowski JQ. Postmortem analysis of adrenal-medulla-to-caudate autograft in a patient with Parkinson's disease. *Ann Neurol* 1989; 25:607-14.
13. Lindvall O, Brundin P, Widner H, Rehncrona S, Gustavii B, Frackowiak R, et al. Grafts of fetal dopamine neurons survive and improve motor function in Parkinson's disease. *Science* 1990; 247:574-7.
14. Bankiewicz KS, Plunkett RJ, Jacobowitz DM. The effect of fetal mesencephalon implants on primate MPTP-induced Parkinsonism. *J Neurosurg* 1990; 72:231-44.