

CLUSTERED INTRAMAMMARY MICROCALCIFICATIONS NOT ASSOCIATED WITH A MASS

C M E Fok, V B Reynolds, K A L Tan, C L Ong, P Y A Chong

ABSTRACT

Over a period of two and a half years, 36 biopsies performed for clustered microcalcifications not associated with a mass revealed 30 benign and 6 malignant lesions. Of the 30 benign cases, 4 showed histological features which are thought to be associated with an increased risk of developing carcinoma.

As similarities can exist in the mammographic appearances between benign and malignant microcalcifications, clusters of microcalcifications showing overlapping features or increasing in number over time require histopathologic study as there is no radiologic means at present of predicting which cluster will be malignant.

We observe that our Chinese female population has a tendency towards dense breast parenchyma often associated with microcalcifications, both scattered and clustered. The presence of these clustered microcalcifications prompts biopsy even though the yield for malignancy is anticipated to be low.

Keywords: clustered intramammary microcalcifications, breast carcinoma

SINGAPORE MED J 1995; Vol 36: 29-31

INTRODUCTION

Mammography to date is still the most reliable imaging modality for detection of breast cancer in its early stages. Early diagnosis depends on detecting a mass, abnormal density, architectural distortion or microcalcifications on the mammograms. The presence of microcalcifications alone, particularly if clustered, is an acceptable indication for biopsy. However, owing to the overlap in features between benign and malignant microcalcifications, it can be anticipated that the positive yield for malignancy would be low in comparison to the number of biopsies performed. Figures ranging from 17.6% to 35.5% for positive biopsies have been reported in the literature⁽¹⁻⁴⁾.

We reviewed a series of patients who had biopsies performed for clustered microcalcifications to determine the yield in our institution.

METHOD

Over the period January 1990 to June 1992, a total of 55 mammographically guided biopsies were performed. All of the

patients had pre-operative mammograms. Those in which radiologic signs other than microcalcifications were present were excluded from the study. Those in which microcalcifications were associated with a mass were also not included. In patients in whom mammograms were performed at another institution, the radiographs were obtained for review. In 7 patients, we had to rely only on the mammogram reports as the radiographs were not available.

The patients were admitted a day before the biopsy. Mammographic localisation was carried out the following morning and a hooked wire was inserted as close to the cluster of microcalcifications as possible. The patient was then transferred to the operating theatre for open biopsy under general anaesthesia.

There were two methods of performing the biopsy. The first involved removing a core of breast tissue around the needle track from the skin entry point to the end of the needle. The second method depended on localising the tip of the needle. An incision was then made over this and only the breast tissue around the tip of the needle was excised.

With either method, the tissue excised together with the needle was radiographed to confirm the presence of the microcalcifications within the specimen. This was then sent to the histopathologist.

RESULT

Out of 55 biopsies, 19 cases were eliminated, leaving 36 patients with clustered microcalcifications not associated with a mass. In addition to the clustered microcalcifications, 21 of the 36 patients had varying number of scattered microcalcifications in one or both breasts. Eight had no other microcalcifications present and this information was not available in 7 patients.

The age range was 29 to 63 years with 50% falling between 41 and 50 years. All but one were Chinese. Thirty-four (94%) had dense or predominantly glandular breast tissue, 2 had predominantly fatty breast tissue.

Thirty (83.3%) of the biopsies proved to be benign. Of these, 4 showed histologic features which are thought to be associated with an increased risk of developing carcinoma; 2 showed atypical ductal hyperplasia, one had atypical lobular hyperplasia and one had papillomatosis.

Six (16.7%) of the biopsies showed malignancy. Of these, 3

Department of Diagnostic Imaging
National University Hospital
Lower Kent Ridge Road
Singapore 0511

C M E Fok, MBBS, FRCR (UK)
Registrar

V B Reynolds, MD
Senior Registrar

K A L Tan, MBBS, FRCR, FRACR (Hon)
Professor and Head

Department of Surgery
National University Hospital

C L Ong, MBBS, M Med (Surg), FRCS
Lecturer

Department of Pathology
National University Hospital

P Y A Chong, MBBS, FRCPath
Consultant

Correspondence to: Dr C M E Fok

were ductal carcinomas, 2 were intraductal carcinomas and one was lobular carcinoma with an in-situ component. None of the axillary lymph nodes removed during definitive surgery showed involvement by tumour. These patients were between the ages of 45-50 years, with the youngest aged 37 years.

Eight of the biopsies were performed because of an increase in the number of microcalcifications or because of the appearance of a new cluster of microcalcifications. Of these, one was malignant, 2 showed cellular atypia and the rest were benign.

DISCUSSION

The association of calcification with breast cancer was recognised more than 40 years ago by Leborgne⁽⁵⁾. Calcification in breast carcinoma can occur in up to 40% of cases.

Two types of microcalcifications are described in the literature^(6,7). Type I microcalcifications, composed of calcium oxalate, are seen largely in benign breast diseases and are actively secreted by the ductal epithelium or acinar cells. These are occasionally associated with malignancy. Type II microcalcifications, composed of calcium phosphate crystals, primarily hydroxyapatite, can be present in both benign and malignant conditions and occur as a result of mineralisation of cellular debris. Type I and II calcifications have no observable distinguishing mammographic features.

There are established radiologic features for microcalcifications which are characteristically benign, requiring no further evaluation, and those which show mammographic features strongly suggestive of malignancy⁽⁸⁾.

One form of characteristically benign calcification is that of milk of calcium. This appears as a semilunar, curvilinear or linear fluid-calcium level on mammograms taken with a horizontal beam. Calcifications with lucent centres are also benign and if multiple are usually scattered throughout both breasts. They generally vary in size from 1 to 4 mm. Calcifications associated with duct ectasia are typically linear, oval or round and are usually larger in length and calibre than those associated with malignancy. They are often oriented with the long axis pointing toward the nipple. Calcifications associated with a fibroadenoma are large, irregular and bizarre in appearance and demonstrate a characteristic "popcorn" appearance.

Malignant calcifications often vary in size (some being less than 0.5 mm), and shapes. The shapes can take the form of pointed, branching, delicate linear deposits less than 0.5 mm, or they can be comma-shaped, have a dot-dash configuration or a combination of forms. A cluster of microcalcifications, arbitrarily taken as 5 or more microcalcifications equal or less than 0.5 mm within a 1 cm³ volume occurring as an isolated feature or in association with a mass, is a sensitive but non-specific sign of malignancy.

The problem arises when calcifications seen on the mammogram have overlapping features. Calcification that occurs is thought to be a reflection of the varied physiology of disturbed epithelial cells which may or may not progress through hyperplasia to in-situ carcinoma and then invasive carcinoma⁽²⁾. It is therefore not unexpected that calcifications in benign and malignant diseases can have similar appearances (Figs 1-4). It is also not surprising that an increase in the number of microcalcifications with time does not necessarily indicate malignancy although there is an increased likelihood of carcinoma⁽⁹⁻¹¹⁾. In our series, 8 patients were biopsied for increasing number or a new cluster of microcalcifications; 5 were benign, one malignant and 2 had cellular atypia.

The risk in atypical ductal or lobular hyperplasia of developing subsequent carcinoma is said to be four times that of the general population. Women with a family history of

Fig 1 – A cluster of several microcalcifications of indeterminate appearance. Histology was that of intraductal carcinoma.

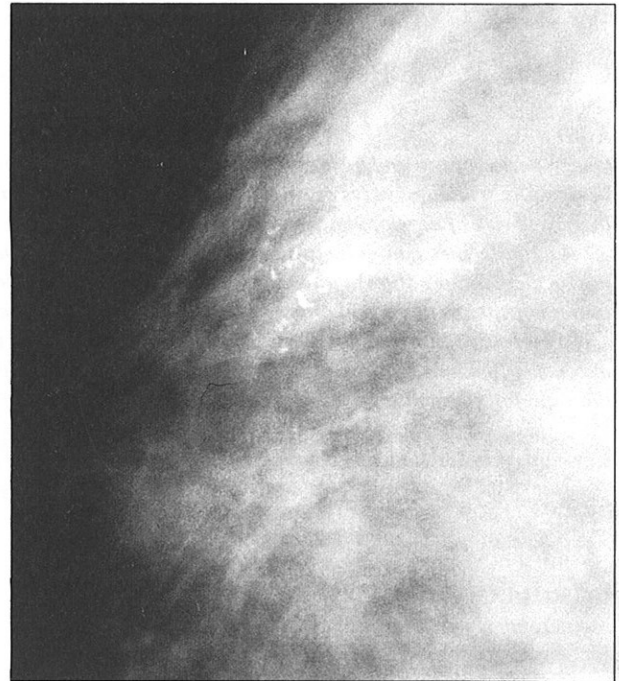
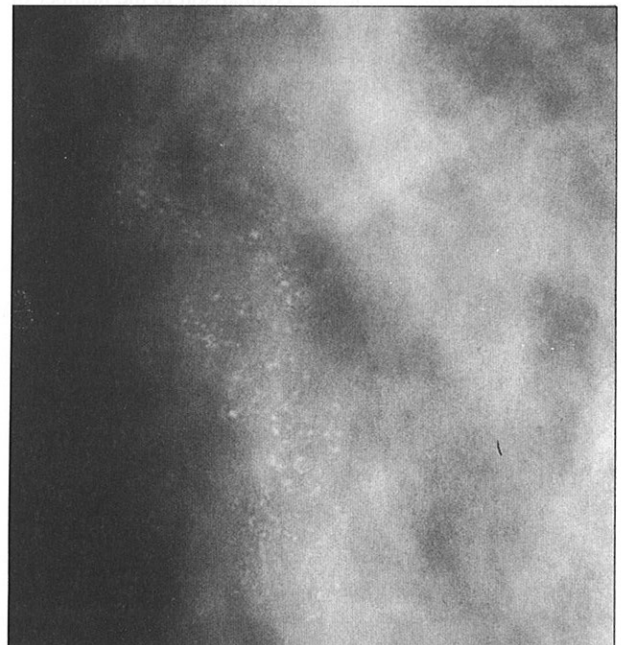


Fig 2 – A large cluster of microcalcifications composed of particles of various morphologies and densities. Histology showed atypical hyperplasia.



carcinoma in a first degree relative as well as atypical lobular hyperplasia on biopsy double their risk of subsequent invasive carcinoma over that of atypical lobular hyperplasia alone⁽¹²⁾.

Papillomatosis (ie multiple papillomas as opposed to a solitary papilloma) is frequently associated with epithelial proliferative disease which often has atypical features approaching that of carcinoma in-situ. Haagensen et al (1981)

Fig 3 – The microcalcifications in this cluster showed different shapes, sizes and densities which prompted biopsy. Histopathology was that of fibrocystic change.

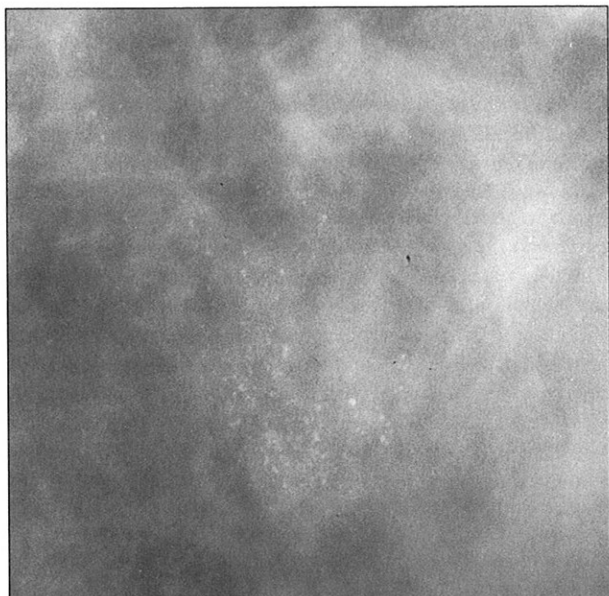
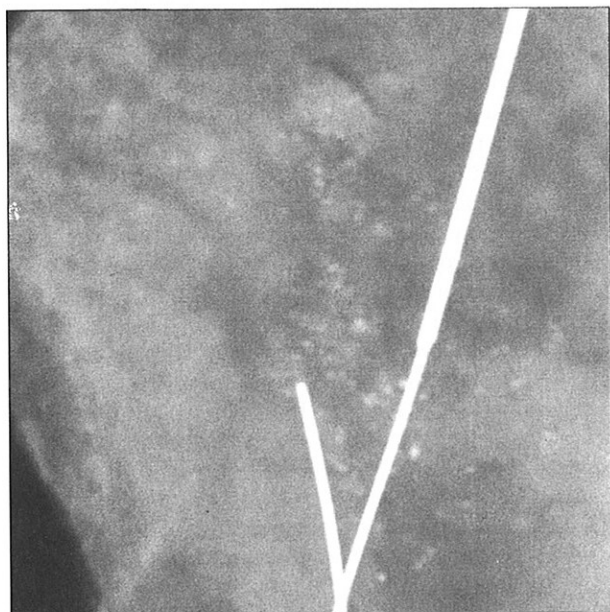


Fig 4 – Fibrocystic change; excised specimen after hook wire localisation showing a cluster of nondescript microcalcifications.



suggested that this helped to explain the increased risk of developing subsequent carcinoma in a group of patients with papillomatosis followed over a period of 19 years⁽¹²⁾.

Martin in 1988 stated that breasts with homogenous densities in those greater than 40 years for some reason had adenosis as the histologically dominant lesion and frequently had scattered and/or clustered microcalcifications⁽¹³⁾. In itself dense parenchymal pattern has not been proven to be an indicator of malignancy. Rather, it is the presence of associated microcalcifications that raises the suspicion of possible malignancy. As there is still no radiological means at present of determining which of the microcalcifications showing overlapping features are malignant, the presence of such microcalcifications will prompt biopsy even though the number of positive cases will be low in relation to the number of biopsies performed. Figures in the literature range from 17.6% to 35.5%.

16.7% of the patients in our series had carcinoma. Our observation that the local Chinese female population frequently has dense breast parenchyma often associated with both scattered and clustered microcalcifications may be a contributing factor to the lower positive yield.

REFERENCES

1. Murphy WA, DeSchrver-Kecskemeti K. Isolated clustered microcalcifications in the breast. Radiologic-pathologic correlation. Radiology 1978; 127: 335-41.
2. Egan RL, McSweeney MB, Sewell CW. Intramammary calcifications without an associated mass in benign and malignant diseases. Radiology 1980; 137: 1-7.
3. D'Orsi CJ, Reale FR, Davis MA, Brown VJ. Breast specimen microcalcifications: Radiographic validation and pathologic-radiologic correlation. Radiology 1991; 190: 397-401.
4. Homer MJ. Breast imaging: pitfalls, controversies and some practical thoughts. Radiol Clin North Am 1985; 23: 459-72.
5. Leborgne R. Diagnosis of tumours of the breast by simple roentgenography. Am J Roentgen 1951; 65: 1-11.
6. Suratt JT, Monsees BS, Mazoujian G. Calcium oxalate microcalcifications in the breast. Radiology 1991; 181: 141-2.
7. Fandos-Moreva A, Prats-Esteve M, Tura-Soteras JM, Traveria-Cros A. Breast tumours: composition of microcalcifications. Radiology 1988; 169: 325-7.
8. Sickles EA. Breast calcifications: mammographic evaluation. Radiology 1986; 160: 289-93.
9. Millis RR, Davis R, Stacey AJ. The detection and significance of calcifications in the breast: a radiological and pathological study. Br J Radiol 1976; 49: 12-26.
10. Moskowitz M. Screening is not diagnosis. Radiology 1979; 133: 265-8.
11. Colbassani HJ Jr, Feller WF, Cigtay OS, Chun B. Mammographic and pathologic correlation of microcalcification in disease of the breast. Surg Gynaecol Obstet 1982; 155: 689-96.
12. Page DL, Anderson TJ. Epithelial hyperplasia. Papilloma and related diseases. In: Page DL, Anderson TJ, Lowell WR. eds. Diagnostic Histopathology of the breast. Great Britain: Churchill Livingstone 1988; 156: 113-5.
13. Martin JE. Benign diseases of the breast. In: Harris JH Jr. ed. Atlas of mammography, histologic and mammographic correlation. 2nd ed. United States of America: William and Wilkins 1988: 304-5.