

# THE AETIOLOGY OF POSTMENOPAUSAL BLEEDING – A STUDY OF 163 CONSECUTIVE CASES IN SINGAPORE

W H Lee, K H Tan, Y W Lee

## ABSTRACT

**Objective:** To study the aetiology and pattern of Postmenopausal Bleeding (PMB) in the local population.

**Design:** A retrospective study

**Subjects:** 163 consecutive patients who presented with postmenopausal bleeding (PMB)

**Setting:** Kangang Kerbau Hospital, Singapore

**Results:** Malignant causes were found in 42 (25.7%) patients. Cervical carcinoma was the most common malignancy (12.9% of the patients) followed by endometrial carcinoma (11%). Important benign causes are cervicitis (12.9%), atrophic vaginitis (12.3%) and cervical polyp (6.7%). Other benign causes include endometrial hyperplasia (3.1%), urethral caruncle (2.5%) and estrogen replacement therapy (1.8%).

**Conclusion:** PMB is a symptom of varied aetiologies. The associated incidence of malignancy is high and a thorough diagnostic evaluation is mandatory.

**Keywords:** postmenopausal bleeding, cervical carcinoma, endometrial carcinoma, atrophic vaginitis, malignancy

SINGAPORE MED J 1995; Vol 36: 164-168

## INTRODUCTION

Abnormal vaginal bleeding is one of the most common presenting complaints encountered in a gynaecological clinic. Amongst them, postmenopausal bleeding ranks as the most sinister as it is often associated with malignancy. The rate of malignancy, however, varied greatly in different investigations, ranging from 5.4% to 76%<sup>(1)</sup>.

With an ageing population and an increase in life expectancy in Singapore, a larger proportion of the female population will be in the postmenopausal age group. There will also be a wider use of oestrogen replacement therapy in this group of population as there is now an increasing awareness of its benefits in the prevention of genital atrophy, cardiovascular disease and osteoporosis<sup>(2,3)</sup>. The incidence of postmenopausal bleeding is thus expected to rise.

The significant frequency with which malignancy occurs mandates careful diagnostic evaluation. It begins with a careful history, which includes a review of the systemic medical history and drug use, and a thorough clinical examination. With few exceptions there will be a need to sample the endometrium for histologic examination.

The objective of this study is to examine the aetiology and pattern of postmenopausal bleeding in the Singapore population.

## MATERIAL AND METHODS

The case records for all patients seen for postmenopausal bleeding from January 1991 to June 1992 in Kangang Kerbau Hospital, Singapore were reviewed. It consisted of 163 patients who were 40 years of age or more, presenting with postmenopausal bleeding

for the first time and underwent diagnostic dilatation and curettage (D&C) of the uterus. The time lapse from the last menstruation was at least six months.

All records acquired were carefully analysed. The various data obtained included age, race, gravidity/parity, age at menopause, interval between last menstrual period and onset of postmenopausal bleeding and duration of bleeding. The use of medications containing oestrogen or medications that are metabolised to compounds with oestrogenic activity, such as digitalis and spironolactone, were documented. Any history of associated medical conditions, particularly those that could give rise to raised oestrogen levels from decreased metabolic clearance of oestrogen and its precursors, such as liver disease, congestive heart failure or hypothyroidism, was noted. Any urinary and gastrointestinal symptoms were taken into account as they may suggest an extragenital source of bleeding. Attention was also given to findings of blood pressure, body weight, pelvic examination and histopathologic findings of curetting. A Papanicolaou smear was obtained if not recorded within the previous six months.

The histologies of endometrial curetting were documented. In addition, they were divided into 4 groups for further analysis: group 1 (atrophic or inactive endometrium), group 2 (proliferative endometrium), group 3 (hyperplastic endometrium including cystic hyperplasia, adenomatous hyperplasia, atypical adenomatous hyperplasia), and group 4 (endometrial carcinoma).

## RESULTS

In our series of 163 patients, the mean age of onset of postmenopausal bleeding was 58.1 years with a standard deviation (SD) of 7.5 years. The patients' ages ranged from 43 to 84 years with the majority (60.7%) between 50 to 59 years of age (Fig 1). About two-thirds (67%) of the study population presented with postmenopausal bleeding before the age of 60. The mean menopausal age was 50.4 years (SD 3.8 years), ranging from 40 to 59 years. Menopause would have occurred in about 83% by the time they were 54 years of age and the distribution of menopausal age was shown in Fig 2. The interval between menopause and the first episode of postmenopausal bleeding varied from 7 months to 44 years and the mean was 7.6 years (SD 8.1 years). Fig 3 showed the distribution, and a large proportion had their first episode of bleeding within 10 years from menopause.

---

Department of Maternal Foetal Medicine  
Kandang Kerbau Hospital  
1 Hampshire Road  
Singapore 0821

W H Lee, MBBS, MRCOG  
Registrar

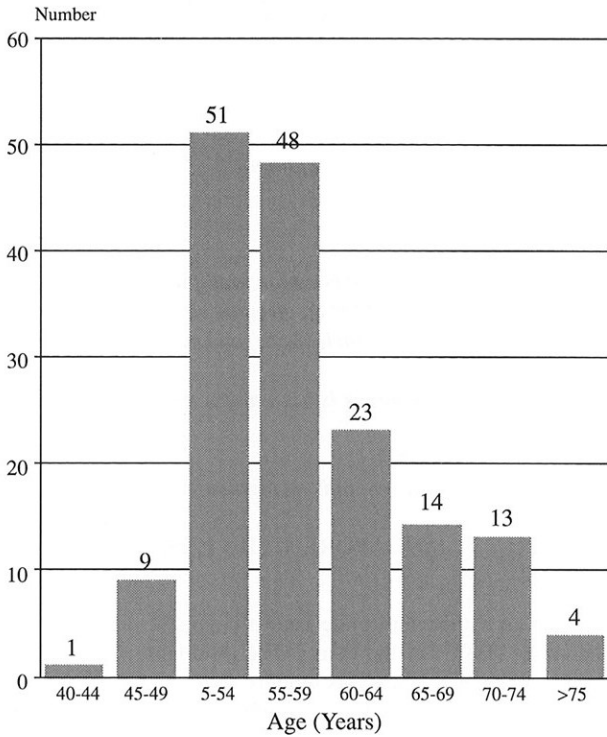
K H Tan, MBBS, M Med (O & G), MRCOG  
Registrar

Y W Lee, MBBS  
Medical Officer

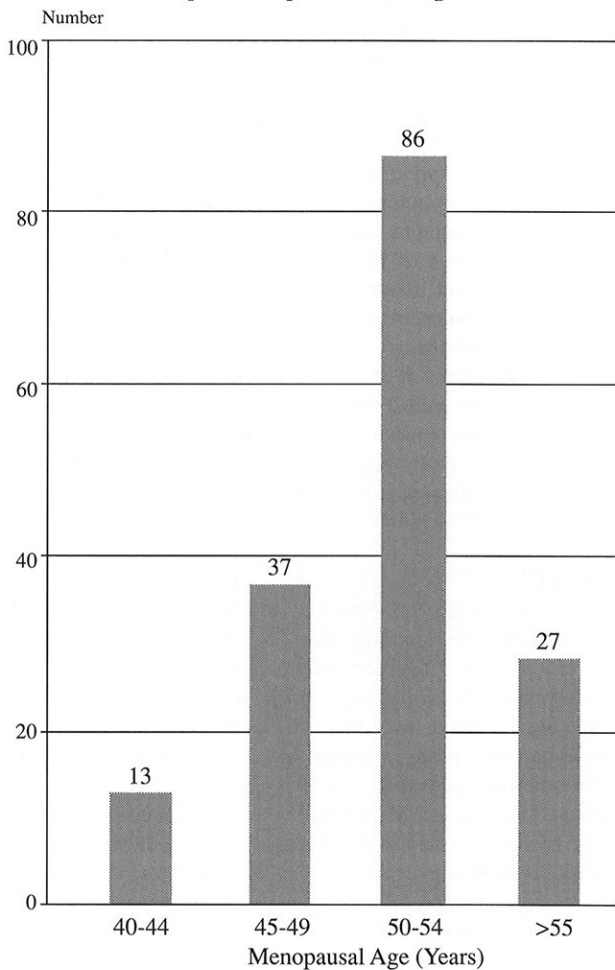
Correspondence to: Dr W H Lee

---

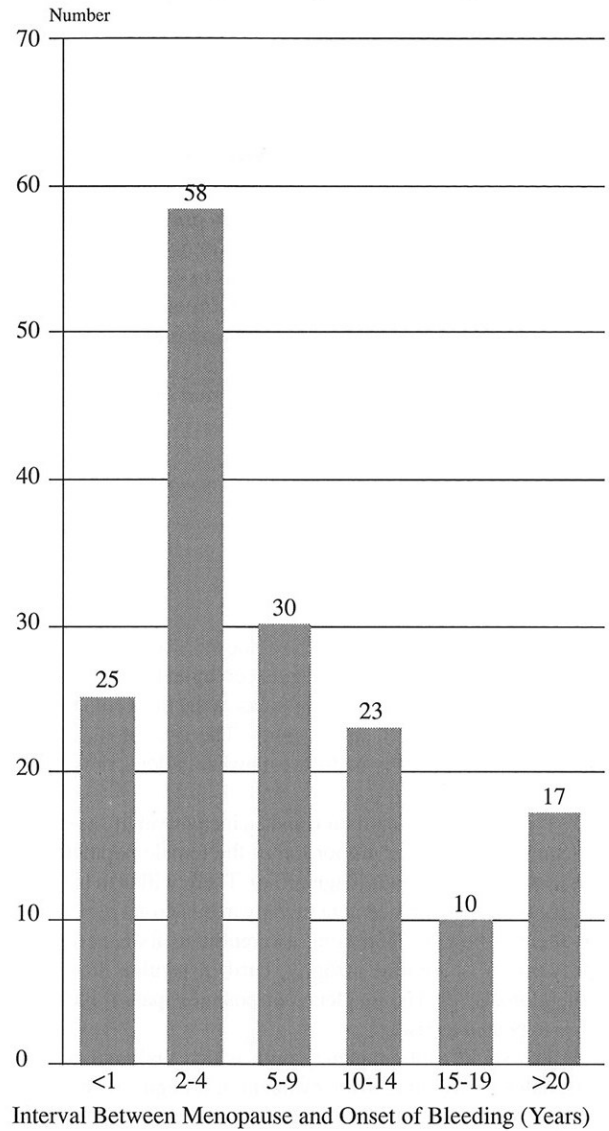
**Fig 1 – Distribution of age in 163 patients with postmenopausal bleeding**



**Fig 2 – Distribution of menopausal age in 163 patients with postmenopausal bleeding**



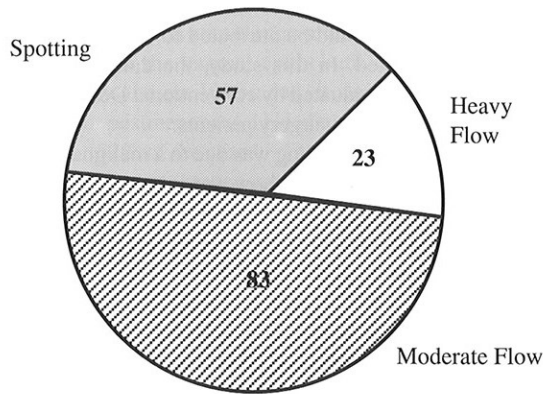
**Fig 3 – Distribution of interval between menopause and onset of postmenopausal bleeding**



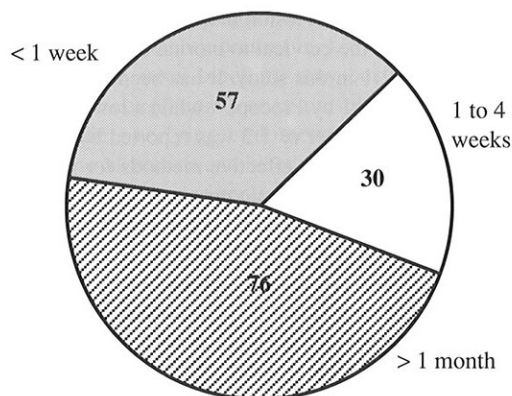
The amount and duration of bleeding experienced by our patients were studied. The amount of bleeding was documented from the patient's history as spotting, moderate flow and heavy flow. The duration was divided into less than one week, a week to a month, and more than a month. The distributions of these two parameters are shown in Figs 4a and 4b, respectively. Most had spotting or moderate flow (86%), but about half the patients (47%) waited for more than a month before seeking treatment.

The parity of our patients averaged 4.0 (SD 2.5) although it ranged from 0 to 12. The racial distribution of the study group comprised Chinese (85%), Malays (16%) and Indians (8%). The mean body weight of the study population was 59.5 kg (SD 10.8 kg), with a range of 34.6 kg to 84 kg. About 12% of patients, whose weight was 25% or more above their ideal weight, were considered obese. Forty percent (65) of the patients had associated medical problems. Hypertension was the most common (17%), followed by diabetes mellitus (12%) and cardiac disease (5%). In the group with cardiac disease, all the 8 patients had ischaemic heart disease but there was no evidence of congestive cardiac failure. There was one patient who had a history of hypothyroidism on thyroxine replacement and was euthyroid. Histology of her endometrial curetting was atrophic endometrium.

**Fig 4a – Severity of postmenopausal bleeding experienced by study population**



**Fig 4b – Duration of postmenopausal bleeding at presentation**



The diagnoses in our cohort of patients who presented with postmenopausal bleeding and their frequency of occurrence are shown in Table I. It was found to be associated with malignancy in 26% (42) of the patients. Most of these cases (93%) had either endometrial or cervical carcinoma. Cervical carcinoma (50%) was the commonest malignancy followed by endometrial carcinoma (43%), an incidence which parallels the incidence in the female population of Singapore. Those with carcinoma of the cervix were significantly older (mean age  $64.1 \pm 7.3$  years) than the rest ( $p < 0.01$ ,  $t = 2.23$ ). The proportion of patients who were nulliparous was found to be higher in those with endometrial carcinoma (16%) than the rest (5%).

There were two patients with ovarian carcinoma. One had Stage IIc poorly differentiated serous adenocarcinoma of the right ovary with uterine involvement, and the other had Stage Ic granulosa cell tumour of the right ovary. Another patient had a tumour arising from the vaginal vault, which was reported histologically as unclassified high grade malignant tumour. Interestingly, there were two cases of pyometra (1.2%) that were associated with a bulky cervical carcinoma stenosing the cervical os in one, and a moderately differentiated endometrial carcinoma involving the cervix in the other.

The mean age in the group with malignancy was 61.5 years (SD 7.0 years), which was significantly higher than in the non-malignant cases ( $p < 0.01$ ,  $t = 3.60$ ). Similarly, the mean interval between menopause and onset of vaginal bleeding in this group

with malignancy (mean  $10.1 \pm 7.3$  years) is significantly longer ( $p < 0.01$ ,  $t = 2.32$ ) than in those without malignancy (mean  $6.8 \pm 8.2$  years). The slightly older mean menopausal age of 51.4 years (SD 3.7 years) was observed in the malignant group compared to those with benign causes (mean  $50.1 \pm 3.8$  years) although it was not statistically significant. In 69% (29) of those with a malignant cause, presentation was spotting or moderate bleeding, while 38% (16) gave a history of bleeding for more than a month when they were first seen.

A review of the 98 patients who had a benign cause of postmenopausal bleeding revealed atrophic vaginitis, cervicitis and cervical polyp as the common causes (Table I). Fibroids were detected in 7 patients in which no other cause of bleeding could be identified. Only 3 patients were diagnosed to have bleeding due to oestrogen-progestin replacement therapy. They were less than 60 years old and they presented with irregular bleeding, one of them had heavy flow while the other two patients had moderate flow. The histology was proliferative endometrium in these patients. It is worthy of note that one patient, who was uncertain of the origin of bleeding, presented with postmenopausal bleeding that was later found to be haematuria due to cystitis. Urethral caruncle was found to be the cause in 4 patients. There were, however, 40 patients (24.5%) in whom no demonstrable cause could be found.

**Table I – Diagnosis and number of cases in 163 patients with postmenopausal bleeding.**

	Number of Cases	Percent
<i>Malignant conditions</i>		
Cervical carcinoma	21	12.9
Endometrial carcinoma	18	11.0
Ovarian carcinoma	2	1.2
Vaginal carcinoma	1	0.6
<i>Non malignant conditions</i>		
Cervicitis	21	12.9
Atrophic vaginitis	20	12.3
Cervical polyp	11	6.7
Fibroid	7	4.3
Endometrial hyperplasia	5	3.1
Uterovaginal prolapse	4	2.5
Urethral caruncle	4	2.5
Endometrial polyp	3	1.8
Oestrogen replacement therapy	3	1.8
Endometritis	2	1.2
Cystitis	1	0.6
No demonstrable lesion	40	24.5
<b>Total</b>	<b>163</b>	<b>100</b>

The histology of the uterine curetting obtained at dilatation and curettage is shown in Table II. Atrophic endometrium was the most frequent finding. The endometrial histology corresponded with proliferative endometrium in 26 cases and secretory endometrium in 5 cases. The 3 patients on oestrogen replacement therapy and cyclic progestogen had proliferative endometrium and they were observed to be younger (mean age  $50.0 \pm 6.3$ ). There were 5 (3.1%) patients with cystic endometrial hyperplasia while 18 (11.0%) had endometrial carcinoma. Inadequate tissue for diagnosis was found in 22 (13.5%) of the patients.

**Table II – Histology of endometrial curettings in 163 patients with postmenopausal bleeding**

	Number of Cases	Percent
Atrophic endometrium	85	52.1
Proliferative endometrium	26	16.0
Endometrial carcinoma	18	11.0
Hyperplastic endometrium	5	3.1
Secretory endometrium	5	3.1
Endometritis	2	1.2
Inadequate tissue	22	13.5
Total	163	100

## DISCUSSION

It is often difficult to give an accurate definition of the postmenopausal state. In this study, women aged 40 years and above with at least six months amenorrhoea were arbitrarily taken to indicate that menopause had occurred, provided pregnancy had been excluded. Any genital bleeding after this period of six months was considered as postmenopausal bleeding<sup>(4)</sup>. This was felt to be an adequate period of time lapse for denoting the final cessation of menstruation although some authors prefer one year<sup>(5,6)</sup>.

Postmenopausal bleeding is becoming one of the common clinical problems in our gynaecologic clinic as women in their menopausal years are forming an increasingly large part of the local population. It is often a source of much concern to patients because it is well known that the cause may be a malignant disease. The clinician, who treats such patients, has to ensure that no serious pathology exists.

The average age of menopause in this group of patients was found to be about 50 years and with an average female life expectancy of 76.5 years in this country, this means that for many women one-third of their life is postmenopausal. In those who had postmenopausal bleeding, it usually presented before the age of 60 years (67%), and in a large proportion of patients, this occurred within 10 years from menopause (69%).

Profuse bleeding was uncommon, and the amount of bleeding was found to be relatively unimportant as 69% of those who had a malignant cause only had spotting or moderate bleeding. Thus any postmenopausal bleeding, regardless of the amount, is significant and requires a full and complete evaluation. It was disconcerting to note that about half the patients was symptomatic for more than a month before seeking medical attention. Thirty-eight percent of patients with a malignant cause fell into this group. This is probably because of the lack of awareness of the importance of this symptom and it would be useful to educate the public regarding this aspect.

It is not surprising to find that about 40% of the patients had associated medical problems as they were elderly. These conditions pose increased medical risks in anaesthesia and surgery. However, none had any condition that predisposed to raised oestrogen levels. Oestrogen replacement therapy used in relieving symptoms due to oestrogen deficiency and, more importantly, helping in the prevention of osteoporosis and cardiovascular disease in menopausal women has attracted much attention from the public and professionals in recent years. Only three patients in our series were found to be on this therapy. In these patients, the postmenopausal bleeding was attributed to this treatment as no other cause was found. This incidence (1.8%) is far below those reported in other series<sup>(7,8)</sup>. However, the local incidence is expected to rise rapidly as the medical profession and the general public become more familiar with the benefits

of hormone replacement therapy.

The incidence of the various causes of postmenopausal bleeding has been the subject of many studies<sup>(9-12)</sup>, usually with emphasis on the incidence of malignancy. The considerable variation in results could be attributed to the way in which the cases were selected. In this study, the data were based on consecutive cases evaluated by conventional D&C of the uterus in hospitalised and day surgery patients.

Postmenopausal bleeding was due to a malignant process in 26% of our cases. There is, however, a great variation in the incidence of postmenopausal bleeding due to malignancy in different reported series ranging from 5.4% to 76%<sup>(1,5,13)</sup>. Patients who had postmenopausal bleeding due to malignancy were generally older than those without malignancy. Similar trends were reported by Procopé<sup>(5)</sup>. It was also observed in this study that the cause was more likely to be malignant if there was a long interval between onset of bleeding and menopause.

Carcinoma of the cervix was the commonest malignant condition with an incidence of 12.9%, making it an extremely important diagnostic consideration in the patient who presents with postmenopausal bleeding. Therefore, the cervix should always be visualised and assessed cytologically by Papanicolaou smear and any suspicious lesion biopsied.

An analysis of the cervical to uterine cancer ratio revealed the ratio to be 1.2:1 in this study. It has been reported to be of equal incidence of 1:1 by Procopé<sup>(5)</sup> while a lower incidence of cervical to uterine cancer of 1:2 was reported by Hathcock<sup>(14)</sup>. The latter could be due to effective methods for the screening and diagnosis of cervical carcinoma and its precursor lesions which effectively eliminated it as a significant cause of postmenopausal bleeding. On the other hand, in countries without effective cervical screening programme, especially in underdeveloped countries, the ratio of cervical to uterine cancer in patients with postmenopausal bleeding is high<sup>(15)</sup>. It was also not surprising to find that cervical cancer accounted for nearly half of patients with a malignant cause in our series as there is yet no comprehensive cervical cytology screening programme in this country. Although routine Papanicolaou smear in this country is easily available and widely encouraged, our system depends on opportunistic screening of women who seek medical care and this misses out on many women, especially the elderly women who may not be aware of the importance of routine Papanicolaou smears. A comprehensive population cervical cytology screening programme is needed in Singapore.

Endometrial carcinoma was found in 11% of the studied population, making it the next commonest malignant cause. The incidence varies widely between different studies but is usually taken to be between 15% to 20% of women with postmenopausal bleeding<sup>(5,10,13)</sup>. As methods of screening for asymptomatic endometrial carcinoma are not as effective as that for cervical carcinoma, postmenopausal bleeding is often the first indication of its occurrence and thus the importance of a thorough evaluation should be realised.

Ovarian adenocarcinoma is an exceptionally rare cause of postmenopausal bleeding, and in our patient it had invaded the uterine cavity giving rise to bleeding. While functioning ovarian tumours, such as the granulosa cell ovarian tumour in our patient, are rare, it should be seriously considered in the formerly hypoestrogenic postmenopausal woman who shows evidence of oestrogen stimulation without any exogenous source.

A non-malignant cause was found in 74.2% of the patients. Cervicitis and atrophic vaginitis were the two most common conditions and together they account for one-third of the cases in this group.

Cervicitis was seen in 12.9% of the patients. The

Papanicolaou smears were inflammatory in nature, and in some patients, a colposcopic-directed biopsy was necessary to exclude malignancy when the erosions appeared suspicious. Atrophic vaginitis, which was found in 16.5% of cases, was due to the withdrawal of oestrogen stimulation after menopause resulting in the shrinking of the vaginal epithelium. The vaginal walls become thin, dry and easily abraded. It was the most common benign cause for postmenopausal bleeding in Dewhurst's series<sup>(9)</sup>, accounting for 52% of the cases.

The most important benign cause of postmenopausal bleeding is endometrial hyperplasia. In our cohort, this was relatively uncommon, being present only in 3.1% of patients. They were found to be cystic endometrial hyperplasia, a condition which is considered to have very low malignant potential<sup>(16,17)</sup>. On the other hand, adenomatous hyperplasia with atypia is considered to be a precursor of uterine carcinoma.

Cervical polyps were relatively common, occurring in 6.7% of the patients. Papanicolaou smear was taken and the polyp removed for histology in each patient to exclude malignancy. They were found to be benign polyps. The finding of a fibroid in a patient with postmenopausal bleeding does not imply that it is the cause. Other causes, especially carcinoma of the cervix and uterus, were excluded in these patients. Leiomyomata were found to be the only abnormality present in 4.3% of patients in this series. Postmenopausal bleeding may occur as a result of increased pelvic congestion<sup>(9)</sup>, or as a result of the atrophy and thinning of the overlying endometrium and myometrium predisposing to ulceration and bleeding<sup>(18)</sup>.

Oestrogen-progestogen replacement therapy was observed to be infrequent in our study population as only 3 (1.8%) gave a history of this treatment. They belonged to a younger age group and had irregular bleeding which was found to be due to breakthrough or withdrawal bleeding.

There had always been concern about the association of postmenopausal oestrogen therapy with the development of endometrial carcinoma as it is being used more frequently as a prophylaxis against osteoporosis, cardiovascular disease and for treatment of hypoestrogenic symptoms. Although the epidemiologic studies by Ziel and Finkle<sup>(19)</sup> and Mack et al<sup>(20)</sup> showed an increased risk of endometrial carcinoma in those treated with conjugated oestrogens, the addition of a progestogen was shown to confer protection against endometrial hyperplasia and carcinoma<sup>(21)</sup>. Therefore, oestrogen-progestogen should be considered in those women in their menopause who had no contraindications to its use. They should have regular follow-up and if there is any irregular bleeding, a careful gynaecological examination in combination with Papanicolaou smear and curettage is always necessary for a confident diagnosis.

Pyometra is caused by intrauterine retention of infective material due to a stenosed cervix. This could arise from postmenopausal tissue shrinkage with the cervix becoming fibrous and stenosed, or from carcinoma involving the cervix, as in our two patients.

Dilatation and curettage (D&C) of the uterus is the traditionally acceptable method for evaluating postmenopausal bleeding. Other methods have been used to obtain endometrial samples for histologic evaluation and they include cytologic or histologic endometrial sampling methods<sup>(22-24)</sup> and hysteroscopy directed biopsies<sup>(25)</sup>.

In our study, there was no significant demonstrable cause found in 24.6% of the patients. In over half of these cases the histology showed atrophic endometrium or proliferative endometrium. The remaining cases had inadequate tissue for histological diagnosis.

Atrophic endometrium is the most often reported histologic

finding in the uterine curetting of our patients. A variety of causes for bleeding from the atrophic endometrium have been postulated, including myometrial arteriolar disease, atrophic endometrial cysts, atrophic endometritis<sup>(26)</sup> and chronic passive congestion of the uterus<sup>(27)</sup>.

Proliferative endometrium is due to oestrogen stimulation, while the cystic adenomatous hyperplasia is due to occlusion of gland mouths and the accumulation of secretion within the glands. The five patients who showed a secretory endometrium belonged to a younger age group, and were probably due to some activation of the ovaries.

## CONCLUSION

Postmenopausal bleeding is a symptom of varied aetiology. It is associated with a high incidence of malignancy (26% in our series). It is therefore mandatory to perform a thorough diagnostic evaluation in patients with postmenopausal bleeding. An accurate diagnosis will not only make it much easier to counsel the patient confidently about the appropriate course of action, but also facilitate carrying out the proper treatment plan that will benefit the patient.

## REFERENCES

- Pacheco JC, Kempers RD. Etiology of postmenopausal bleeding. *Obstet Gynecol* 1968; 32:40-6.
- Judd HL, Cleary RE, Creasman WT, Figge DC, Kase N, Rosenwaks Z. Estrogen replacement therapy. *Obstet Gynecol* 1981; 58:267-75.
- Hammond CB, Maxson WS. Current status of estrogen therapy for the menopause. *Fertil Steril* 1982; 37:5-25.
- Lachelin G. ed. The menopause. In: *Introduction to Clinical Reproductive Endocrinology*. London: Butterworth-Heinemann. 1991:172-86.
- Procopio BJ. Aetiology of postmenopausal bleeding. *Acta Obstet Gynecol Scand* 1971; 50:311-3.
- Merrill JA. Management of postmenopausal bleeding. *Clin Obstet Gynecol* 1981; 24:285-99.
- Miyazawa K. Clinical significance of an enlarged uterus in patients with postmenopausal bleeding. *Obstet Gynecol* 1983; 61:149-52.
- Richards CJ, Kase NG. Diagnosis and management of perimenopausal and postmenopausal bleeding. *Obstet Gynecol Clin North Am* 1987; 14:169-89.
- Dewhurst JD. Postmenopausal bleeding from benign causes. *Clin Obstet Gynecol* 1983; 23:769-77.
- Keirse MJ. Aetiology of postmenopausal bleeding. *Postgrad Med J* 1973; 49:344-8.
- Mantalenakis SI, Papapostolon MG. Genital bleeding in females age 50 and over. *Int Surg* 1977; 62:103-5.
- Payne FL, Wright RC, Fetterman HH. Postmenopausal bleeding. *Am J Obstet Gynecol* 1959; 77:1216-7.
- Gambrell RD. Postmenopausal bleeding. *J Am Geriatr Soc* 1974; 22:337-43.
- Hathcock EW, Williams GA, Englehardt SM, Murphy AL. Office aspiration curettage of the endometrium. *Am J Obstet Gynecol* 1974; 120:205-13.
- Panda S, Panda SN, Sarangi RK, Habeebullah S. Postmenopausal bleeding. *J Indian Med Assoc* 1977; 68:185-8.
- Tung VD. ed. The endometrium. In: *Syllabus of gynecologic pathology with clinical correlations*. Texas: University of Texas Press. 1990: 56-70.
- Walter JB, Isreal MS. eds. Disorders of growth. In: *General pathology*. Edinburgh: Churchill Livingstone 1987:320-34.
- Mattlingly RF, Thompson JD. eds. Leiomyomata uteri and abdominal hysterectomy for benign disease. In: *TeLinde's operative gynecology*. Philadelphia: JB Lippincott. 1985:210-7.
- Ziel HK, Finkle WD. Increased risk of endometrial carcinoma among users of conjugated estrogens. *N Engl J Med* 1975; 293:1167-70.
- Mack TM, Pike MC, Henderson BE, Pfeffer RI, Gerkins VR, Arthur M, et al. Estrogens and endometrial cancer in a retirement community. *N Engl J Med* 1976; 294:1262-7.
- Gambrell RD. The menopause: benefits and risks of estrogen-progestogen replacement therapy. *Fertil Steril* 1982; 37:457-74.
- Grimes DA. Diagnostic dilatation and curettage: A reappraisal. *Am J Obstet Gynecol* 1982; 142:1-6.
- Kawada CY, Song HA. Screening for endometrial cancer. *Clin Obstet Gynecol* 1979; 22:713-28.
- Stovall TG, Solomon SK, Ling FW. Endometrial sampling prior to hysterectomy. *Obstet Gynecol* 1989; 73:405-9.
- Gimpelson RJ, Rappold HO. A comparative study between panoramic hysteroscopy with directed biopsies and dilatation and curettage. *Am J Obstet Gynecol* 1988; 158:489-92.
- Novak E, Woodruff JD. eds. *Histology of endometrium*. In: *Novak's gynecologic and obstetric pathology with clinical and endocrine relations*. Philadelphia: W B Saunders Company, 1967:155-73.
- Kanter AE, Klawans AH. Postmenopausal bleeding. *Surg Clin N Am* 1950; 30:287-97.