

LEFT VENTRICULAR MYXOMA, ADRENAL TUMOUR AND CUTANEOUS VASCULITIS - A CASE REPORT

W H Koh, S C Chuah, H H Chng

ABSTRACT

Cardiac myxoma has myriad presentations including cutaneous vasculitis. It has also been associated with endocrine neoplasm in Carney's Complex. We report a Chinese patient with cutaneous vasculitis and Raynaud's phenomenon suggesting a collagen vascular disease. In the course of investigation, echocardiogram showed a possible left ventricular myxoma and computed tomography of the abdomen demonstrated a left adrenal tumour. Cardiac myxoma should be considered in the differential diagnosis of vasculitis.

Keywords: ventricular myxoma, adrenal tumour, vasculitis

SINGAPORE MED J 1995; Vol 36: 328-330

INTRODUCTION

In 1985, Carney and co-workers first described a complex consisting of myxomas, spotty pigmentation and endocrine overactivity⁽¹⁾. The occurrence of these rare conditions together were thought unlikely to be co-incidental. Many of the patients had primary pigmented nodular adrenocortical disease while the skin lesions consisted predominantly of lentiginos and nevi. We describe a Chinese patient with the rare association of cutaneous vasculitis, Raynaud's phenomenon, left ventricular myxoma and a functioning adrenal tumour.

CASE REPORT

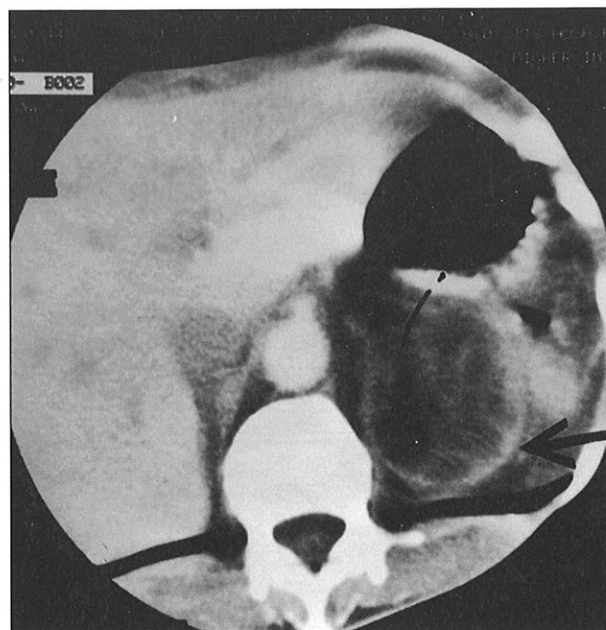
The patient, a 39-year-old Chinese female, had a history of pulmonary tuberculosis in 1969 which was treated. She subsequently developed post-tuberculous bronchiectasis. In August 1992, the patient was admitted for breathlessness, pedal swelling and increased purulent sputum of a few days' duration associated with loss of weight and appetite. There were no chest pains, palpitations or fever.

Clinical examination showed her to be cachexic and centrally cyanosed. She was afebrile, had a blood pressure of 110/80 mmHg and a regular pulse rate of 100 per minute. The apex beat was displaced at the 6th intercostal space, left anterior axillary line. The heart sounds were dual and no murmur was heard. There was pitting edema in the legs and the jugular venous pressure was elevated. Bilateral coarse crepitations and expiratory rhonchi were heard in the lungs. There was absence of hepatosplenomegaly and no masses were palpable in the abdomen. The initial diagnosis was cor pulmonale with cardiac failure secondary to bronchiectasis.

The arterial blood gas taken whilst on room air showed PO₂ 51.4 mmHg, PCO₂ 58mmHg, pH 7.443 and standard HCO₃ 34.3 mmol/litre. The chest radiographic film showed cardiomegaly and cystic changes in both lung fields consistent with bronchiectasis while an electrocardiogram revealed right axis deviation, right bundle branch block and Q waves from V₁ to V₄. She had significant proteinuria of 1.1 gm in 24 hours. The serum albumin was 28 gm/litre. Phase contrast microscopy of the urinary sediments was not indicative of glomerulonephritis. A rectal biopsy, performed to exclude amyloidosis, was normal.

An ultrasound of her kidneys incidentally revealed a left adrenal mass measuring about 4.4 cm in diameter. A computed tomographic scan of the abdomen confirmed a rounded left adrenal mass with well defined margins and patchy areas of low attenuation within (Fig 1). No calcifications were seen. The patient had biochemical evidence of hypercortisolism with an elevated 8 am plasma cortisol level of 1655 nmol/litre and a 24-hour urine cortisol of 0.91 umol, measured after she was on dexamethasone 2 mg thrice daily for two days. Plasma ACTH, serum testosterone, deoxyhydroepiandrosterone were normal. A week after admission she developed a palpable purpura

Fig 1 - Computed tomographic scan of the abdomen showing the left adrenal tumour (arrow).



Department of Rheumatology & Immunology
Tan Tock Seng Hospital
Moulmein Road
Singapore 1130

W H Koh, MRCP (UK)
Registrar

H H Chng, M Med (Int Med)
Consultant

Department of Cardiology
Tan Tock Seng Hospital

S C Chuah, MRCP (UK)
Consultant

Correspondence to: Dr W H Koh

indicative of a vasculitic rash on her extremities and later Raynaud's phenomena and splinter haemorrhages. She had no arthritis or retinal infarcts. Biopsy of the skin lesion showed necrotising vasculitis with perivascular neutrophilic and lymphocytic infiltrate (Fig 2). Most vessels of the superficial plexus in the upper dermis showed thrombosis with necrosis of the cell walls. Deposits of IgM, IgA, Clq were seen in the upper and mid dermal vessels. Her antinuclear antibody, anticardiolipin antibody and Hepatitis B surface antigen were negative and serum complements C3, C4 were normal.

Cross sectional echocardiography was done to evaluate the degree of cor pulmonale and cardiac status. A large pedunculated mass, 2.2 cm x 1.9 cm, at the apex of the left

Fig 2 - Skin biopsy showing thrombosis and necrosis of the vessel cell walls with perivascular infiltrate of neutrophils and lymphocytes.

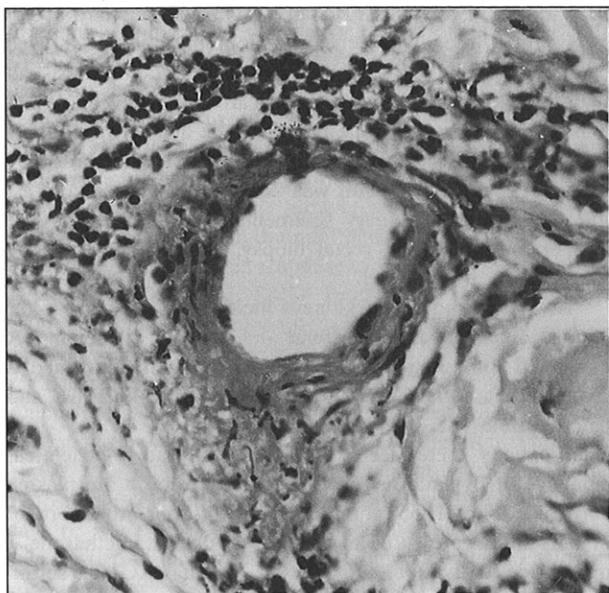
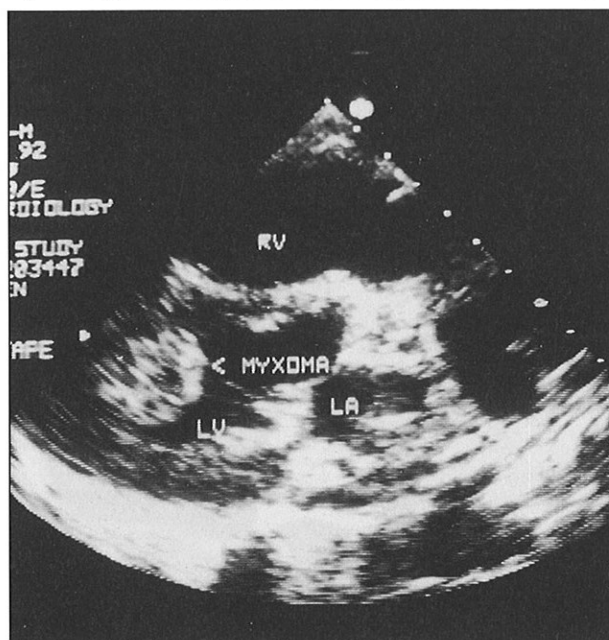


Fig 3 - Cross sectional echocardiography showing a mass lesion protruding into the left ventricle (arrow). (RV = right ventricle, LA = left atrium, LV = left ventricle)



ventricle consistent with a myxoma was found (Fig 3). The left ventricle had normal systolic function and chamber dimensions.

The patient and her family had refused any surgical intervention. She collapsed suddenly on 21 September 1992 and could not be resuscitated. A post mortem was not done as consent was not given.

DISCUSSION

This patient possessed an interesting constellation of rare medical conditions which included a left ventricular mass, left adrenal tumour and cutaneous vasculitis. Did she have a malignant left adrenal mass with metastatic deposits to the left ventricle with the vasculitis appearing as a sign of paraneoplastic syndrome⁽²⁾, or was there a left ventricular myxoma with embolic phenomenon mimicking peripheral vasculitis⁽³⁾ and a coincidental left adrenal tumour?

Computed tomographic scan has been shown to reliably differentiate benign from malignant lesions in the adrenals⁽⁴⁾. The tumour in this patient was likely to have been benign as evidenced by its smooth margins, distinct rounded shape and small size. The functioning nature of the adrenal tumour was demonstrated by the failure to suppress plasma cortisol and 24-hour urine cortisol levels.

Metastatic tumours of the heart are 20 to 40 times more common than primary cardiac tumours⁽⁵⁾. Solid tumours of the lung and breast, lymphomas and leukaemias largely account for the primary malignancies⁽⁶⁾. Metastatic lesions from the adrenals to the heart have not been reported and would be extremely rare. Furthermore, a secondary tumour of the heart is usually associated with metastatic disease elsewhere⁽⁷⁾, a feature not seen in the patient. Thus the left ventricular tumour is likely to be a primary cardiac tumour, of which two-thirds are benign, the commonest being myxoma^(5,8).

Myxomas have varied presentation including embolic and cutaneous vasculitis^(3,8). Their initial symptoms may mimic those of a collagen vascular diseases like polyarteritis nodosum and systemic lupus erythematosus⁽⁹⁾. Raynaud's phenomenon and splinter haemorrhages present in this patient have been described in association with cardiac myxoma^(3,10). Recent reports have even suggested that the production of interleukin-6 by the myxoma may be responsible for the immunologic features similar to those of autoimmune diseases⁽¹¹⁾. The patient developed peripheral vasculitis and various laboratory tests failed to determine a cause. Cutaneous vasculitis described as part of a paraneoplastic syndrome is usually associated with haematological neoplasia rather than a solid tumour like adrenal carcinoma⁽²⁾. The echocardiography incidentally demonstrated a left ventricular myxoma and it is probable that the skin lesions were a manifestation of the cardiac myxoma. Echocardiography has been used to diagnose cardiac myxoma reliably including those found in the left ventricle⁽¹²⁾.

The presence of significant proteinuria was difficult to account for. Rectal biopsy did not show amyloid deposits but this could be due to sampling error and renal amyloidosis secondary to bronchiectasis cannot be excluded.

Although the patient did not have pigmented skin lesions, the triad of left ventricular myxoma, adrenal tumour and cutaneous vasculitis easily forms part of Carney's Complex. A dominant inheritance of this complex was put forward by Carney who described a family in which at least one manifestation of the complex has occurred in three successive generations⁽¹³⁾. Our patients did not have a family history of

heart disease or endocrine disorder and we did not have the opportunity to examine her family.

In conclusion, this case illustrates a unique syndrome and a need to exclude cardiac myxoma in patients with cutaneous vasculitis. The early diagnosis of the myxoma by echocardiography has important therapeutic implications as surgical intervention can affect the patient's prognosis⁽¹⁴⁾.

ACKNOWLEDGEMENTS

The authors acknowledge the help of Dr Ng See Ket for the skin biopsy, Dr Ong Beng Hock and Mr Lee Siak Poh for their photography.

REFERENCES

1. Carney JA, Gordon H, Carpenter PC, Shenoy BV, Go VL. The complex of myxomas, spotty pigmentation, and endocrine overactivity. *Medicine(Baltimore)* 1985; 64: 270-83.
2. Sanchez-Guerrero J, Gutierrez-Urena S, Vidaller A, Reyes E, Iglesia A, Alarcon-Segovia D. Vasculitis as a paraneoplastic syndrome. Report of 11 cases and review of the literature. *J Rheumatol* 1990; 17: 1458-61.
3. Huston KA, Combs JJ Jr, Lie JT, Giuliani ER. Left atrial myxoma simulating peripheral vasculitis. *Mayo Clin Proc* 1978; 53: 752-6.
4. Adams JE, Johnson RJ, Rickards D, Isherwood I. Computed tomography in adrenal disease. *Clin Radiol* 1983; 34: 39-49.
5. Lancaster LD, Ewy GA. Cardiac consequences of malignancy and their treatment. *Arch Intern Med* 1984; 30: 275-93.
6. Bisel HF, Wroblewski F, La Due JS. Incidence and clinical manifestations of cardiac metastases. *JAMA* 1953; 153: 712-5.
7. Hanfling SM. Metastatic cancer to the heart. *Circulation* 1960; 22: 474-83.
8. Markel ML, Waller BF, Armstrong WF. Cardiac myxoma. A review. *Medicine (Baltimore)* 1987; 66: 114-25.
9. Fitzpatrick AP, Lanham JG, Doyle DV. Cardiac tumours simulating collagen vascular disease. *Br Heart J* 1986; 55: 592-5.
10. Byrd WE, Matthews OP, Hunt RE. Left atrial myxoma presenting as a systemic vasculitis. *Arthritis Rheum* 1980; 23: 240-3.
11. Jourdan M, Bataille R, Seguin J, Zhang XG, Chaptal PA, Klein B. Constitutive production of interleukin-6 and immunologic features in cardiac myxomas. *Arthritis Rheum* 1990; 33: 398-402.
12. Blondeau P. Primary cardiac tumours - French studies of 533 cases. *Thorac Cardiovasc Surg* 1990; 38(Suppl 2): 192-5.
13. Carney JA, Hruska LS, Beauchamp GD, Gordon H. Dominant inheritance of the complex of myxomas, spotty pigmentation, and endocrine overactivity. *Mayo Clin Proc* 1986; 61: 165-72.
14. Becker RC, Loeffler JS, Leopold KA, Underwood DA. Primary tumours of the heart: a review with emphasis on diagnosis and potential treatment modalities. *Semin Surg Oncol* 1985; 1: 161-70.

XVIII Symposium of the International Association For Comparative Research On Leukaemia And Related Diseases

Theme: 'Leukemia and Lymphoma/Pathogenesis and Treatment/Molecular Aspects'

29 October – 3 November 1995

Venue: Kyoto International Conference Hall
Kyoto, Japan

For information, please contact:

The Secretariat
XVIII IACRLRD Symposium
c/o Dr Yoji Ikawa
Dept of Retroviral Regulation
Tokyo Medical and Dental University
Medical Research Division
1-5-45 Yushima
Bunkyo, Tokyo 113
Japan
Fax: 81-3-3814-7172