

A CASE OF BILIARY ASCARIASIS ASSOCIATED WITH CALCULI IN THE GALL BLADDER AND THE COMMON BILE DUCT

T H Tan

ABSTRACT

A 44-year-old lady presented with symptoms suggestive of pathology of hepatobiliary origin. Real-time sonography reveals presence of biliary ascariasis, and calculi in both the gall bladder and common bile duct. The worm and the common bile duct calculi were successfully removed endoscopically.

Keywords: intrabiliary ascariasis, gall bladder and common bile duct calculi, sonography, follow-up.

SINGAPORE MED J 1995; Vol 36: 442-443

CASE REPORT

A 44-year-old Chinese lady presented with a history of epigastric pain for two months. Prior to admission acute pain was felt at the right upper quadrant of the abdomen. The nature of the pain was constant. There was no associated fever or jaundice, no history of recent travel.

The blood eosinophil count (11%, $0.75 \times 10^9/L$) was significantly raised. Liver function test showed both the total bilirubin and alkaline phosphatase to be slightly raised.

Sonographically, a long echogenic tubular structure with anechoic centre was seen in the left main hepatic duct and common bile duct (Fig 1). Calculi were seen in both the gall bladder and in the common bile duct (Fig 2). The common bile duct was dilated. The liver and pancreas were normal.

Fig 1 – Sonogram showed a nonshadowing, long echogenic tubular structure with an anechoic centre in common bile duct (arrow).

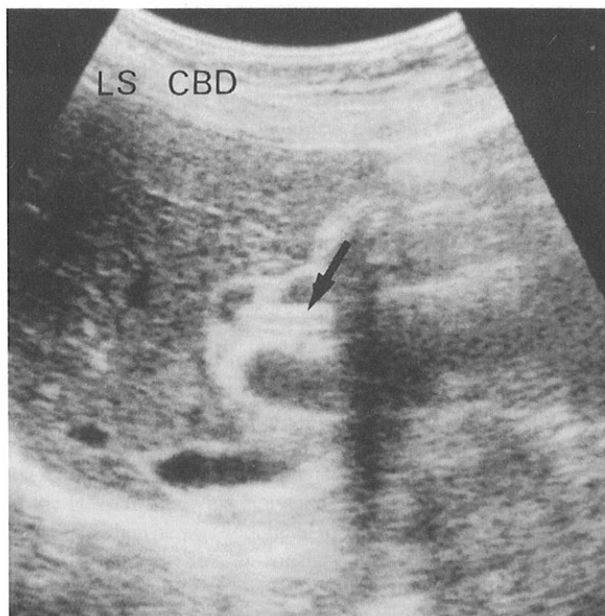
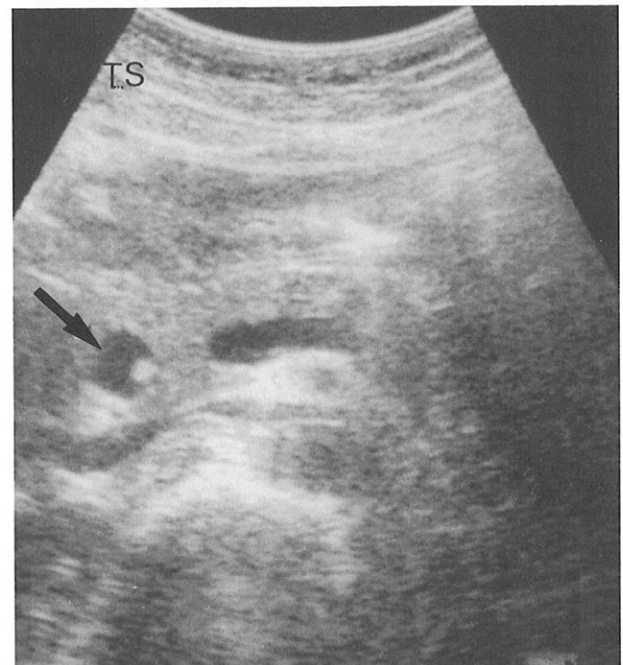


Fig 2 – Sonogram demonstrated a calculus in a dilated intrapancreatic common bile duct (arrow).



Endoscopic Retrograde Cholangiopancreatogram (ERCP) confirmed the presence of calculi in the common bile duct and gall bladder associated with a worm in the biliary duct (Fig 3). No worms were found in the stomach or the duodenum. Subsequently both the calculi in the common bile duct and the worm were removed endoscopically after sphincterotomy.

DISCUSSION

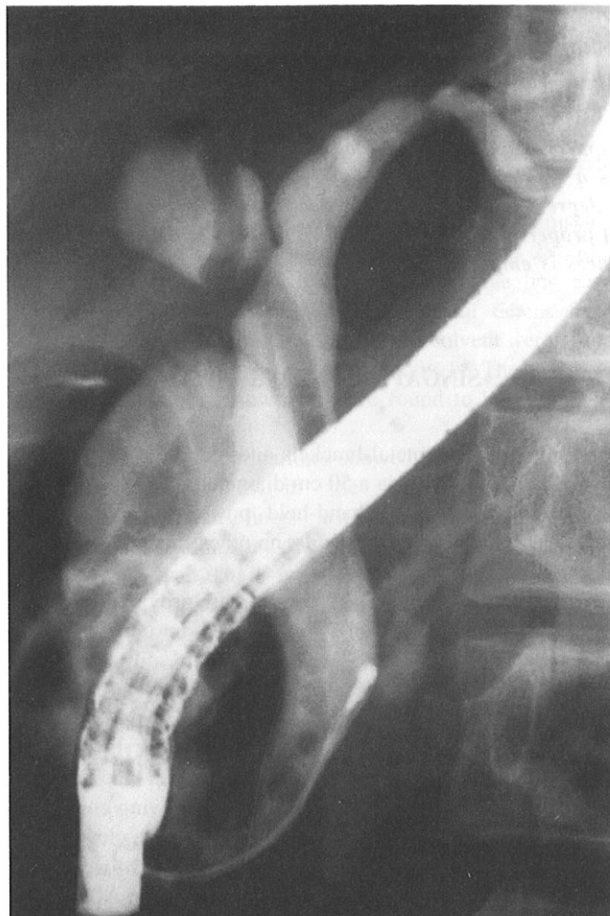
Ascaris lumbricoides is a parasitic disease of the human gastrointestinal tract. It can pass through the ampulla of Vater into the biliary or pancreatic ducts. The common clinical presentation includes abdominal pain mimicking biliary colic, nausea, vomiting and jaundice⁽¹⁾.

Ascariasis of the biliary system is associated with calculi and it has been suggested that the stones were formed around the dead *Ascaris* worms⁽²⁾. Complications do occur leading to biliary obstruction, cholecystitis, cholangitis, pancreatitis and even bile duct perforation. Occasionally massive infestation may lead to multiple hepatic abscesses, septicemia and even death⁽³⁾.

Department of Diagnostic Radiology
Caritas Medical Centre
Sham Shui Po, Kowloon
Hong Kong

T H Tan, MBBS (S'pore), FRCR (UK)
Senior Medical Officer

Fig 3 – ERCP showed a long tubular filling defect in the common bile duct and intrahepatic duct.



Hepatobiliary alterations found in autopsy case of massive biliary ascariasis suggest that inflammation and presence of the parasite remnants are responsible for the hyperplastic and metaplastic changes associated with intraductal papillomas

and adenomatous proliferation. These changes are also seen in chlonorchiasis, fascioliasis and schistomiasis infestations⁽⁴⁾. Therefore follow-up of these patients would be prudent.

Sonographic findings include a nonshadowing, long, echogenic tubular structure with an anechoic centre. On real-time ultrasonography, characteristic erratic movements of the worm are easily seen as in our case.

Occasionally the caudal part of a ventriculo-peritoneal drain implanted for hydrocephalus therapy may appear as a vermicular structure in the region of the gall bladder and be mistaken for a worm. Intra-biliary stent may also have similar appearance as ascariasis infestation on sonography. Therefore with a careful clinical history, making the wrong diagnosis is avoidable.

Uncomplicated manifestation of ascariasis is usually treated with appropriate drugs like Piperazine salts, pyrantel pamoate, mebendazole and many others. However when obstruction occurs the treatment is usually surgical, but in our case, endoscopic removal of the worm has been successfully performed.

Real-time sonography offers a simple, non-invasive, low-cost and rapid approach for the diagnosis of intra-biliary ascariasis and the follow-up of these patients for subsequent potential hyperplastic and metaplastic changes and possible reinvasion.

REFERENCES

1. Quintos Aranda C, Romero Jaimes GH, Athie A, Ibanez Fuentes JR, Santamaria Linares E, Velazquez-Macias RF. Biliary ascariasis. Experience at the Dr. Manuel Gea Gonzalez General Hospital. *Rev Gastroenterol Mex* 1990; 55(2): 61-5.
2. Choi MH, Park IA, Hong IK, Chai JY, Lee SH. A case of biliary ascariasis accompanied by cholelithiasis. *Kisaengchunghak Chapchi(Korea)* 1993;31:71-4.
3. Khuroo MS, Zargar SA, Mahajan R. Hepatobiliary and pancreatic ascariasis in India. *Lancet* 1990; 335:811-2.
4. Gayotto LC, Muszkat RM, Souza IV. Hepatobiliary alterations in massive biliary ascariasis. Histopathological aspects of an autopsy case. *Rev Inst Med Trop Sao Paulo.* 1990;32:91-5.