

DIAGNOSIS OF DEEP VEIN THROMBOSIS USING DUPLEX ULTRASONOGRAPHY

H C Tan, M C L Lim, M Choo, M B E Tay, H F Choo, S S S Lee

ABSTRACT

Duplex ultrasonography is a safe, accurate, efficient, inexpensive, noninvasive diagnostic test for deep vein thrombosis (DVT). The sensitivity and specificity of this technique is comparable to venography in symptomatic patients in many studies. The diagnostic accuracy of this test can be further enhanced by serial studies. We report our experience with the use of this technique for study of 180 patients with clinically suspected DVT. Only 55 (30.6%) patients were confirmed to have DVT on duplex ultrasonography which illustrates the inaccuracy of bedside diagnosis of this potentially life-threatening condition. Almost all our DVT patients have proximal vein involvement, indicating that venous thrombosis usually do not cause signs or symptoms until they become large, occlusive and extend into the proximal veins. It is also observed in our study cohort that half of the patients with proximal vein thrombosis has incomplete recanalisation on follow-up study. None of them with normal study developed significant sequelae of untreated DVT, suggesting that it is safe to withhold treatment based on result of this non-invasive test. Duplex ultrasonography is the diagnostic modality of choice for suspected DVT in symptomatic patients and is an excellent substitute for conventional contrast venography.

Keywords: duplex ultrasonography, deep vein thrombosis

SINGAPORE MED J 1995, Vol 36: 491-494

INTRODUCTION

Deep vein thrombosis (DVT) in hospitalised patients is a fairly common condition and has significant mortality and morbidity. Prompt diagnosis and treatment are needed to avoid major complications such as pulmonary embolism and disabling post-phlebotic syndrome.

Clinical diagnosis of DVT is notoriously insensitive and fallible⁽¹⁾. Many potentially dangerous venous thrombi are non-obstructive and non-inflammatory and therefore clinically inapparent. In addition, none of the clinical features of DVT are specific or unique, as they can be caused by non-thrombotic disorders. Therefore, objective tests to diagnose DVT are necessary.

Contrast phlebography has been the gold standard for diagnosis of DVT, but has many significant disadvantages such as invasiveness and the risk of dislodging thrombi. This has prompted the search for non-invasive tests of comparable diagnostic accuracy. In recent years, alternatives explored have included duplex ultrasonography, plethysmography,

thermography and radioactive fibrinogen uptake scanning. Among these, duplex ultrasonography currently appears most promising.

In this paper, we report our experience with the use of duplex ultrasonography in a large series of patients with suspected DVT to determine their characteristics, clinical course and complications.

METHODS

One hundred and eighty consecutive patients with clinically suspected DVT referred to our laboratory for ultrasonographic evaluation between February 1992 and March 1994 were enrolled into the study. Indications for referral, clinical characteristics and the presence of predisposing risk factors were recorded.

Venous duplex ultrasound scanning was performed in every case by experienced sonographers using an ACUSON 128XP/10M colour Doppler ultrasonograph which permits high-resolution imaging with a 5-MHz electronically focused linear array transducer. This machine allows imaging of calf veins as small as 2-3 mm in diameter. Routine scanning by real-time B-Mode and colour Doppler techniques included the proximal femoro-popliteal veins and the three groups of deep calf veins.

The diagnostic features (Fig 1 and 2) of DVT sought were: (1) direct visualisation of intraluminal thrombus; (2) visible lack of compressibility of involved venous segments; (3) absence of spontaneous Doppler venous flow or lack of phasicity (respiratory variation); and (4) absence of flow augmentation during distal limb compression (Fig 3). In addition, Doppler colour flow imaging within thrombosed segments was used to assess blood flow and degree of occlusion. As a rule, studies were conducted in both supine and standing positions. All recordings were reported by two independent observers based on stated criteria.

All patients with a positive ultrasonographic diagnosis of DVT were anticoagulated unless such treatment was contraindicated. Patients with negative studies were not anticoagulated. Follow-up was obtained in every patient either in the outpatient clinic or via a structured telephone interview.

RESULTS

Duplex ultrasonography found the presence of DVT in only 55 (30.6%) of the 180 patients. One additional patient with a negative ultrasound study was found to have DVT on computed

Cardiac Department
National University Hospital
5 Lower Kent Ridge Road
Singapore 119074

H C Tan, M Med (Int Med) MRCP (UK)
Registrar

M C L Lim, M Med (Int Med) MRCP (UK), FAMS
Consultant

M Choo, MD, FRCP (UK), FAMS
Professor and Chief

H F Choo, FRCP (UK), FAMS
Consultant

M B E Tay
Cardiovascular Sonographer

S S S Lee
Cardiovascular Sonographer

Correspondence to: Prof M Choo
3 Mt Elizabeth #06-06
Mt Elizabeth Medical Centre
Singapore 228510

Fig. 1a - Cross-sectional view of the normal right common femoral artery and vein.

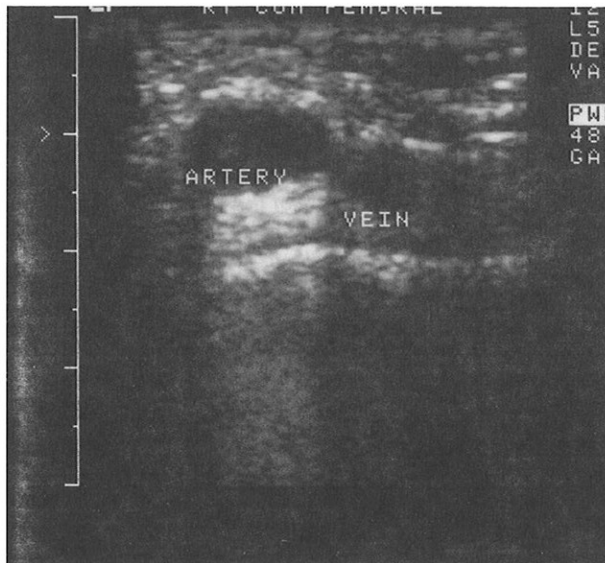


Fig. 1b - Cross-sectional view of the normal right common femoral vessels showing compressibility of the normal vein by transducer pressure. The normal artery is not compressible.

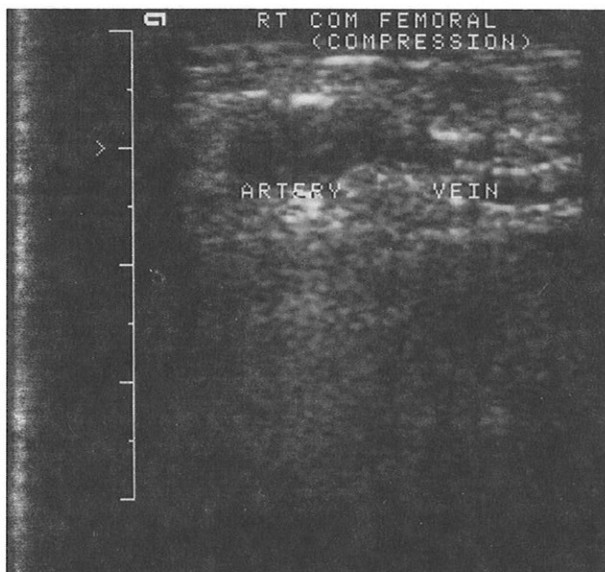


Fig. 2a - Cross-sectional view of the left common femoral artery and vein in the same patient showing venous thrombosis.

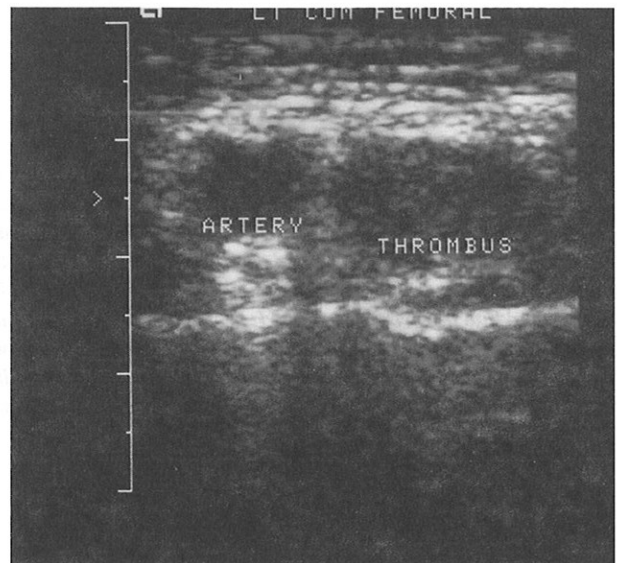
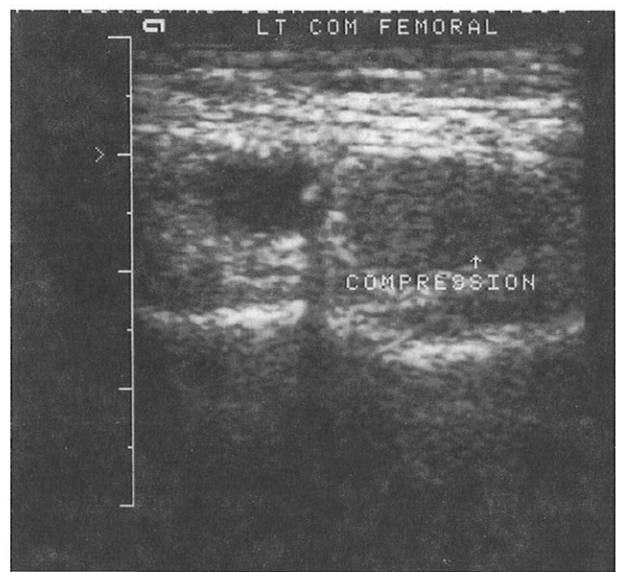


Fig. 2b - Cross-sectional view of the left common femoral vein which is thrombosed, dilated and non-compressible.



tomography. Of these 56 patients with a positive diagnosis confirmed objectively, 22 were male and 34 were female. Their ages ranged from 19 to 87 years (mean 56 years). The commonest risk factors were stroke (16.7%), malignancy (16.3%), surgery in the preceding 3 months (14.6%) and lower limb trauma (8.3%).

Almost all patients (53/55, or 96.4%) with ultrasonographically defined DVT had thrombosis within or proximal to the popliteal vein (Table I). Only 2 patients had isolated distal thrombosis within the tibio-peroneal veins.

All patients were anticoagulated except for 5 who, because of strong contraindications to anticoagulation, underwent insertion of an inferior vena caval filter. As a rule, symptomatic improvement occurred, but 6 patients died during therapy - 4 from underlying malignancy, one from fatal pulmonary embolism

Table I - Distribution of lower limb venous thrombi

Site	Number (%)
Proximal only	28 (50.9)
Proximal and distal	25 (45.5)
Distal only	2 (3.6)

Proximal location defined as popliteal vein or higher.

Distal location defined as below the popliteal vein within the tibio-peroneal system.

because of suboptimal anticoagulation, and one from major gastrointestinal haemorrhage.

Twenty patients had a repeat ultrasound scan performed 1-4 months after initial diagnosis. Half showed complete resolution of disease and half showed partial or no resolution (Table II).

Fig. 3 - Doppler signal in a proximal vein showing normal augmentation when distal draining veins are squeezed. If an intervening venous segment is thrombosed, augmentation will be attenuated or absent.

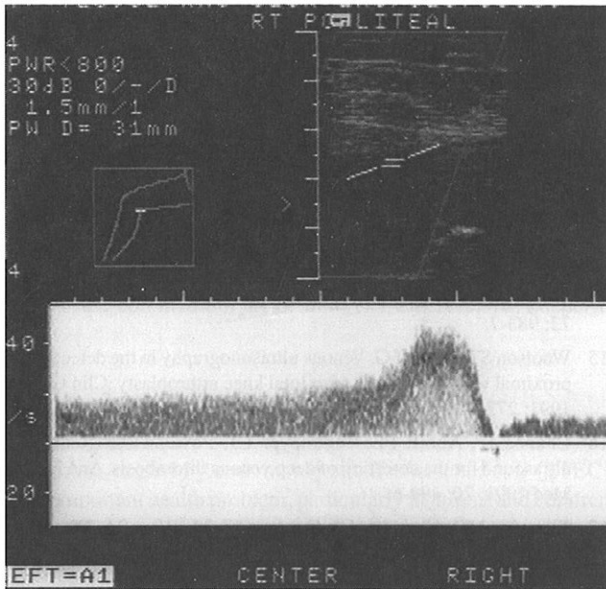


Table II - Late findings in 20 thrombosed veins

Findings	Number (%)
Complete resolution	10 (50.0)
Partial resolution	5 (25.0)
No resolution*	5 (25.0)

*Persistent occlusion

Table III - Revised diagnosis in patients with normal tests

Diagnosis	Number (%)
Cellulitis	14 (11.3)
Hematoma	3 (2.4)
Varicose veins	3 (2.4)
Phlebitis	2 (1.6)
Muscle sprain	2 (1.6)
Elephantiasis	1 (0.8)
Viral myositis	1 (0.8)
Unknown	98 (79.0)

Of the 124 patients without laboratory confirmation of DVT, 106 (85.5%) had resolution of symptoms and signs on follow-up 4 or more months after presentation. The diagnosis was revised in many cases (Table III). Eighteen patients (14.5%) died from underlying severe medical illnesses. None of the 124 patients without documented DVT suffered from a thromboembolic event.

DISCUSSION

Our findings agree with those of other investigators who have shown that only a minority of patients with clinically suspected DVT will have a positive diagnosis on ultrasonography. It is important to distinguish those with DVT from those without, as the disease carries significant morbidity and mortality and should be treated. Wrong diagnosis leading to unnecessary treatment however is inconvenient, expensive and may cause significant side-effects.

Numerous studies have been performed comparing venous

duplex ultrasonography with contrast venography for diagnosing DVT. These studies include real time B-mode imaging, Doppler velocimetry and colour flow techniques, used singly or in combination⁽²⁻²²⁾.

B-mode ultrasonography relies on direct visualisation of intraluminal thrombus or non-compressibility of the vein by transducer pressure. Lack of venous compressibility has been used as the sole criterion to diagnose DVT with great accuracy^(2, 5-8, 11, 12, 18, 19). Its sensitivity for diagnosing lower limb DVT is as high as 100% for the common femoral vein, dropping slightly to 93% for calf veins. Overall specificity is 100% when compared to venography⁽¹¹⁾. Serial studies may enhance its diagnostic accuracy⁽¹⁹⁾.

Although venous non-compressibility is a highly sensitive and specific finding in symptomatic patients with suspected DVT, it is much less useful as a screening tool in asymptomatic post-operative patients at high risk of DVT, detecting only one-third of proximal or calf vein thrombi visible on contrast venography⁽²³⁾. This is probably because subclinical post-operative thrombi tend to be small and associated with far less mural and perivascular reaction. Use of colour Doppler does not overcome this limitation. However the clinical value of detecting or missing such small thrombi is unknown⁽²²⁾.

In symptomatic patients however, colour Doppler imaging can improve the sensitivity of ultrasonography for evaluating smaller and more complex calf veins where B-mode imaging is less sensitive⁽⁹⁾. Furthermore, adequate compression is often impossible in some sites such as the distal femoral vein at the level of the adductor canal, just above the knee and in the calf. In such situations, colour Doppler can demonstrate normal blood flow, or otherwise, if the vein cannot be subjected to compression. This is especially important in post-operative DVT when most thrombi arise in the calf region and are non-occlusive.

Calf vein thrombi, which when localised are associated with little morbidity, may however extend into popliteal and femoral veins^(24, 25). In our study, there were few patients with proven isolated calf vein thrombosis (3.7%). This may be because calf vein thrombosis causes fewer symptoms and is thus less likely to present for diagnosis. Another reason is that interrogation of the posterior tibial, anterior tibial and peroneal veins in both legs is a difficult and laborious exercise, and some calf vein thrombi may be missed.

None of our patients with a normal diagnostic study developed significant sequelae of untreated DVT on follow-up (4 to 33 months). This supports the reliance on the results of duplex ultrasonography to withhold treatment if the scan is negative, especially if repeatedly so^(19, 26).

At present, duplex ultrasonography with colour Doppler imaging is probably the investigation of choice for the diagnosis of DVT provided it is performed by an experienced sonographer. It is safe, accurate, accessible, reproducible, efficient and most importantly, noninvasive. By accurately separating patients with clinically important DVT from those who are at little or no risk, it provides an excellent triaging tool for therapy. It can also distinguish DVT from other confounding conditions such as superficial thrombophlebitis or a Baker cyst which are treated differently.

Contrast venography is invasive and may be technically difficult. It requires considerable experience to perform and interpret, and may cause complications such as contrast allergy, superficial phlebitis or even DVT (in 4% of test patients). It is not suitable as a screening test.

Besides DVT diagnosis, duplex ultrasonography may also be used to determine the age of the thrombus, predict the likelihood of normalisation, and assess the natural history of the disease. The most predictive ultrasound criterion for recent thrombosis is the venous diameter^(23, 27). Venous diameter was

found to be at least twice that of the diameter of the accompanying artery when the thrombosis was less than 10 days old⁽²³⁾. Other appearances such as clot echogenicity are less reliable.

There have been few studies assessing the natural history of DVT. Recanalisation occurs predominantly in the first 6 weeks after thrombosis, and results in return of compressibility and reappearance of Doppler flow⁽²⁷⁾. The degree of recanalisation depends more on the size and extent of the thrombus than on its site. The likelihood of normalisation increases if the lesion was located in only one segment, if the pelvic veins are unaffected, if the affected leg is the left one, if the clot is nonocclusive, if there is no history of DVT, or if the symptom has been present for less than 24 hours before treatment⁽²⁸⁾.

Despite adequate treatment, a little more than half of thrombi above the knee recanalise completely⁽²⁵⁾. This is also observed in our cohort in which half the patients with proximal DVT who had repeat scans showed complete resolution while the rest showed either partial resolution or persistent occlusion. In addition to monitoring the evolution of the disease process, repeat scans within 6-12 months of the acute episode are also useful in providing a known baseline for comparison if DVT recurs.

CONCLUSION

Our study strongly supports the view that duplex ultrasonography with colour Doppler imaging is the new diagnostic modality of choice for suspected DVT in symptomatic patients. It is an accurate, objective, simple, rapid and reproducible noninvasive test for both diagnosis and follow-up of patients with DVT. When pretest clinical probability of disease is incorporated into the decision-making process, most DVT patients can be managed safely based on the result of this non-invasive test. It is an excellent substitute for conventional contrast venography.

ACKNOWLEDGEMENT

The authors wish to thank Mr Gautam Kumar, a medical student, for his valuable assistance during the successful conduct of this study.

REFERENCES

- Barnes RW, Wu KK, Hoak JC. Fallibility of the clinical diagnosis of venous thrombosis. *JAMA* 1975; 234: 605-7.
- Sullivan ED, Peter DJ, Cranley JJ. Real-time mode venous ultrasound. *J Vasc Surg* 1984; 1: 465-71.
- Appelman PT, DeJong TE, Lampmann LE. Deep venous thrombosis of the leg: US findings. *Radiology* 1987; 163: 743.
- O'Leary DH, Kane RA, Chase BM. A prospective study of the efficacy of B-scan sonography in the detection of deep venous thrombosis in the lower extremities. *J Clin Ultrasound* 1988; 16:1.
- Raghendra BN, Horii SC, Hilton S, Subramanyam BR, Rosen RJ, Lam S. Deep venous thrombosis: detection by probe compression of veins. *J Ultrasound Med* 1986; 5: 89-95.
- Dauzat MM, Laroche JP, Charras C. Real-time B-mode ultrasonography for better specificity in the noninvasive diagnosis of deep venous thrombosis. *J Ultrasound Med* 1986; 5: 625-31.
- Langsfeld M, Hershey FB, Thorpe L. Duplex B-mode imaging for the diagnosis of deep venous thrombosis. *Arch Surg* 1987; 122: 587-91.
- Cronan JJ, Dorfman GS, Scola FH, Schepps B, Alexandra J. Deep venous thrombosis. US assessment using vein compression. *Radiology* 1987; 162: 191-4.
- Killewich LA, Bedford GR, Beach KW, Strandness DE. Diagnosis of deep venous thrombosis. *Circulation* 1989; 79:810-4.
- Fletcher JP, Kershaw LZ, Barker DS, Koutts J, Varnava A. Ultrasound diagnosis of lower limb deep venous thrombosis. *Med J Aust* 1990; 153: 453-5.
- Habscheid W, Hohmann M, Wilhelm T, Epping J. Real-time ultrasound in the diagnosis of acute deep venous thrombosis of the lower extremity. *Angiology* 1990; 41: 599-608.
- Mussurakis S, Papaioannou S, Vrakatselis T. Compression ultrasonography as a reliable imaging monitor in deep venous thrombosis. *Surg Gynecol Obstet* 1990; 171: 233-9.
- George JE, Berry RE. Noninvasive detection of deep venous thrombosis. A critical evaluation. *Am Surg* 1990; 56: 76-8.
- Woolson ST, Mc Crory DW, Walter JF, Maloney WJ, Watt JM, Cahill PD. B-mode ultrasound scanning in the detection of proximal venous thrombosis after total hip replacement. *J Bone Joint Surg Am* 1990; 72: 983-7.
- Woolson ST, Pottorff G. Venous ultrasonography in the detection of proximal vein thrombosis after total knee arthroplasty. *Clin Orthop* 1991; 273: 131-5.
- Chance JF, Abbitt PL, Tegtmeier CJ, Powers RD. Real-time ultrasound for the detection of deep venous thrombosis. *Ann Emerg Med* 1991; 20: 494-6.
- Tremaine MD, Choroszy CJ, Gordon GH, Menking SA. Diagnosis of deep venous thrombosis by compression ultrasound in knee arthroplasty patients. *J Arthroplasty* 1992; 7: 187-92.
- Lensing AWA, Prandoni P, Brandjes D, Huisman PM, Vigo M, Tomasella G. Detection of deep vein thrombosis by real-time B-mode ultrasonography. *N Engl J Med* 1989; 320: 342-5.
- Heijboer H, Buller HR, Lensing AWA, Turpie AGG, Colly LP, Cate JWT. A comparison of real-time compression ultrasonography with impedance plethysmography for the diagnosis of deep vein thrombosis in symptomatic outpatients. *N Engl J Med* 1993; 329: 1365-9.
- Sumner DS, Lambeth A. Reliability of doppler ultrasound in the diagnosis of acute venous thrombosis both above and below the knee. *Am J Surg* 1979; 138: 205-10.
- Baxter GM, Duffy P, Partridge E. Colour flow imaging of calf vein thrombosis. *Clin Radiol* 1992; 46: 198-201.
- Davidson BL, Elliott CG, Lensing AW. Low accuracy of color doppler ultrasound in the detection of proximal leg vein thrombosis in asymptomatic high-risk patients. *Ann Intern Med* 1992; 117: 735-8.
- Longbloets LMM, Lensing AWA, Koopman MMW, Buller HR, Cate JW. Limitations of compression ultrasound for the detection of symptomless postoperative deep vein thrombosis. *Lancet* 1994; 343: 1142-4.
- Lagerstedt CI, Olsson CG, Fagher BO, Oqvist BW, Albrechtsson U. Need for long term anticoagulant treatment in symptomatic calf vein thrombosis. *Lancet* 1985; 2: 515-8.
- Baxter GM, Mc Kenie S, Duffy P. Colour doppler ultrasound of the post-phlebotic limb: Sounding a cautionary note. *Clin Radiol* 1991; 43: 301-4.
- Vaccaro JP, Cronan JJ, Dorfman GS. Outcome analysis of patients with normal compression ultrasound examinations. *Radiology* 1990; 175: 645-9.
- Ramshorst B, Bemmelen PS, Hoeneveld H, Faber JAJ, Eikelboom BC. Thrombus regression in deep venous thrombosis. *Circulation* 1992; 86: 414-9.
- Mantoni M. Deep venous thrombosis: longitudinal study with duplex ultrasound. *Radiology* 1991; 179: 271-3.