

# ELECTROCARDIOGRAPHIC CASE

## ELECTROCARDIOGRAPHIC CLINICAL DIAGNOSIS IN A DROWSY AND TACHYPNOEIC PATIENT

S B S Ooi

### CASE REPORT

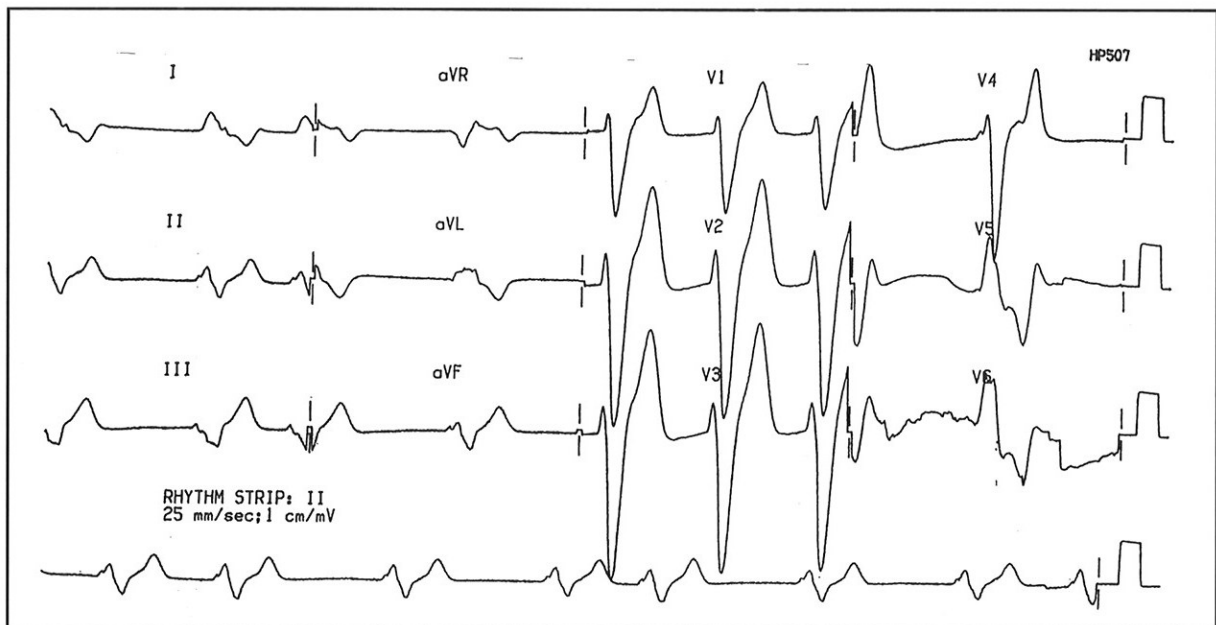
A 79-year-old Chinese lady was brought in to the Emergency Department because of drowsiness, malaise and breathlessness earlier in the morning of the day of admission. She has a history of end stage renal failure for 4 years and is on regular dialysis twice a week. She also has hypertension.

On examination, she was pale, sallow, drowsy and not communicating. Her vital signs were as follows: pulse rate 42/min, blood pressure 74/45mmHg, respiratory rate 30/min. She had deep sighing respiration. She was not in cardiac failure and there were no localising signs on neurological examination. She was immediately put on blood pressure and cardiac monitoring.

Fig 1 is the 12-lead electrocardiogram done in the Emergency Department. What is your diagnosis? (Answer on pages 690-691)

SINGAPORE MED J 1995; Vol 36: 666, 690-691

Fig 1 - Initial 12-lead electrocardiogram done in the Emergency Department



Emergency Department  
National University Hospital  
5 Lower Kent Ridge Road  
Singapore 119074

S B S Ooi, MBBS, FRCS (A&E)  
Registrar

Correspondence to : Dr Shirley Ooi