

# RADIOLOGICAL CASE

## CLINICS IN DIAGNOSTIC IMAGING (8)

C Helpert, W C G Peh, B H Lim

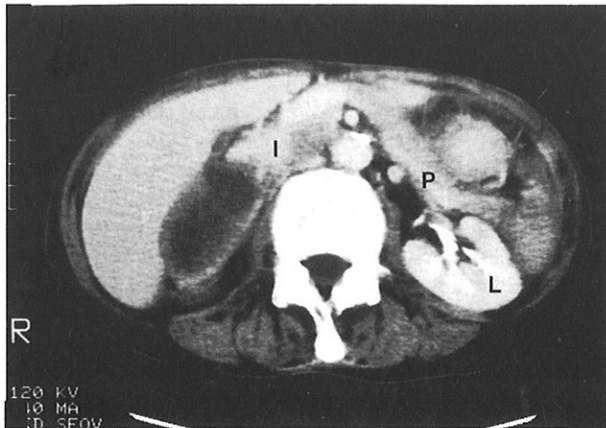
SINGAPORE MED J 1995; Vol 36: 671-673

### CASE REPORT

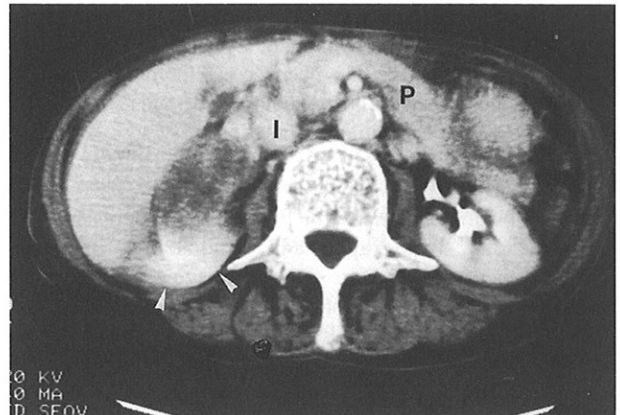
A 73-year-old woman presented with acute epigastric pain and melaena. She had a past history of peptic ulcer disease and previous left pyelolithotomy. She used to smoke cigarettes but stopped 5 years ago. Physical examination revealed pallor, blood pressure of 90/50 mm Hg and pulse rate of 100/min. Her abdomen was soft and non-tender, with the liver edge being just palpable. Melaena was found on rectal examination. Haemoglobin level was 4.8 g/dL.

The patient was resuscitated on admission and underwent an emergency endoscopy which revealed a bleeding gastric incisural ulcer as well as a duodenal ulcer. The gastric ulcer was treated endoscopically using a combination of adrenaline injection and heater probe. Ultrasound was performed later to investigate the palpable liver. The liver and kidneys were normal but a 4 cm x 8 cm oval shaped mass of mixed heterogeneity was detected between the liver, upper right renal pole and the inferior vena cava. Computerised tomography (CT) was done to better delineate this mass. What do contiguous CT scans (Fig 1 and 2) and chest radiograph (Fig 3) show? What is the diagnosis? How could the diagnosis be confirmed?

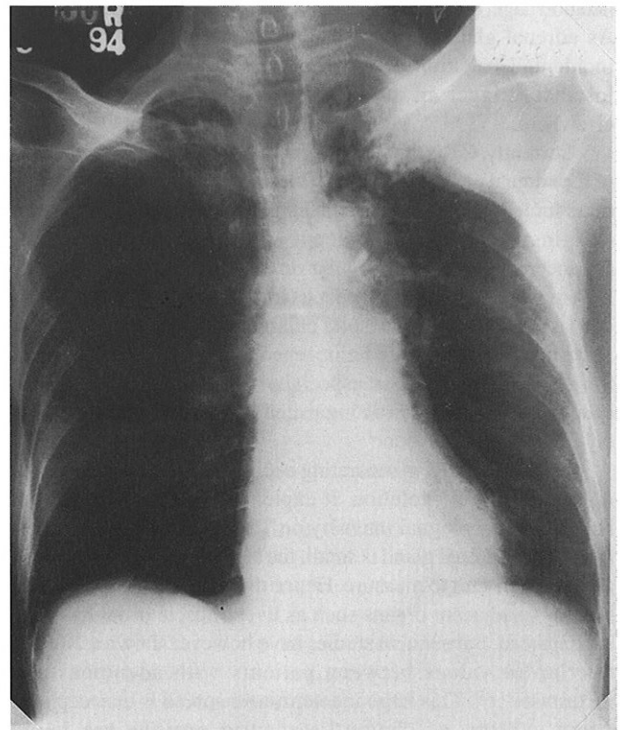
**Fig 1 – Enhanced CT at the level of the tail of pancreas [P]. Inferior vena cava [I] and left kidney [L] are marked.**



**Fig 2 – Enhanced CT at the level of the body and tail of pancreas [P] (5mm caudal to Fig 1). Inferior vena cava [I] and upper pole of the right kidney [arrowheads] are marked.**



**Fig 3 – Frontal chest radiograph.**



Department of Diagnostic Radiology  
The University of Hong Kong  
Queen Mary Hospital  
Hong Kong

C Helpert, MD  
Visiting Scholar

W C G Peh, FRCR, FHKAM, FAMS  
Senior Lecturer and Consultant

Department of Surgery  
The University of Hong Kong  
Queen Mary Hospital

B H Lim, MBChB, FRCS  
Medical Officer

Correspondence to: Dr W C G Peh

## IMAGE INTERPRETATION

CT demonstrates a well-defined, largely cystic mass with thick irregular enhancing borders (Fig 1). It abuts upon but does not invade the upper right kidney and inferior vena cava, corresponding anatomically to a right adrenal mass (Fig 2). Chest radiograph shows an opacity in the periphery of the left upper zone, with suggestion of involvement of the lateral aspects of the left second and third ribs (Fig 3). CT of the thorax confirms an irregular heterogeneously enhancing tumour in the posterior segment of the left upper lobe causing destruction of the adjacent ribs (Fig 4).

## DIAGNOSIS

### Adrenal metastasis from bronchial carcinoma

#### Clinical Course

Aspiration, under ultrasound guidance, of the right adrenal mass yielded 15 ml of light brown fluid. Cytological examination confirmed the diagnosis of a necrotic carcinoma. The patient underwent a course of palliative radiotherapy and subsequently died 7 weeks after her initial presentation.

## DISCUSSION

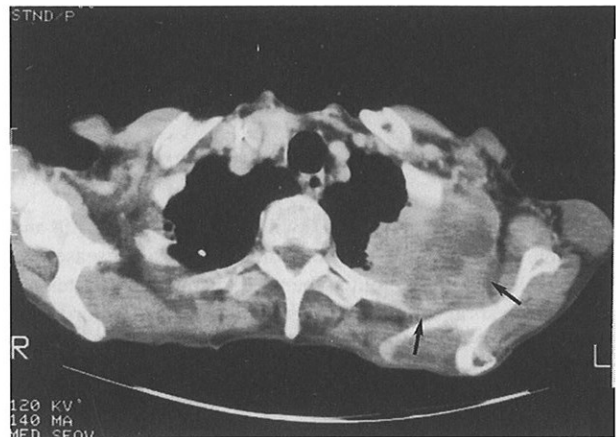Besides obviating the need for invasive procedures such as arteriography, venography and venous sampling, the development of modern cross-sectional imaging techniques has enabled accurate delineation of both normal and diseased adrenal glands<sup>(1)</sup>. Nearly all masses larger than 1 cm that deform the adrenal gland contour can be identified by CT or magnetic resonance imaging (MRI)<sup>(2)</sup>. Adrenal diseases can be divided biochemically into symptomatic (hyper- or hypo-functioning glands) or asymptomatic (normal adrenal function) categories. The differential diagnoses of asymptomatic adrenal masses include adenoma, primary adrenal carcinoma, myelolipoma, haemorrhage, cysts, metastases, lymphoma and pseudotumours<sup>(1)</sup>. As adrenal glands are a common site of metastatic disease, incidental detection of an adrenal mass should, in the first instance, trigger an intensive search for a primary tumour elsewhere.

Currently, CT is the imaging modality of choice for depiction of the adrenal gland<sup>(1)</sup>. Features which are suggestive of malignant mass include: size greater than 3cm in diameter, poorly defined margins, invasion of adjacent structures, heterogeneous enhancement and thick irregular rims. On the other hand, benign lesions tend to have homogeneous low attenuation, maintenance of gland configuration despite enlargement, thin or absent rim, sharp margins and diffuse homogeneous contrast enhancement<sup>(3)</sup>. Small adrenal metastasis, especially those smaller than 3cm in size, cannot be clearly distinguished from other benign lesions on CT appearances alone<sup>(1)</sup>.

The role of MRI in separating benign from malignant adrenal disease is still in evolution. It exploits the property of tumour having a higher signal intensity on T2-weighted sequences. As the normal adrenal gland is small, the signal from normal adrenal cortex is difficult to measure. Hence the ratio of signals from the tumour to adjacent organs such as liver, muscle or fat has been used instead. Subsequent studies have however shown a 20-30% overlap in values between patients with adenomas and metastases<sup>(1,4,5)</sup>. This large indeterminate spread is unacceptable when surgery or chemotherapeutic options are being considered<sup>(6)</sup>. MR spectroscopy is another research tool used to help distinguish between adenomas and carcinomas. Adenomas have been found to contain more lipid compared with malignant tumours<sup>(7)</sup>.

Percutaneous biopsy remains the most definitive method of confirming adrenal metastasis. Using a thin gauge Chiba needle,

**Fig 4 – CT of the upper thorax showing a large irregular mass, with heterogeneous contrast enhancement, in the left upper lobe. There is adjacent chest wall invasion and rib destruction (arrows).**



larger lesions can be biopsied easily under ultrasound control and smaller lesions with CT guidance. In the hands of experienced cytopathologists and radiologists working jointly, the overall accuracy for percutaneous adrenal biopsy is 80-100%<sup>(1,6,8)</sup>. A potentially fatal complication of adrenal biopsy is precipitation of a hypertensive crisis by an unsuspected pheochromocytoma. Screening for catecholamines in hypertensive patients is recommended prior to adrenal biopsy<sup>(1)</sup>.

Differential diagnoses of a pulmonary soft-tissue mass with adjacent rib destruction include metastases, multiple myeloma, mesothelioma and other rarer tumours, tuberculous osteitis, fungal infections and radiation osteitis<sup>(9)</sup>. The combination of such a pulmonary lesion together with a large adrenal mass, as found in our patient, is highly suggestive of advanced bronchial carcinoma.

Lung cancer is the world's commonest fatal malignancy, with about 90% of afflicted patients eventually dying from the disease. Histological subdivisions include adenocarcinoma (35%), squamous cell carcinoma (25%), small cell carcinoma (20%) and large cell undifferentiated carcinoma (15%). The 5-year survival rate is only 10-15% as most bronchogenic tumours are unresectable at the time of diagnosis. The new International Staging System for Lung Cancer was devised to resolve differences in the existing staging systems and to reflect advances in surgical therapy. The system is based on stage grouping of TNM subsets, where bronchial carcinoma survival depends on the extent of primary tumour (T), lymph node metastases (N) and the presence of distant metastases (M)<sup>(10)</sup>.

Surgical resection remains the only reliable method of curing lung cancer. However selection criteria for surgical candidates are continually evolving, paralleling advances in treatment and surgical techniques. The main role of imaging in lung cancer staging is to identify distant metastases, N3 or unresectable N2 disease and T4 lesions, hence sparing the patient unnecessary thoracotomy. In the absence of detectable distant metastases, staging proceeds to assessment of mediastinal lymph nodes and involvement of the mediastinum, chest wall and other structures by the primary tumour. CT remains the primary imaging modality used in lung cancer staging, complemented by MRI in evaluation of superior sulcus tumours and vascular, pericardial and cardiac invasion<sup>(10)</sup>.

This case illustrates the importance of considering the diagnosis of metastasis when an asymptomatic unilateral adrenal mass is incidentally detected. Where there is no extra-adrenal primary neoplasm, such an adrenal lesion smaller than 3 cm in

diameter is likely to be benign. For these lesions, follow-up with serial scans every 6 to 12 months to exclude growth, is recommended. In doubtful situations and when the result is likely to influence the patient's management, imaging-guided percutaneous biopsy of the adrenal mass can be performed<sup>(2)</sup>.

#### REFERENCES

1. Dunnick MR. Adrenal imaging: Current status. *AJR* 1990; 154:927-36.
2. Reznek RH. CT of adrenal pathology. In : Husband JE, ed. *International London Courses in Computed Tomography and MRI*, Gleneagles. 1994:41-5.
3. Berland LL, Koslin DB, Kenny PJ, Stanley RJ, Lee JY. Differentiation between small benign and malignant adrenal masses with dynamic incremented CT. *AJR* 1988;151:95-101.
4. Chang A, Glazer HS, Lee JKT, Ling D, Heiken JP. Adrenal gland : MR imaging. *Radiology* 1987;163:123-8.
5. Francis IR, Gross MD, Shapiro B, Korobkin M, Quint LE. Integrated imaging of adrenal disease. *Radiology* 1992;184:1-13.
6. Bernardino ME. Management of the asymptomatic patient with a unilateral adrenal mass. *Radiology* 1988;166:121-3.
7. Leroy-Willig A, Bittoun J, Luton JP, Louvel A, Lefevre JE, Bonnin A, et al. In vivo MR spectroscopic imaging of the adrenal glands: distinction between adenomas and carcinomas larger than 15mm based on lipid content. *AJR* 1989;153:771-3.
8. Bernardino ME, Walther MM, Phillips VM, Graham SD Jr, Sewell CW, Gedgudas-McClees K, et al. CT-guided adrenal biopsy : accuracy, safety, and indications. *AJR* 1985;144:67-9.
9. Chapman S, Nakielny R. *Aids to radiological differential diagnosis* 2nd ed. London: Balliere-Tindall, 1990:131.
10. Zwirowich CV, Muller NL. Computer tomography and magnetic resonance imaging for staging of lung cancer. In : Higgins CB, Pettersson H, eds. *Chest and Cardiac Radiology* London. Merit Communications, 1991:60-102.

#### ABSTRACT

*A 73-year-old Chinese woman was incidentally discovered having a right supra-renal mass on ultrasound. Computerised tomography (CT) demonstrated this large, mostly cystic mass, with thick enhancing rims, located within the right adrenal gland. Plain radiograph and CT showed a bronchial tumour causing destruction of the adjacent ribs. Ultrasound-guided aspiration biopsy of the right adrenal mass confirmed the diagnosis of metastasis. Imaging plays an important role in the detection of asymptomatic adrenal masses and in the staging of lung cancer.*

**Keywords:** adrenal gland, bronchial tumour, computerised tomography (CT), lung cancer, percutaneous biopsy, tumour staging.