

CASE REPORT - OCULAR ROSACEA

P H Ng, R L S Yeoh, C H Low, A S M Lim

ABSTRACT

Rosacea is an uncommon disease of the eye and facial skin. Ocular rosacea is often undiagnosed by the ophthalmologist especially when skin manifestations are not evident yet. Early diagnosis and treatment is important to decrease morbidity of this potentially blinding disease. A case of ocular rosacea in a 14-year-old Chinese girl is reported. Our patient presented with chronic non-specific keratoconjunctivitis. Only much later did the characteristic corneal and facial skin lesions appear. She responded to guttae prednisolone, oral and guttae tetracycline. This case illustrates the difficulty of early diagnosis when ocular manifestations precede those of the skin. We believe this is the first case of ocular rosacea reported in Singapore.

Keywords: ocular rosacea, undiagnosed, potentially blinding

SINGAPORE MED J 1996; Vol 37: 111-112

CASE REPORT

Miss K, a 14-year-old Chinese girl, presented with a history of itch and redness in her left eye over a period of several months.

There was no significant past ophthalmic history and she was in good health.

On initial examination, non-specific findings of conjunctival injection, superficial punctate keratopathy, marginal infiltrates, chalazia, squamous blepharitis and mild corneal vascularisation were noted and these were treated with topical antibiotics and steroids.

Miss K defaulted follow-up and only reappeared 17 months later complaining of a 1-day history of severe pain, redness and tearing in both eyes. Both corneas had neovascularisation at the classical 4 and 8 o'clock positions and nodular subepithelial elevations (Fig 1 and 2). There was bilateral squamous blepharitis and hyperaemic conjunctivae. The nasal skin was hypertrophic consistent with early rhinophyma (Fig 3 and 4). A diagnosis of rosacea keratitis was made on clinical grounds. A treatment regime of oral tetracycline 250 mg tid, oc tetracycline tid and guttae Pred mild tid was started. Within 2 weeks of therapy, there was marked relief of symptoms. Corneal vascularisation was less marked and the eyes less injected (Fig 5 and 6).

DISCUSSION

Rosacea is a disease of the eye and "blush area" of the face that is often undiagnosed by the ophthalmologist⁽¹⁾. As the pathogenesis of this disease is still unknown and there are no diagnostic features with regards to histopathology and biochemistry, diagnosis rests mainly on a constellation of clinical

signs which are largely non-specific. This problem is further compounded by the fact that 20% of patients with ocular rosacea have not yet developed skin lesions.

Ocular rosacea is described by Duke-Elder as a disease of adult life, usually starting between 20 and 30 years of age. Rosacea without ocular involvement affects women twice as often as men⁽²⁾. As yet, there is no data on the prevalence of rosacea among the races. We believe this is the first report of a patient with ocular rosacea in Singapore. Her young age of only 14 is also noteworthy.

The skin and ocular manifestations have been well described^(1,3,4). In order for rosacea to be diagnosed, skin

Fig 1 - Pre-treatment (left eye) corneal neovascularisation at 4 o'clock

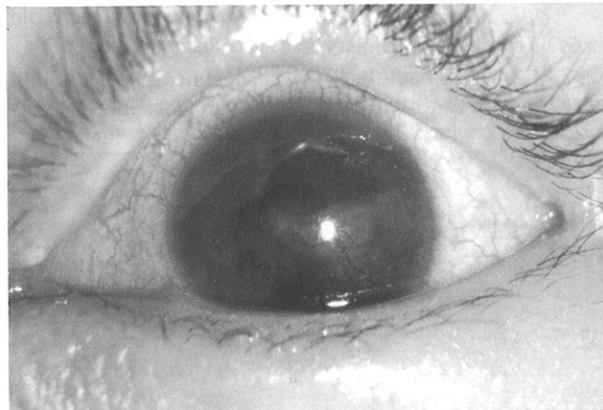
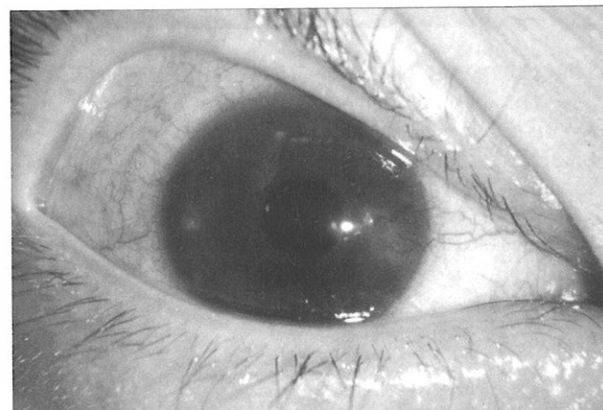


Fig 2 - Pre-treatment (right eye) corneal neovascularisation at 4 and 8 o'clock



Department of Ophthalmology
National University Hospital
5, Lower Kent Ridge Road
Singapore 119074

P H Ng, MBBS
Resident

R L S Yeoh, FRCS (Glasgow), FRCOphth
Visiting Consultant

C H Low, FRCS, FRCS (Edin), FRCS (Glasgow)
Visiting Consultant

Department of Ophthalmology
National University of Singapore
5 Lower Kent Ridge Road
Singapore 119074

A S M Lim, FRCS, FRCS (Edin), FRACS
Clinical Professor and Head

Correspondence to: Dr P H Ng

Fig 3 - Hypertrophic sebaceous glands on nose (arrowed) and cheeks pre-treatment

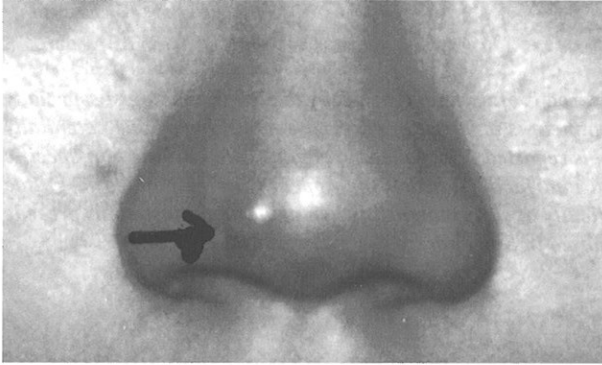


Fig 4 - Resolution of hypertrophic glands on nose post treatment

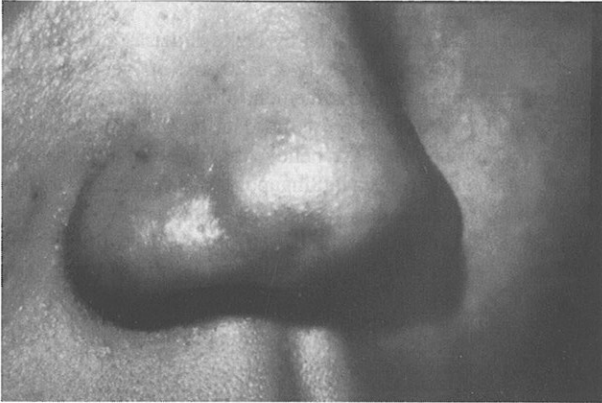
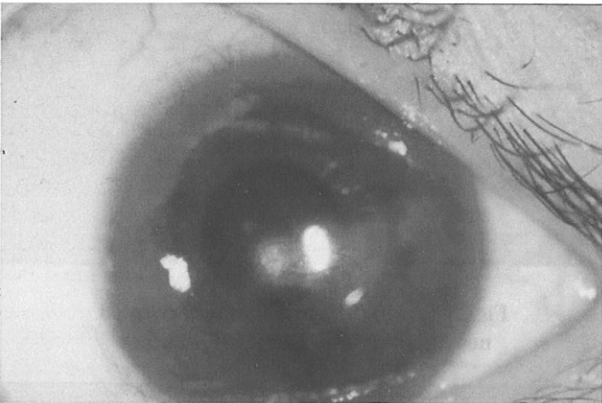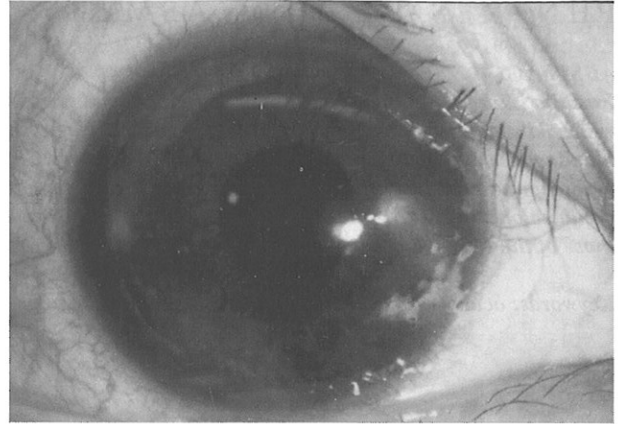


Fig 5 - Post-treatment (left eye), corneal neovascularisation and conjunctival injection less marked.



manifestations must be present. The ocular manifestations are too non-specific until keratitis occurs. This explains why delayed diagnosis is frequent as in our patient. However, as ocular rosacea is a potentially blinding condition, early diagnosis and treatment is important. Browning et al have proposed a point system for diagnosis⁽³⁾. His scheme merits consideration as there is so far no definitive biochemical or histopathological test to help confirm diagnosis.

Fig 6 - Post-treatment (right eye), reduced corneal neovascularisation



Various hypotheses of aetiology have been proposed. These range from bacterial infection, gastrointestinal disorder, disorder of vasodilation, sebaceous gland abnormalities and *Demodex folliculorum* infestation. To date none of these has been convincingly proven. Recent work by Thanh et al suggest a Type IV hypersensitivity reaction accounting for the conjunctival inflammation, but the offending antigen(s) is still unknown⁽⁵⁾. This view is based on the finding that rosacea conjunctiva has a statistically significant increase in number of T helper cells with a CD4/CD8 ratio of 1.6 compared to a ratio of 0.85 in normal conjunctiva.

Treatment of rosacea rests largely on the use of antibiotics (tetracycline, ampicillin, erythromycin and metronidazole). Tetracycline was first used to treat ocular rosacea in 1966⁽⁶⁾. Prior to this, management consisted of Vitamin B complex administration and radiotherapy to the cornea⁽⁴⁾. Oral tetracycline has been effective in the treatment of all the ocular lesions of rosacea. The mechanism of action of tetracycline is unknown. Recent work on doxycycline has shown promise⁽⁷⁾. Topical steroids are useful in the management of iritis, keratitis and episcleritis until tetracycline takes effect.

CONCLUSION

The pathogenesis of rosacea is still an enigma and when ocular manifestation precedes those of the skin, a high index of suspicion is required for early diagnosis.

REFERENCES

1. Duke-Elder S. System of ophthalmology - Diseases of the outer eye. Britain: Henry Kimpton. 1965; Vol. VIII:534-46.
2. Borrie P. Rosacea with a special reference to its ocular manifestations. *Br J Dermatol* 1953; 6: 458-63.
3. Browning DJ, Proia AD. Ocular rosacea - Review. *Surv Ophthalmol* 1986;3:145-58.
4. Goldsmith AJB. The ocular manifestations of rosacea. *Br J Dermatol* 1953;65:449-57.
5. Thanh HX, Rodriguez A, Zaltas MM, Rice BA, Foster S. Ocular rosacea - A histologic and immunopathologic study. *Ophthalmology* 1990;97:1468-75.
6. Sneddon IB. A clinical trial of tetracycline in rosacea. *Br J Dermatol* 1966;78:649-52.
7. Frucht-Pery J, Chayet AS, Feldman ST, Lin S, Brown SI. The effect of doxycycline on ocular rosacea. *Am J Ophthalmol* 1989;107:434-5.