

RUPTURED PHAEOCHROMOCYTOMA - A RARE DIFFERENTIAL DIAGNOSIS OF ACUTE ABDOMEN

K L Ong, T H Tan

ABSTRACT

Ruptured phaeochromocytoma may mimic other cause of acute abdomen and though it is rare, it must be remembered as a possible differential; clinical suspicion should be increased when there is lability in blood pressure. We report a patient whose presentation closely resembles that of a leaking aortic aneurysm. The ultrasound performed was non conclusive and was followed by a computerised axial tomography which showed a retroperitoneal mass. A laparotomy was performed and histology of the mass revealed a haemorrhagic phaeochromocytoma. A computerised axial tomography is a useful investigation to distinguish it from other causes of acute abdomen and in particular a leaking aortic aneurysm.

Keywords: *phaeochromocytoma, labile blood pressure, acute abdomen, high index of suspicion, computerised axial tomography*

SINGAPORE MED J 1996; Vol 37: 113-114

CASE REPORT

An 80-year-old Chinese male presented to our Accident and Emergency Department with a history of sudden onset of severe abdominal pain that radiated to the back for one day. The pain was continuous and the patient was still in severe pain at presentation to our department. It was accompanied by 2 bouts of vomiting. There was no history of trauma, no previous history of documented hypertension or any other constitutional symptoms.

On examination, he was sweaty and his blood pressure was high on the initial 2 readings (242/127 mmHg and 212/112 mmHg). The blood pressure lowered spontaneously, without treatment, to 124/70 mmHg in the Emergency Department. Abdominal examination revealed tenderness over the epigastrium and a mass over the left upper quadrant. It was not pulsatile and there was no bruit heard. All peripheral pulses were palpable and equal and the rate was 90 per minute.

Initial blood investigations in the Emergency Department included the haemoglobin level, blood glucose and amylase level. An electrocardiogram and radiographic examination of the chest and abdomen were done. Results of investigations were: haemoglobin concentration 14.8 g/dL (finger prick using Haemocue machine), blood glucose 11.5 mmol/L, serum amylase 11.32 IU/L. After admission, the complete blood picture done showed the white cell count to be raised: $13.8 \times 10^9/L$.

The electrocardiogram and chest radiograph were normal. However the abdominal radiograph showed loops of dilated bowel on the left side with loss of psoas shadows.

Initial working diagnoses made in the Emergency Department included abdominal aortic aneurysm, carcinoma of the colon and pancreatic tumour. The surgeon was consulted after the initial assessment and stabilisation. Treatment in the

Emergency Department included administration of oxygen, setting up intravenous line with administration of crystalloids and sending blood for group and cross matching.

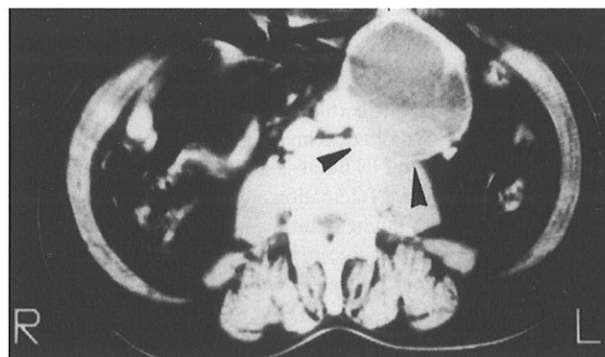
An ultrasound of the abdomen was done after admission to the surgical ward and it showed a mass arising immediately to the left of the aortic bifurcation. The mass was partly cystic, partly solid and there was suggestion that at one point, the mass communicated with the lower aorta. The differential diagnosis was a saccular aneurysm or mycotic aneurysm. An urgent CT scan with contrast was performed soon after the ultrasound. The findings revealed a large thick-walled cyst with blood-fluid content in the retroperitoneal space (Fig 1). The aorta was normal in calibre. The mass was not in continuity with the aorta, left kidney or pancreas. A radiological diagnosis of retroperitoneal bleeding or mesentery cyst was made.

The patient remained haemodynamically stable and his blood pressure was not raised (120/70 mmHg) and he did not experience any episode of severe abdominal pain while in the surgical ward. Laparotomy was performed at which a 9 cm hard cyst arising from the mesentery of the upper small bowel was found. It was adherent to the duodenal-jejunal flexure, to the ureter along the left lateral wall and also to the aorta posteriorly.

Histology showed the tumour to be a phaeochromocytoma which had undergone cystic degeneration and that 90% of the tumour was occupied by altered blood. The paraaortic lymph node removed appeared normal both in size and morphology and was free from tumour microscopically.

Post-operatively, the patient's blood pressure remained normal and his recovery was uneventful. An ^{131}I -metaiodobenzylguanidine (^{131}I MIBG) scan was performed to

Fig 1 - CT scan of the abdomen. A large thick-walled cystic lesion with blood-fluid content in the retroperitoneal space.



Department of Accident and Emergency
Prince of Wales Hospital
Shatin
New Territories
Hong Kong

K L Ong, MBBS, FRCS (A&E) Edinburgh
Senior Medical Officer

Department of Diagnostic Radiology
Prince of Wales Hospital

T H Tan, MBBS, FRCR
Senior Medical Officer

Correspondence to: Dr K L Ong

locate the presence of phaeochromocytoma and its metastases elsewhere. The result was negative.

DISCUSSION

The classical clinical manifestation of phaeochromocytoma is hypertension, either persistent or paroxysmal (15%). Phaeochromocytoma occurs in 0.1% to 0.5% of hypertensive patients. Sometimes, abdominal pain can be a significant feature^(1,2). Other symptoms include orthostatic hypotension, pallor, headache and nausea. Rupture of a phaeochromocytoma presenting as an acute abdominal emergency is rare.

Ninety percent of phaeochromocytomas arise in the adrenals and 10% in the extra-adrenal areas. The extra-adrenal tumour may arise anywhere in the sympathetic system from the neck to the pelvis but the most common sites are the paraaortic region and the organ of Zuckerkandl. The malignancy rate is generally accepted to be 10% with metastases commonly to lymph nodes, lung, liver and skeletal system⁽³⁾.

Small areas of haemorrhage commonly occur in phaeochromocytoma. On the other hand, haemorrhagic necrosis severe enough to manifest as acute abdomen is unusual. This tends to occur in the larger tumours and has been noted to be precipitated by phenothiazines⁽²⁾ and administration of anticoagulants^(2,4,5). A large proportion of patients experience severe, constant abdominal or loin pain frequently associated with vomiting⁽⁶⁾. Clinical findings may include features of intense sympathetic stimulation - sweating, tachycardia, hypertension, and peripheral vasoconstriction. In addition, a mass may sometimes be palpable. Clinical diagnosis of this condition can be difficult, especially when there is no previous history of phaeochromocytoma. Differential diagnoses would include leaking aortic aneurysm, acute pancreatitis, mesenteric infarction and cholecystitis.

Laboratory investigations for the acute diagnosis are non-specific and therefore not helpful. A haemoglobin level is helpful to look for anaemia secondary to significant bleeding, for example in a leaking aneurysm, and in our patient, the haemoglobin level done in the Accident and Emergency Department was normal. Other abnormalities include leucocytosis and mild hyperglycaemia⁽⁶⁾.

When using ultrasound and computerised axial tomography to identify masses in the adrenal and para-renal region, there are no specific features to identify phaeochromocytoma from other tumours or tumour metastases. However to distinguish it from a leaking aortic aneurysm, a computerised axial tomography of the abdomen is an invaluable technique. Ultrasound, although a useful radiological investigation in the hands of an experienced operator, is generally considered to be less specific. Frequently, patients with leaking aortic aneurysms have secondary ileus and the loops of gas filled bowels make interpretation difficult. Computerised axial tomography has the advantage of demonstrating cross-sectional images and therefore enables the appreciation of relationship of the mass to the aorta and other structures. In the case of our patient the ultrasound result was non-conclusive. Further investigation was needed with CT which showed it to be either a retroperitoneal or mesentery cyst. Furthermore, the mode of presentation as an acute abdomen meant that rupture may require immediate surgery⁽⁷⁾ without the opportunity for any radiological investigation. One may be alerted to this possible diagnosis by the absence of shock or, alternatively, by the presence of great fluctuations of blood pressure.

Other adjunctive studies that are useful for diagnosis and localisation include ¹³¹Iodine-metaiodobenzylguanidine (¹³¹I -

MIBG), arteriography and catecholamine assay from venous sampling of the vena cava⁽⁸⁾. ¹³¹I - MIBG scanning is a technique using a radiolabelled analogue of guanethidine that specifically accumulates in phaeochromocytomas and to a lesser degree in neuroendocrine tumours. It has a similar sensitivity to CT for localising extra-adrenal phaeochromocytomas in the retroperitoneum. However, the advantage of this technique is the ability for whole body imaging which allows for evaluation of a wide range of potential extra-adrenal locations with a single study⁽⁸⁾.

Elective surgical resection with pharmacological control carries a low mortality rate but the risk is markedly increased in an undiagnosed patient undergoing surgical procedures of any kind. From a total of 50 cases reported from 1961 to 1984 by Sellevold et al, the mortality of phaeochromocytoma diagnosed during the perioperative period is 80%⁽⁹⁾. As in this patient, reported cases of successful resection of phaeochromocytoma with haemorrhagic necrosis have been described⁽¹⁰⁻¹²⁾.

In the acute presentation of ruptured phaeochromocytoma, clinical diagnosis is difficult and a high index of suspicion is needed. Very often in the presence of abdominal pain and abdominal mass, one tends to only consider the classical differential diagnoses (as in this patient) and therefore this diagnosis is missed. This is not surprising as the presentation is rather non specific. However one could be alerted to this diagnosis by the lability of blood pressure or to the fact that an unexpectedly small volume of colloid is needed to resuscitate an apparently shocked patient⁽⁷⁾. In our patient, there was only transient fluctuation of blood pressure in the Emergency Department which made clinical diagnosis extremely difficult, and in the absence of any other significant findings, the radiological diagnosis could not be conclusive.

REFERENCES

1. Grossman E, Knecht A, Holtzman E, Nussinovich N, Rosenthal T. Uncommon presentation of phaeochromocytoma: case studies. *Angiology* 1985;36:759-65.
2. Manager WH, Gifford RW Jr. *Phaeochromocytoma*. Berlin:Springer-Verlag, 1977.
3. Sutton D. ed. The adrenal glands. In: A textbook of radiology and imaging. Churchill Livingstone, 1993:1023-45.
4. Jelliffe RS. Phaeochromocytoma presenting as a cardiac and abdominal catastrophe. *Br Med J* 1952;ii:76-7.
5. McAlister WH, Koehler PR. Haemorrhage into a phaeochromocytoma in a patient on anticoagulants. *J Can Assoc Radiol* 1967;18:404-5.
6. Jones DJ, Durning P. Phaeochromocytoma presenting as an acute abdomen: report of two cases. *Br Med J* 1985;291:1267-8.
7. Forty J, Dale RF. Ruptured phaeochromocytoma: a case report. *J R Coll Surg Edin* 1989;34:109-1.
8. Goldfarb DA, Novick AC, Bravo EL, Straffon RA, Montie JE, Kay R. Experience with extra-adrenal phaeochromocytoma. *J Urol* 1989;142:931-6.
9. Sellevold OFM, Raeder J, Stenseth R. Undiagnosed phaeochromocytoma in the perioperative period. Case reports. *Acta Anaesthesiol Scand* 1985;29:474-9.
10. Huston JR, Steward WRC. Haemorrhagic phaeochromocytoma with shock and abdominal pain. *Am J Med* 1965;39:502-4.
11. Ejerblad S, Hemmingsson A. Haemorrhage into a phaeochromocytoma in an anti-coagulant treated patient. *Acta Chir Scand* 1981;147:497-500.
12. Nicholls K. Massive adrenal haemorrhage complicating adrenal neoplasm. *Med J Aust* 1979;ii:560-2.