

USEFULNESS OF CONVENTIONAL ULTRASONOGRAPHY IN IDENTIFYING NORMAL AND ABNORMAL GASTRIC ANTRUM

J George

ABSTRACT

Aim: This study evaluates the usefulness of measuring gastric antral thickness on conventional ultrasonography as a means of suggesting gastric antral pathology. Normal and abnormal appearances of the gastric antrum are reviewed.

Method: The control group consisted of 156 patients with a mean age of 43 years (SD 11 years). The control group represented a population with no history or physical findings to suggest possible gastric pathology. The true positives represented six patients with proven gastric antral carcinoma on presentation.

Results: The mean value of the greatest thickness of one wall of the gastric antrum in the control group was 5.5mm (SD 1.9mm). The 95% confidence interval was 5.2 - 5.8mm. The normal range was 1.3 - 10mm. This was compared with 6 patients with proven gastric antral carcinoma who presented at the same time-frame of 4 months in which the control study was performed. The mean value of the thickness of the gastric antrum in these patients was 17.7mm (SD 1.9mm). The p-value on two-tailed t-test comparison between the two groups was 0.0009 which is statistically significant. This finding is in keeping with the fact that at presentation most gastric antral carcinomas are advanced.

Conclusion: This study recommends that patients with epigastric pain (gallbladder vs peptic ulcer disease), hypochromic microcytic anaemia, marked weight loss and unknown primary malignancy would benefit from ultrasonography of the gastric antrum at the time of abdominal scan. If the measurement of one wall of the gastric antrum is more than 10mm and particularly if this is associated with an abnormal echo, the patient should be endoscoped fairly urgently.

Keywords: ultrasonography gastric antrum, gastric antral carcinoma - ultrasonography, ultrasonography gastric carcinoma

SINGAPORE MED J 1996; Vol 37: 181-183

INTRODUCTION

Conventional studies on ultrasonographic appearances of normal and abnormal stomach are well described. One good study is that of Derchi et al⁽¹⁾. In this study the normal thickness of the gastric antrum under the left lobe of the liver measured between 2-5mm (hypochoic outer muscularis propria alone). Endoscopic ultrasonography reveals that the stomach consists of five echogenically distinct layers. Conventional studies with a 3.5 MHz transducer usually discriminate 2 layers ie an inner hyperechoic layer and an outer hypochoic layer. The appearance of the stomach when abnormalities such as carcinoma of the stomach and lymphoma are present have also been described on endoscopic evaluation⁽²⁾ and *in vitro* abdominal ultrasound⁽³⁾.

This study differs from that of Derchi et al⁽¹⁾ in that the control group is larger and the mean age of the patients is nearer the peak age of incidence of gastric carcinoma ie 50-60 years. The measurements of the latter study were taken beneath the left lobe of the liver which corresponds with the distal end of the antrum, but this study concentrated on the middle and proximal end of the antrum to take into account possible spread of carcinoma from the body to the antrum. This would increase the sensitivity of the study. The hypothesis proposed is that since carcinoma of the stomach is mostly advanced at the time of presentation the measurements of the abnormal gastric antral thickness should differ significantly from that of the normal gastric antrum and that the abnormal gastric antrum should show an alteration from normal echogenicity.

MATERIAL AND METHOD

A protocol sheet was first prepared including the age, sex, height, weight and previous history of peptic ulcer, carcinoma, lymphoma or any other stomach disorder. This protocol was used to identify a group of patients who had no history to suggest possible stomach pathology. One hundred and fifty-six such patients were identified and scanned over a period of 4 months. They comprised 65 men and 91 women. The mean age of all the patients was 43 years (SD 11 years). The age range of the patients was 20 to 80 years.

Six patients with proven antral carcinoma on gastroscopy underwent ultrasound examination. Five of these were Chinese, aged between 50-60 years, with chronic epigastric symptoms for at least 1 month prior to presentation.

One of these patients had an unknown primary with no gastric symptoms. Endoscopy was recommended after abdominal ultrasound scan because the gastric antrum appeared abnormal using the criterion that the gastric antrum was more than 10mm in thickness (one wall) with loss of normal echogenicity. Endoscopy revealed poorly differentiated adenocarcinoma of the stomach. A longitudinal upper abdominal scan using the proximal superior mesenteric vein as a reference point was performed on the above patients. In this plane the proximal part of the gastric antrum is mostly measured. The proximal portion of the gastric antrum lies just under the anterior abdominal wall in most patients, making it accessible to conventional ultrasonography. The normal gastric antrum has a concentric appearance (Fig 1) at this reference point.

Measurement of the thickest wall of this concentric antrum was taken. This was primarily done in patients who had fasted a minimum of four hours and who often had just a tiny amount of fluid in the gastric antrum that separated the anterior and posterior walls of the gastric antrum.

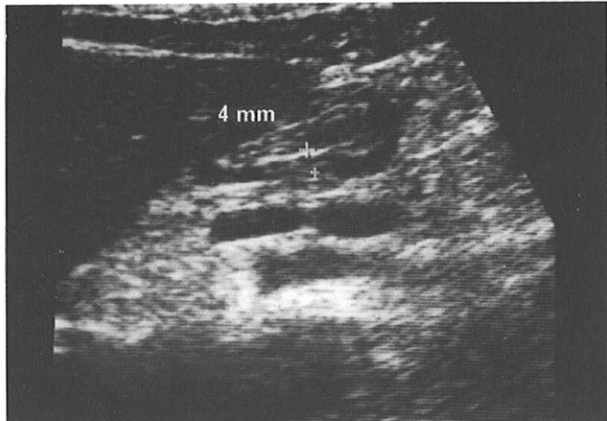
RESULTS

The results showed that the thickness of normal gastric antral

Department of Radiology
University Hospital
59100 Kuala Lumpur
Malaysia

J George, MBBS (Adel), DMRD (Aberdeen), FRCR (UK)

Fig 1 – This figure shows a concentric oval appearance of gastric antrum above the superior mesenteric vein on this midline longitudinal section. Notice the inner hyperechoic rim and the outer hypoechoic rim. A small amount of fluid separates the anterior and posterior wall. Measurement of the posterior wall here is 4mm.



wall using conventional ultrasonography was 5.3mm (SD 1.9mm). The 95% confidence interval was 5.2 - 5.8mm in this group. The normal range was 1.3 - 10mm. Routine ultrasound of the gastric antrum revealed that only 2 layers of the gastric antrum could be distinguished with ease in a fasting patient despite the fact that *in vitro* studies revealed five echogenically distinguishable layers^(2,3). This is in keeping with earlier conventional studies⁽¹⁾. The inner hyperechoic layer represents the combination of interface echo, mucosa, muscularis mucosa, submucosa and the interface between submucosa and muscularis propria.

The outer hypoechoic layer represents the muscularis propria (Fig 1 & 2). It should be noted however, that when ascites is present and fluid surrounds the gastric antrum, an additional outer third layer which is hyperechoic may also be identified which is thought to be the serosal layer and an interface echo⁽⁴⁾ (Fig 3).

This layer is not normally seen as it blends with the surrounding hyperechoic fat around the stomach. It is interesting that with newer high definition imaging ultrasounds recently

Fig 2 - This figure shows a more rounded concentric gastric antrum. Note again the inner hyperechoic and outer hypoechoic layers. This inner layer represents the mucosa and submucosa and the outer layer, the muscularis propria.

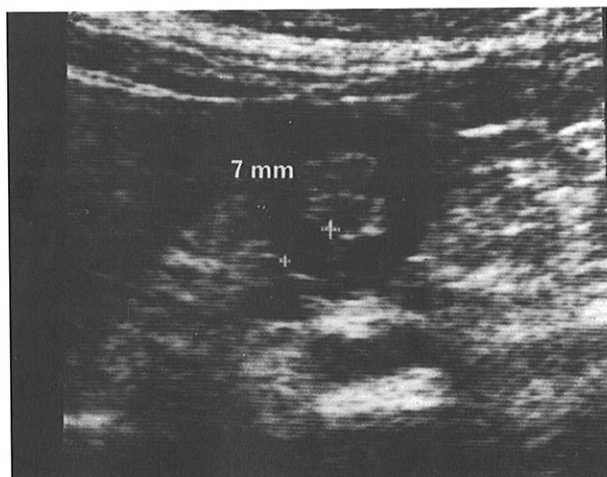
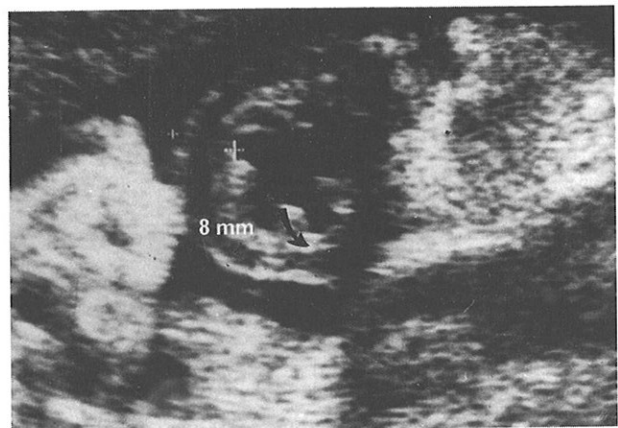

Fig 3 - When ascites surrounds the gastric antrum, three echogenically distinct layers are seen. The innermost hyperechoic layer is the mucosa and submucosa (curved arrow). The next layer is the hypoechoic muscularis propria and the outermost third layer formed by serosa and interface echo. Distance between crosses that is right lateral aspect of gastric antrum was measured at 8mm.



introduced to the market that the five layers seen on endoscopic ultrasound can sometimes be identified but the criterion for suggesting abnormality remains the same as it is based on abnormal thickness of the gastric antrum.

In the six patients who had known gastric antral carcinoma, the mean of the greatest thickness of one wall of the abnormal gastric antrum was 17.8 mm (SD 2.3mm).

Applying a two - tailed t - test to the two groups revealed a p - value of 0.0009 which is highly significant. All patients with gastric tumours showed an abnormal echo pattern of the gastric mucosa apart from increased thickness.

DISCUSSION

In a recent study in Japan⁽⁵⁾ of 250 cases of proven gastric carcinoma, 193 cases (77%) had advanced carcinoma and computed tomography scans showed that 95% of these patients had thickened walls discernable on CT scanning.

In a recent personal study of gastric carcinoma operated on in Singapore⁽⁶⁾ a surgeon reported that of 150 cases of carcinoma he operated on, 117 (78%) cases involved the antrum and 33 cases the cardia. The conclusion that can be obtained from the two studies cited^(5,6) suggests that gastric carcinoma is often advanced on presentation and that the antrum and body are the most common sites involved. Many studies have looked at the appearance of carcinoma of the stomach *in vivo* and *in vitro*⁽⁴⁾, endoscopic ultrasound⁽²⁾ and intraoperatively⁽⁷⁾.

The conventional appearance of the gastric antrum in our study did not reveal all the five layers of the stomach seen in the endoscopic studies. Endoscopic ultrasonography shows the first (mucosal) layer, the third (submucosal) layer and the fifth (serosal and interface echo) as hyperechoic. The second (muscularis mucosae) and fourth layer (muscularis propria) are hypoechoic. Therefore conventional ultrasound distinguishes the first innermost hyperechoic layer (mucosal and interface echo) and the third hyperechoic submucosal layer and also reveals the fourth hypoechoic layer (muscularis propria).

The fifth hyperechoic interface echo noted *in vitro* is not seen as this blends in with the surrounding hyperechoic fat. However, when ascites is present, conventional ultrasonography does show a distinct third layer that is the hyperechoic layer consisting of the serosal fat and interface echo (Fig 3).

In five out of the six patients with known carcinoma in our

Fig 4 - There is a protruding tumour (open arrow) into the gastric lumen. Distance between the tips of the black arrows was 17mm which is above the normal upper limit of 10mm. This protrusion of tumour was noted endoscopically.

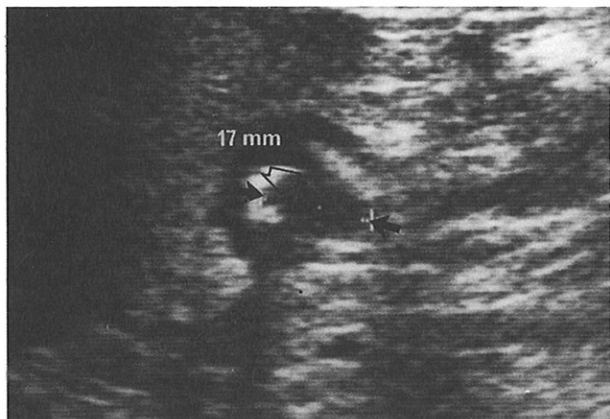


Fig 5 - There is marked abnormal thickening and echogenicity of the gastric antrum. The posterior wall, especially, is very thick (18mm) and is completely hyperechoic. The muscularis propria (outer hypoechoic layer) is replaced by echogenic tumour tissue.

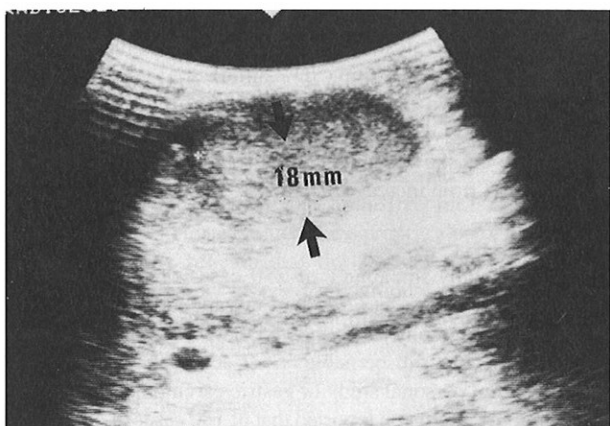
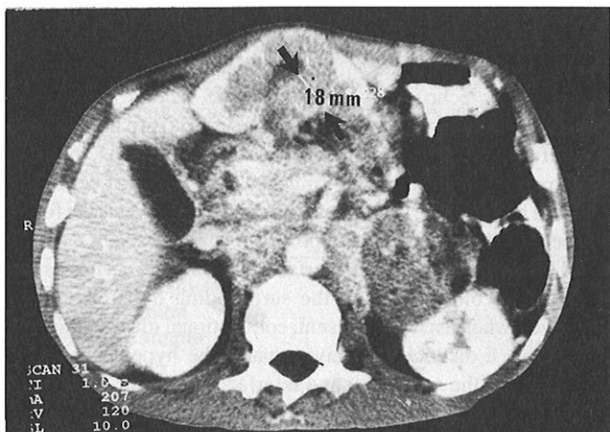


Fig 6 - This is a CT scan of the patient in Fig 5. Note the anterior position of the gastric antrum that makes it readily accessible to conventional ultrasonography. The measurement of the posterior wall corresponds with the ultrasound findings. Note that the superior mesenteric vessels lie in the longitudinal plane of the gastric antrum.



study, all or part of the hypoechoic muscularis propria (layer 4) of the gastric antrum was replaced with hyperechoic tumour tissue (Fig 5). A corresponding CT scan of the tumour in Fig 5 is shown in Fig 6. Note the anterior position of the gastric antrum. Fig 4 shows localised gastric carcinoma affecting all layers as hypoechoic mass. Protrusion of tumour into the lumen is noted. Fig 5 show a large tumour which is infiltrating the mucosa in both a vertical and longitudinal direction on ultrasound scan. Note the loss of the normal concentric appearance. The corresponding computed tomography scan (Fig 6) shows that the proximal region of the gastric antrum lies in the same plane as the superior mesenteric vein and just under the anterior abdominal wall, making it suitable for conventional ultrasonography. This demonstrates well the reason for choosing the site of the superior of the mesenteric vein as the reference point on the longitudinal scan.

CONCLUSION

This study suggests that measurements of the gastric antrum should be taken as part of routine abdominal ultrasound examination, especially when gastric carcinoma is suspected. Patients with chronic epigastric symptoms, especially in the Chinese community, aged 50 and above, should have the gastric antral measurements taken. If this measurement exceeds 15mm and has a corresponding abnormal echogenicity, the patient should have urgent endoscopy and biopsy. A submucosal biopsy should be performed if the mucosa of the antrum appears normal on endoscopy but ultrasound reveals abnormality as the tumour may be present submucosally as sometimes seen in scirrhus carcinoma of the stomach. Ultrasonography also serves as a guide to the best site for biopsy, especially when the thickening is localised to one wall.

Considerable interest should now lie in detecting earlier thickening of the gastric antrum 11-14mm with or without abnormal echogenicity. This could suggest edema of adjacent ulcer or earlier infiltrative change of the gastric antrum respectively. Earlier detection of gastric carcinoma could improve the stage of the cancer in some patients and therefore their 5-year survival.

REFERENCES

1. Derchi LE, Biggie E, Neumaler CE, Cicio, GR. Ultrasonographic appearances of gastric cancer. *Br J Radiol* 1983; 56(666): 365-70.
2. Bolondi L, Casanova P, Caletti GC, Grigioni W, Zani L, Barbara L. Primary gastric lymphoma versus gastric carcinoma: Endoscopic US evaluation. *Radiology* 1987; 165: 821-6.
3. Bolondi L, Casanova P, Santi V, Caletti G, Barbara L, Giuseppe L. The sonographic appearance of the normal gastric wall: an *in vitro* study. *Ultrasound Med Biol* 1986; 12: 991-8.
4. Lim JH, Jeong YM. Sonography of the stomach: An *in vitro* study to determine the anatomic cause of inner hyperechoic and outer hypoechoic rim of the gastric wall: *AJR* 1994; 162: 335-8.
5. Hori S, Tsuda K, Murayama S, Matsushita M, Yukawa K, Kosuka T. CT of gastric carcinoma: preliminary results with new technique. *Radiographics* 1992; 12: 257-68.
6. Ti TK. Pattern and surgical treatment for gastric cancer in Singapore. *Br J Surg* 1993; 80: 886-9.
7. Machi J, Takeda J, Sigel B, Kakegawa T. Normal stomach wall and gastric cancer: Evaluation with high-resolution operative US *Radiology* 1986; 159: 85-7.