

# MELIOIDOSIS PRESENTING WITH ORBITAL CELLULITIS

P K Wong, P H Ng

## ABSTRACT

*Melioidosis is known to present with many diverse manifestations but orbital cellulitis from melioidosis has never been described. We report a case of melioidosis in a 42-year-old diabetic male who presented with orbital cellulitis. He succumbed to recurrent empyema of the paranasal sinuses, rupture of an intracranial mycotic aneurysm and pulmonary empyema despite early antibiotic treatment.*

**Keywords:** melioidosis, orbital cellulitis, sinusitis

SINGAPORE MED J 1996; Vol 37: 220-221

## INTRODUCTION

Melioidosis affects many tissues and organs, giving rise to diverse clinical manifestations. The manifestations reported are quite varied, ranging from pulmonary lesions, osteomyelitis, abscesses in liver, kidney, spleen, pericardium and parapharyngeal space, skin abscesses, panophthalmitis to fatal septicaemia<sup>(1)</sup>. However, melioidosis involving the orbit has not been reported so far in the literature. We describe a patient who presented with orbital cellulitis from melioidosis.

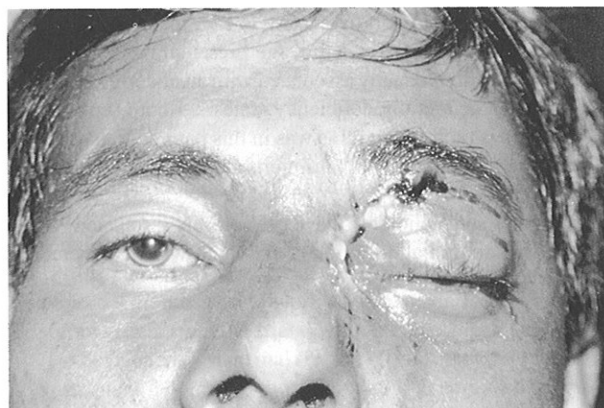## CASE REPORT

A 42-year-old previously healthy male forklift driver presented to the Medical Unit with high fever and left-sided headache of one week's duration. There was no significant past medical history of note. Initial examination did not reveal any focal signs of infection. A provisional diagnosis of cerebral abscess was made. Preliminary investigations showed leucocytosis with neutrophilia. Chest X-ray, cerebrospinal fluid studies and CT scan of the brain were normal. He was however found to be diabetic.

Intravenous ceftriaxone was started on day 1 pending blood culture results. There was no clinical response and the patient complained of blurred vision and drooping of the left upper eye lid from day 3. The fever remained unabated at 39°C. He was referred to the Eye Department on day 5. Visual acuity was 6/9 in the right eye and 6/36 which improved to 6/6 with pinhole in the left eye.

Clinically, the patient was toxic. There was a left complete ptosis with gross 4 mm left proptosis (Fig 1). The orbit was tense and tender to palpation. The eye was chemosed, injected as well as divergent and hypotropic with total ophthalmoplegia (Fig 2). Both pupils were equal and reactive with no left relative afferent pupillary defect. The optic disc was not swollen and the retinal

**Fig 1 – Complete left ptosis and lid swelling. Beads of pus are seen exuding from the lateral rhinotomy incision.**



vessels were not congested. The left intraocular pressure was raised at 34 mmHg.

Urgent CT scan of orbits and paranasal sinuses showed left acute ethmoiditis, left frontal sinus empyema, left preseptal abscess and right ethmoiditis. There was no orbital abscess but the intraorbital tissues appeared congested. A lateral rhinotomy, ethmoidectomy and drainage of the frontal sinus empyema and preseptal abscess was performed the same day. Specimens from nasal swabs and pus from sinuses grew *Pseudomonas pseudomallei*. The same organism was isolated from blood culture and was found to be sensitive to amoxicillin-clavulanic acid, ampicillin-sulbactam, piperacillin, ceftazidime, ceftriaxone, chloramphenicol and tetracycline. It was resistant to ampicillin, cephalixin, cefuroxime and gentamicin.

The patient was then switched to intravenous ceftazidime and chloramphenicol. He was also put on timolol eye drops and oral acetazolamide 250 mg twice daily and this lowered his left intraocular pressure satisfactorily. A repeat drainage of the frontal sinus was required due to recurrent empyema. Intravenous imipenam was added. He subsequently suffered a massive right frontal lobe haematoma from a ruptured mycotic aneurysm on day 12. Although the haematoma was evacuated, he became decerebrate. He was eventually cured of melioidosis; blood cultures were negative from day 19.

However, the illness was also complicated by pulmonary empyema and pneumonia from *Klebsiella* and *Pseudomonas aeruginosa*. He finally expired after 60 days of illness without regaining consciousness.

## DISCUSSION

Melioidosis is a severe infection first described in 1911 by Whitmore in Rangoon<sup>(2)</sup>. It is caused by *Pseudomonas*

---

Department of Ophthalmology  
National University Hospital  
5 Lower Kent Ridge Road  
Singapore 119074

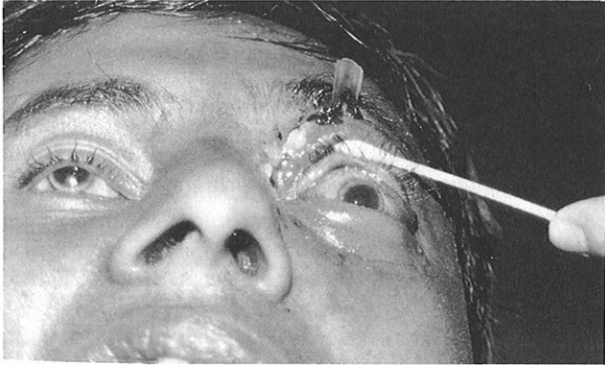
P K Wong, FRCS (Edin), FRCOphth (London), M Med (Ophth)  
Senior Registrar

P H Ng, MBBS  
Resident

**Correspondence to:** Dr P K Wong  
Department of Ophthalmology  
Faculty of Medicine  
University of Malaya  
Lembah Pantai  
59100 Kuala Lumpur  
Malaysia

---

**Fig 2 – Postoperative appearance with residual left proptosis and chemosis. The left eye is still divergent and hypotropic**



*pseudomallei*, an inhabitant of soil and water in the tropics and is endemic in South East Asia<sup>(3,4)</sup>. It can present with acute, subacute, chronic suppurative, latent or asymptomatic form and the outcome is closely related to the presentation<sup>(5)</sup>. The acute septicaemic form is usually associated with an underlying disease like diabetes or immunodeficiency states<sup>(6)</sup>. Acute septicaemic melioidosis is rapidly fatal<sup>(5)</sup> as was in this patient. Fatality rates even with the availability of antimicrobial agents are reported at 50% - 75%<sup>(7)</sup>.

Diabetes and melioidosis have been closely associated<sup>(1)</sup>. This patient was an undiagnosed diabetic which was discovered on

admission. The orbit was secondarily involved from contiguous spread from the paranasal sinuses which were heavily involved. To our knowledge, there has been no previous report of sinusitis and orbital cellulitis from melioidosis. Mycotic aneurysm from melioidosis has also not been reported before. It is likely that severe vasculitis in the region of the frontal sinus and frontal lobe resulted in formation of a mycotic aneurysm with subsequent thrombosis and rupture. Despite surgical intervention and appropriate antibiotic therapy, the patient eventually succumbed to superimposed infection.

#### REFERENCES

1. Guard RW, Khafagi FA, Brigden MC, Ashdown LR. Melioidosis in far north Queensland. *Am J Trop Med Hyg* 1984; 33: 467-73.
2. Whitmore A, Krishnaswami CS. An account of the discovery of a hitherto undescribed infective disease occurring among the population of Rangoon. *Indian Med Gaz* 1912; 47: 262-7.
3. Howe C, Sampath A, Spotnitz M. The *pseudomallei* group: a review. *J Infect Dis* 1971; 124: 598-606.
4. Strauss JM, Groves MG, Mariappan M, Ellison DW. Melioidosis in Malaysia II. Distribution of *pseudomonas pseudomallei* in soil and surface water. *Am J Trop Med Hyg* 1969; 18: 698-702.
5. Pisespong Patamasucon, Schaad UB, Nelson JD. Melioidosis. *J Pediatr* 1982; 100: 175-82.
6. Lin HP, Puthucheary SD, Sinniah D. Acute septicaemic melioidosis occurring in a child with acute lymphoblastic leukaemia. *Clin Pediatr* 1980; 19: 679-99.
7. Rode JW, Webling DDA. Melioidosis in the northern territory of Australia. *Med J Aust* 1981; 1: 181-4.