

CERVICOFACIAL ACTINOMYCOSIS WITH PARAVERTEBRAL SPREAD: A CASE REPORT

J Abisheganaden, K N Sin Fai Lam, L S Chew, D Tan

ABSTRACT

We report a case of cervicofacial actinomycosis with paravertebral extension in a 60-year-old man who presented with recurrent neck masses. Diagnosis was confirmed on culture and histology of pus and debris obtained from surgical drainage. He improved only after lengthy in-hospital high dose penicillin therapy. He is currently well and is on maintenance doxycycline therapy for 6 months following the high dose penicillin therapy.

Keywords: cervicofacial, actinomycosis, paravertebral, abscess, sinuses

SINGAPORE MED J 1996; Vol 37: 229-232

INTRODUCTION

Cervicofacial actinomycosis is uncommon, is seldom suspected early in its course and the diagnosis easily eludes the clinician. It is a suppurative infection noted for forming external sinuses which discharge characteristic "sulphur granules". A normal inhabitant of the mouth, *Actinomyces israelii* acts as an opportunistic infection and spreads unimpeded by the usual anatomic barriers when endogenous oral commensals invade tissues of the face and neck. Fistula and palpable masses are the main physical signs, with pain and fever the most frequent symptoms. Mechanisms of host resistance and immunity to actinomycosis are unknown.

Principles for managing actinomycosis remain unchanged since 1960 when Peabody and Seabury emphasised intense and prolonged therapy coupled with a sound surgical approach to drainage of abscesses or radical excision of sinus tracts⁽¹⁾. Cervicofacial infection carries an excellent prognosis for response to antibiotics alone, when recognised early and treated appropriately.

CASE REPORT

WLK, a 60-year-old retired tailor, presented with the diagnostic and management problem of recurring neck swellings. He was first seen at Alexandra Hospital in February 1992 with a 2-month history of right-sided cervical and supraclavicular non-discharging neck masses.

These were thought to be matted lymph nodes. They averaged 3 cm in size and were located in the lower cervical and

supraclavicular regions. He had no systemic symptoms or symptoms referable to the ear, nose or throat region. He had no previous significant medical or surgical illnesses and he had a 20 pack-year smoking history. The chest X-ray was normal. Nasopharyngoscopy did not reveal any abnormal pathology. Excision biopsies of the swelling done on two separate occasions showed reactive follicular hyperplasia with no evidence of granuloma, acid-fast bacilli or malignancy. He was treated with a one-week empirical course of ampicillin and reviewed.

The swellings gradually shrank in size and disappeared, and he was well for the next 6 months. But in January 1993 he was found to have early signs of inflammation over the previous biopsy scar with three overlying small sinuses. The clinical impression then was that these were stitch sinuses and no specific therapy was instituted. However a month later he developed a round 4 cm swelling over the left supraclavicular fossa with surrounding sister swellings matted with it. A tru-cut biopsy of this lesion showed unremarkable lymphoid tissue, negative for malignancy. Sputum, laryngeal swabs and biopsy cultures for acid-fast bacilli were repeatedly negative. Toxoplasma and EBV serologies were negative.

In May 1993 the nodes on the left neck had increased in size, while those on the right had diminished. He did not have any fever, epistaxis, dysphagia, cough or hemoptysis. Ultrasound examination of the abdomen was normal. Computerised tomography (CT) of the neck and thorax showed enlarged lymph nodes in the thoracic inlet on both sides, in the posterior triangle of the neck on the left side and some nodes in the angle of the jaw on the left side. Incisional biopsy and drainage was performed for the left-sided swelling in June 1993. A pointing abscess 3 cm in diameter was found in the left supraclavicular fossa. Pus was mixed with necrotic debris and yellow granules were seen. The wall of the abscess was thickened. Several sinuses were found higher up in the neck on the same side. On histology, the skin showed collections of neutrophils and lymphocytes in oedematous and congested granulation tissue. A colony of actinomyces was seen in the inflamed granulation tissue. There was no evidence of tuberculosis. Anaerobic cultures of the pus further confirmed the presence of *actinomyces* species.

Unfortunately the patient refused hospitalisation for intravenous antibiotics and was treated with oral penicillin V 500 mg qds for 4 months. No dental clearance was performed as he was edentulous. A month after stopping oral antibiotics, he developed recurrent boils with discharging sinuses on both sides of the neck (Fig 1). He was restarted again on a prolonged course of penicillin V 500 mg qds for an additional 6 months. Thereafter, in March 1994, he developed a new eruption of swellings and pustules with sinuses on the back as well as a bulge on the left chest wall anteriorly. Full blood count (Hb 13.8 g/dL, Wbc 5.5 x

Department of Medicine
Alexandra Hospital
Alexandra Road
Singapore 159964

J Abisheganaden, MBBS, MRCP (UK), M Med (Int Med)
Medical Officer (Specialist)

K N Sin Fai Lam, MBBCH BAO, FRCPI
Consultant

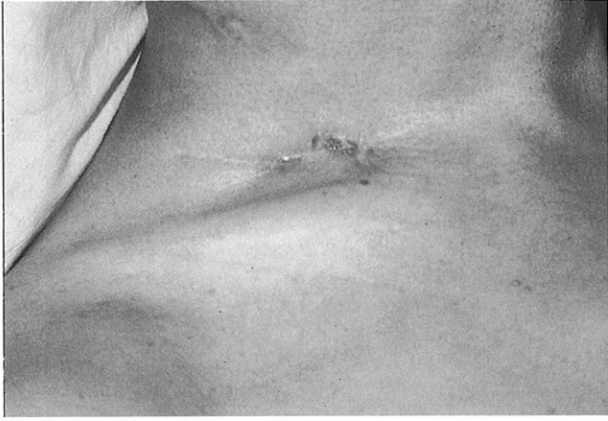L S Chew, MBBS, FRACP
Associate Professor & Head

Department of General Surgery
Alexandra Hospital

D Tan, MBBS, FRCS (Ed)
Senior Registrar

Correspondence to: Dr J Abisheganaden
Department of Respiratory Medicine
Tan Tock Seng Hospital
Moulmein Road
Singapore 308433

Fig 1 – Discharging sinuses over the neck



10⁹/L, Plt 173 x 10⁹/L) and liver function test were normal. Serum immunoglobulin assays, CD4 and CD8 counts and ratios were also normal. CT scans of the thorax showed a paravertebral soft tissue mass in the upper thoracic spine (Fig 2). Some bony erosion was noted in the C7 to T3 vertebrae. This was suspicious for spinal involvement. Plain radiography of the neck and thorax however did not show any bony erosions. The patient was admitted and treated with intravenous crystalline penicillin 12 million units/day for 8 weeks. The swellings subsided with antibiotics and the sinuses dried up after a month of in-hospital therapy. He had no neurological signs or symptoms referable to the spine. He was thereafter treated with a 6-month course of

doxycycline 100 mg bd and repeat CT scan performed in December 1994 showed that there was improvement, with only a small amount of residual right paravertebral soft tissue mass in the upper thoracic spine (Fig 3). The patient is currently well and asymptomatic.

DISCUSSION

Actinomyces israelii, the organism causing human actinomycosis, is a gram-positive, usually non-acid fast, anaerobic bacterium that is often considered with fungi because of its morphology. Clinically, actinomycosis involves 3 main anatomical areas. Cope's classic monograph reported cervicofacial lesions in 63%, thoracic disease in 15% and abdominal involvement in 22% of 1,330 patients⁽²⁾. Men are affected 3-4 times more often than women, and there is no occupational or environmental predisposition^(3,4).

Cervicofacial actinomycosis evolves in two forms⁽⁵⁾. The first, a painless slowly enlarging fluctuant swelling, is located at the crossing of the lower border of the mandible and the facial vessels. A dental portal of entry is usually implicated, and many, but not all patients, have neglected dental care⁽³⁾. The second form, more painful and widespread, simulates an acute pyogenic infection in the neck. The case presented describes the first form. The patient had recurring abscesses, lymphadenopathy and sinuses. He eventually developed a cold abscess over the left supraclavicular fossa. These lesions failed to resolve partly due to his refusal for in-hospital intensive high dose antibiotic therapy. As such, it is likely that the infection extended directly from the maxillo-facial region to the back and the paravertebral space. It might have even penetrated into the lower cervical and upper

Fig 2 – Computerised tomogram showing paravertebral soft tissue mass.

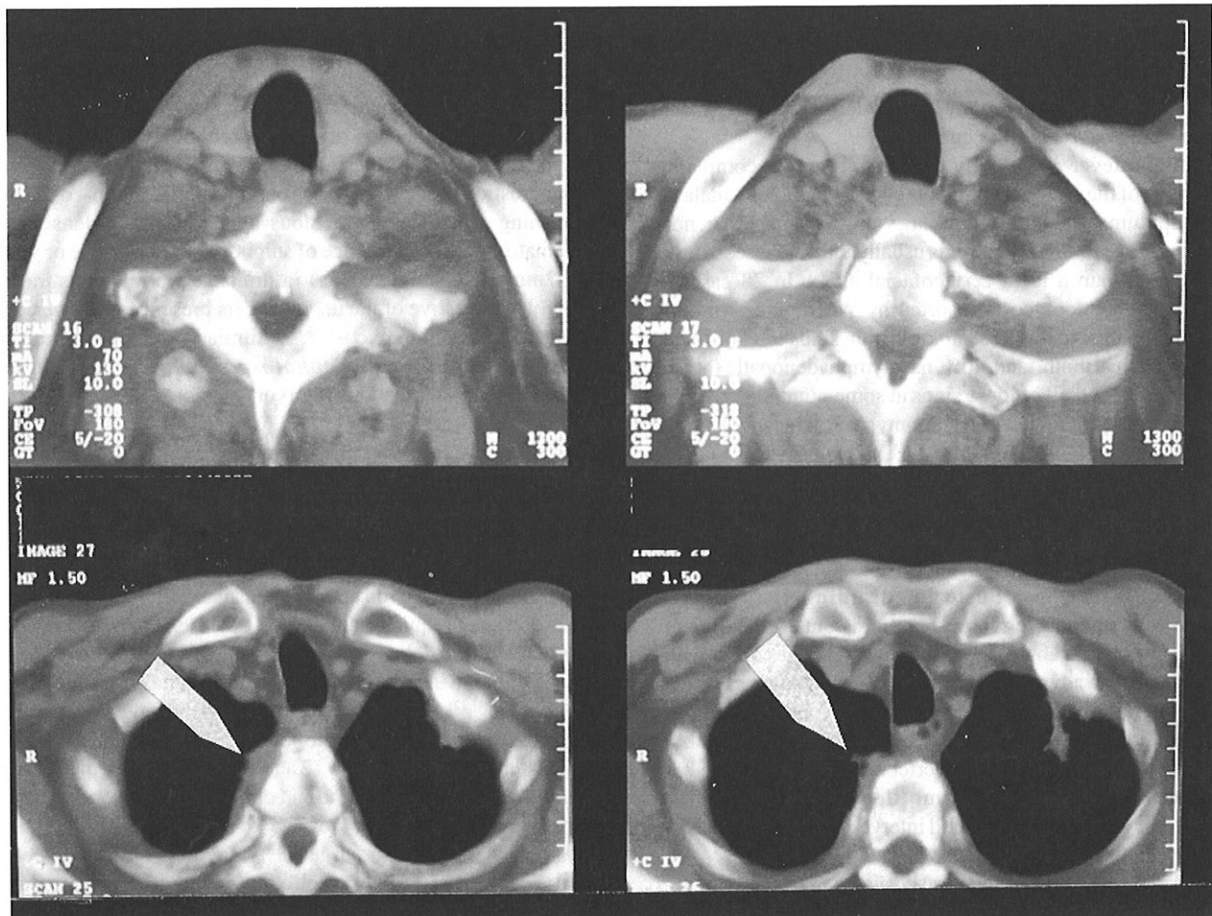
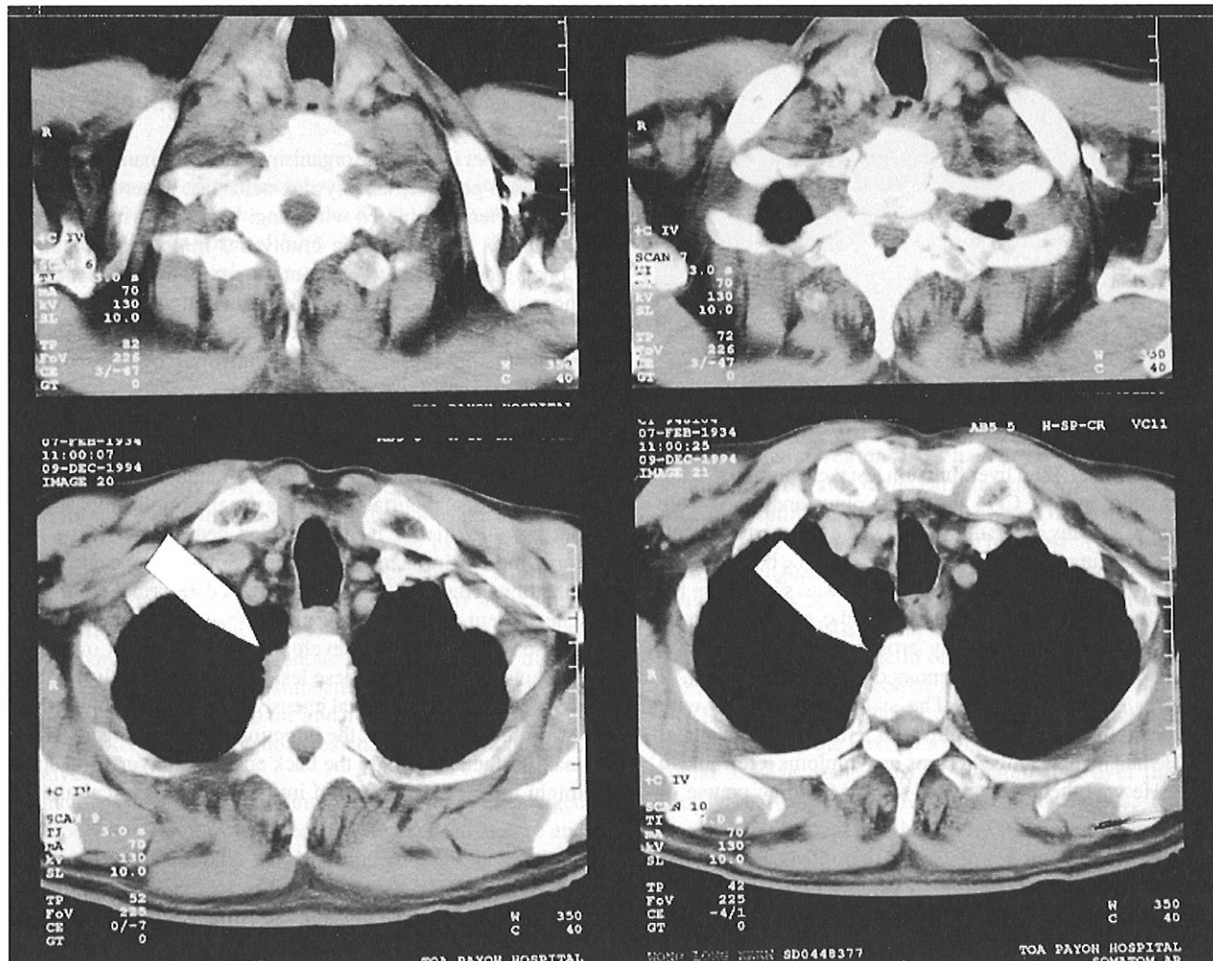


Fig 3 – Computerised tomogram showing small amount of residual paravertebral soft tissue mass in the repeat scan



thoracic vertebrae. Without any antibiotic therapy, this would most certainly have been the outcome.

Pain and fever are usually the most common complaints irrespective of the site of primary infection. Weight loss, malaise, cough, sputum production, nausea, vomiting and other non-specific gastrointestinal symptoms usually indicate disease more disseminated than a local cervicofacial site⁽⁶⁾. In 28 cases of cervicofacial actinomycosis reported by Weese and Smith, all had either a palpable mass (89%) or visible sinus tract or fistula (61%); 54% had both, and 40% had lymphadenopathy⁽⁶⁾. The patient we saw had all of these signs at some point in time in his illness. In a series of reviews of actinomycosis, bone involvement has been noted in 1%-15% of cases⁽⁷⁾. The majority (55%) of the actinomycotic infections involving bone were cervicofacial in location, 5% were localised to the extremities, and 40% were thoracic or lumbar. Bone disease almost always presents in association with well-established cervicofacial, thoracic, or abdominal infections. Posterior draining fistulae may communicate with the vertebrae, but more commonly originate from a paravertebral abscess. Radiographic changes occur when the disease is far advanced. A diffuse shadow suggestive of a paravertebral abscess may precede any bone changes. Differentiation from tuberculosis or other infections of the spine is important. Destruction of the vertebrae, combined with new bone formation, produces a mottled effect and, unlike tuberculosis, vertebral collapse and intervertebral disc narrowing are not common, as the disc space is usually spared⁽⁷⁾.

The key to diagnosis of actinomycosis lies in suspicion. Cases discovered are usually chanced upon during the extensive work-

up for tuberculosis or metastatic carcinoma. Culture remains the most definitive means of diagnosis, though the characteristic appearance of the micro-organism in biopsy material is also diagnostic. It is usually obvious on hematoxylin-eosin stain, forming a mass of filamentous hyphae staining densely with hematoxylin. The presence of sulphur granules (white or yellow, 1-2mm clumps of mycelia) in drainage from a sinus tract are highly suggestive of the diagnosis. Its presence, however, is not specific for actinomycosis⁽⁸⁻¹⁰⁾. Similar structures can be seen with *Monosporium*, *Cephalosporium*, *Nocardia*, some staphylococcal infections (botryomycosis), coccidioidomycosis, and aspergillosis.

In many instances the diagnosis is delayed as in the case presented. This is because special suspicion by the clinician is needed to obtain the appropriate cultures. As the micro-organism responds readily (at least initially) to penicillin, a solitary mass or lymph node such as in this patient which is a common manifestation, may disappear after an empirical antibiotic trial. Lesions may require drainage and debridement before adequate cultures of the debris are sent for analysis.

Penicillin in large doses and for long duration is the treatment of choice^(11,12). Administration should be intravenous penicillin G, 10-20 million units/day for the first 4 to 6 weeks, followed by oral administration for 6 to 12 additional months. Other effective alternatives are tetracycline and clindamycin. Extensive chronic disease occasionally may respond to intravenous penicillin alone and may not require surgery⁽¹³⁾. Our patient was placed on doxycycline instead of penicillin/tetracycline or clindamycin as he refused further intravenous therapy and there was a problem

of compliance - he wanted only the minimum daily-dosing frequency of oral medication for treatment.

Suppurative lesions should be excised or drained or both. Surgical debridement of soft-tissue lesions is believed by some to play a very important role. It may be used for diagnosis as in suspected metastatic carcinoma with lymphadenopathy. It also facilitates debridement of necrotic areas. However, even at surgery, the gross appearance may not resolve the surgeon's dilemma. The disease may not only mimic carcinoma of the lung but may also complicate it. Actinomycosis and tuberculosis can exist together.

Appropriate therapy yields an approximate 80%-90% recovery rate⁽⁷⁾. With a combination of massive long term administration of penicillin and wide surgical excision of infected tissues, the cure rate of this infection has been raised⁽⁴⁾.

CONCLUSION

Experience gained from this case has reinforced our understanding of the problems in diagnosing and treating actinomycosis. This is an uncommon disease whose initial presentation may lead the physicians to suspect tuberculosis or neoplasm. This case has illustrated the following:

- i) routine cultures seldom yield the pathogen, so cases may go unrecognised until adequate histology and cultures are taken and specified for the suspecting organism;
- ii) the picture most often mimics tuberculosis or malignancy; the true diagnosis is stumbled on when these two diagnoses are being pursued;
- iii) the avascularity and induration of infected areas emphasise the need for lengthy and high dosage antibiotic administration;

- iv) surgery may be used as a diagnostic procedure, when routine gram-stains and cultures are negative; it also permits debridement of localised necrotic areas and removal of persistent sinuses.

REFERENCES

1. Peabody JW, Seabury JH. Actinomycetes and norcardiosis. Am J Med 1960; 28: 99.
2. Cope Z. Actinomycosis. London: Oxford University Press, 1938.
3. Brown JR. Human actinomycosis. A study of 181 subjects. Human Pathology 1973; 4: 319.
4. Harvey JC, Cantrell JR, Fisher AM. Actinomycosis: its recognition and treatment. Ann Intern Med 1957; 46: 868-85.
5. Bramley P, Orton HS. Cervicofacial actinomycosis. A report of eleven cases. Br Dent J 1960; 109: 235.
6. Weese WC, Smith IM. A study of 57 cases of actinomycosis over a 36-year period. Arch Intern Med 1975; 135: 1562.
7. Lewis RP, Sutter VL, Finegold SM. Bone infections involving anaerobic bacteria. Medicine 1978; 57: 279.
8. Weed LA, Baggenstoss AH. Some problems in diagnosis of actinomycosis. Mayo Clin Proc 1949; 24: 463-72.
9. Graybill JR, Silverman BD. Sulphur granules: Second thoughts. Arch Intern Med 1969; 123: 430-2.
10. Auger C. Human actinobacillary and staphylococcal actinophytosis. Am J Clin Path 1948; 18: 645-52.
11. Holm P. Some investigations into the penicillin sensitivity of human-pathogenic actinomycosis and some comments on penicillin treatment of actinomycosis. Acta Pathol Microbiol Scand 1948; 23: 376.
12. Garrod LP. The sensitivity of *actinomyces israelii* to antibiotics. Br Med J 1952; 1: 1263.
13. McQuarrie DG, Hall WH. Actinomycosis of the lung and chest wall. Surgery 1968; 64: 905.