

## RADIOLOGICAL CASE

### CLINICS IN DIAGNOSTIC IMAGING (12)

M G Irwin, W C G Peh

SINGAPORE MED J 1996; Vol 37: 212-215

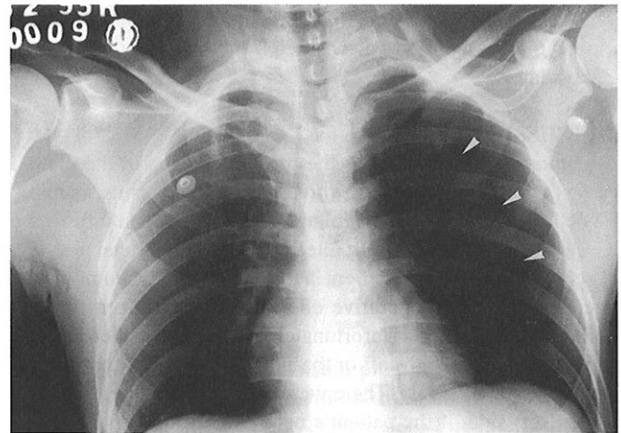
#### CASE REPORT

A 28-year-old Chinese man was admitted directly to the intensive care unit following an industrial accident resulting in injuries to his left arm and pelvis. Being hypotensive, he required resuscitation with large amounts of intravenous fluids and blood, and a right internal jugular central venous line was eventually inserted. A thorough clinical examination and radiographic imaging demonstrated fractures of the left humerus and pelvic ring, with associated soft tissue damage. Although the patient developed a mild degree of disseminated intravascular coagulation, his condition stabilised rapidly.

Two days later, he was scheduled for internal fixation of his fractured pelvis and urethral repair. Prior to induction of anaesthesia, the patient's oxygen saturation was noted to be only 87% despite not having apparent thoracic trauma. This improved to 100% following the administration of oxygen. Induction of general anaesthesia was straightforward, but after intubation, he developed very high inspiratory airway pressure during positive pressure ventilation. This was accompanied by decreased air entry to his left lung, with a significant fall in blood pressure and oxygen saturation (SaO<sub>2</sub> 60%). The anaesthetist checked that the endotracheal tube was in the correct position, excluding

endobronchial intubation. The preoperative chest radiograph was then quickly reviewed. What does this anteroposterior (AP) chest radiograph show (Fig 1)? What should the anaesthetist do next?

Fig 1 – Pre-operative chest radiograph



---

Department of Anaesthesiology  
The University of Hong Kong  
Queen Mary Hospital  
Hong Kong

M G Irwin, MBChB, FRCA, FHKAM  
Lecturer

Department of Diagnostic Radiology  
The University of Hong Kong

W C G Peh, FRCR, FHKAM, FAMS  
Senior Lecturer and Consultant

Correspondence to: Dr W C G Peh

---

## IMAGE INTERPRETATION

The pre-operative chest radiograph shows increased translucency of the left hemithorax, despite being generally well-centred. A thin sharp curvilinear line is visible (arrowheads), with a lack of lung markings within the space between this line and the adjacent lateral chest wall. The right lung is normal. The right-sided central venous line is well positioned.

## DIAGNOSIS

### Iatrogenic pneumothorax

## CLINICAL COURSE

A 16G intravenous catheter was inserted through the patient's chest wall at the second left intercostal space in the mid-clavicular line. There was a rush of air from the catheter, followed by an immediate improvement in his clinical condition. A chest tube with an underwater seal drain was then placed and surgery was able to proceed uneventfully. A follow-up radiograph showed reduction in size of the pneumothorax (Fig 2). The patient made a good recovery and was discharged from the intensive care unit 5 days later.

## DISCUSSION

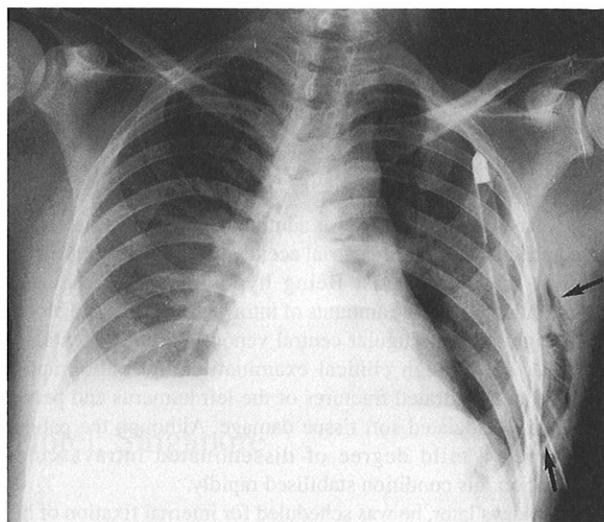
Pneumothorax is defined as the presence of gas in the pleural space. It can occur through three basic mechanisms, namely: Type I, intrapulmonary alveolar rupture; Type II, injury to the visceral pleura; and Type III, interruption of the parietal pleura<sup>(1)</sup>.

In retrospect, this patient had a left-sided pneumothorax present on his pre-operative chest radiograph taken the day following admission. Unfortunately, this was not detected by the attending medical staff or the anaesthetist who reviewed the patient pre-operatively. There were a number of puncture marks on the left side of the patient's neck where attempts had been made to introduce an internal jugular central venous catheter during resuscitation at admission and, in the absence of chest trauma, this was almost certainly the cause of the pneumothorax. The patient's pneumothorax was exacerbated during anaesthesia by the pleural leak increasing in size under the effect of positive pressure ventilation coupled with the influx of nitrous oxide into the pleural space. The solubility of nitrous oxide in blood is 34 times greater than that of nitrogen. Therefore, blood exposed to an air-filled pneumothorax will discharge nitrous oxide more rapidly than it absorbs nitrogen. This effect can double the pneumothorax volume in 10 minutes<sup>(2)</sup>.

Insertion of long needle such as that used for central venous catheterisation may cause a break in the visceral pleura (Type II mechanism), allowing slow and progressive air entry. Many other iatrogenic pneumothoraces are caused in a similar manner; examples include supraclavicular or perivascular brachial plexus block, stellate ganglion block, ventriculoperitoneal shunt, tracheostomy, intercostal nerve block, mediastinoscopy, percutaneous liver or renal biopsy, and acupuncture. This is also the mechanism by which chest trauma such as rib fractures can cause pneumothoraces. From an anaesthetist's viewpoint, alveolar rupture (Type I) can be caused by high inflation pressure during mechanical ventilation, particularly in the presence of pre-existing pulmonary disease or in children. Certain surgical procedures such as laparoscopy, spinal fusion, upper abdominal or neck surgery, oesophageal perforation and hypopharyngeal trauma from attempted intubation may also produce iatrogenic pneumothoraces. Recognised causes of pneumothorax are listed in Table I<sup>(3)</sup>.

In a recent study, the leading cause of iatrogenic pneumothorax was found to be transthoracic needle aspiration, followed by subclavian central vein catheterisation and thoracocentesis<sup>(4)</sup>. Pneumothorax may occur in up to 6% of

**Fig 2 – Subsequent chest radiograph shows a small residual pneumothorax following insertion of the chest tube. Iatrogenic subcutaneous emphysema of the left chest wall (arrows) is noted.**



**Table I - Causes of pneumothorax**

1. Spontaneous
2. Iatrogenic
3. Traumatic
4. Secondary to pneumomediastinum
5. Secondary to pneumoperitoneum
6. Secondary to lung disease
  - a) emphysema
  - b) cystic fibrosis
  - c) any cystic lung disease
  - d) pneumonia
  - e) broncho-pleural fistula
  - f) certain lung neoplasms

Table adapted from reference no. 3

subclavian central vein catheterisations but the incidence is less than 0.5% using the internal jugular approach<sup>(5)</sup>. The index of suspicion should be increased if the clinician is inexperienced and if placement or attempted placement requires multiple attempts<sup>(5)</sup>. Pneumothoraces are not always evident immediately following catheter placement, with signs and symptoms being delayed as long as 12 to 24 hours. It has been shown that the incidence of iatrogenic pneumothorax exceeds that of spontaneous pneumothorax, with the former accounting for substantial morbidity and some mortality, especially in conjunction with positive pressure ventilation<sup>(6)</sup>.

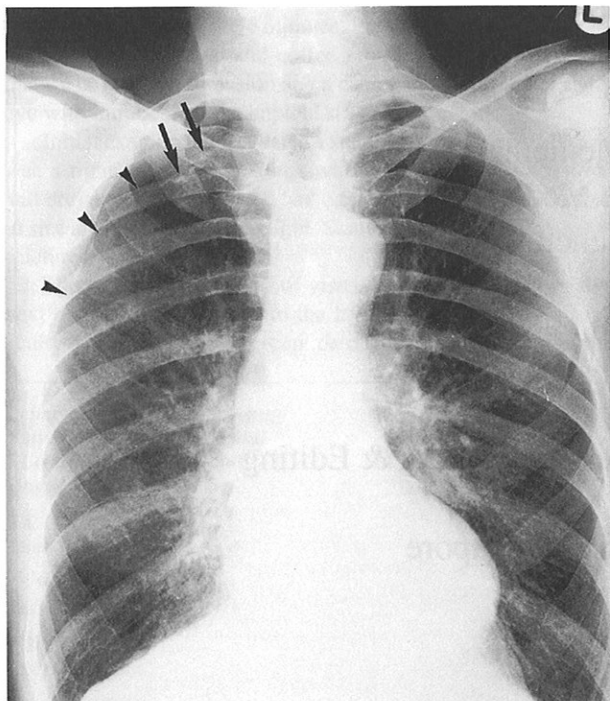
Clinical signs of pneumothorax depend on the patient's level of consciousness, associated cardiopulmonary disease and age. Tachycardia, tachypnoea, cough and chest pain exacerbated by deep breathing are early signs in an awake patient. Tension pneumothorax is a potentially rapidly lethal situation. There is a marked decrease in venous return, cardiac output and blood pressure, an increased pulmonary vascular resistance and shunt causing severe hypoxaemia and hypercapnia. Decreased air entry and hyper-resonance on the affected side, contralateral tracheal deviation (tension pneumothorax can also occur bilaterally with signs over the entire thorax), distended neck veins, subcutaneous emphysema and wheezing, with high pulmonary inflation pressures, if ventilated, are other signs which may be detected.

Radiographically, the cardinal sign of a pneumothorax is the

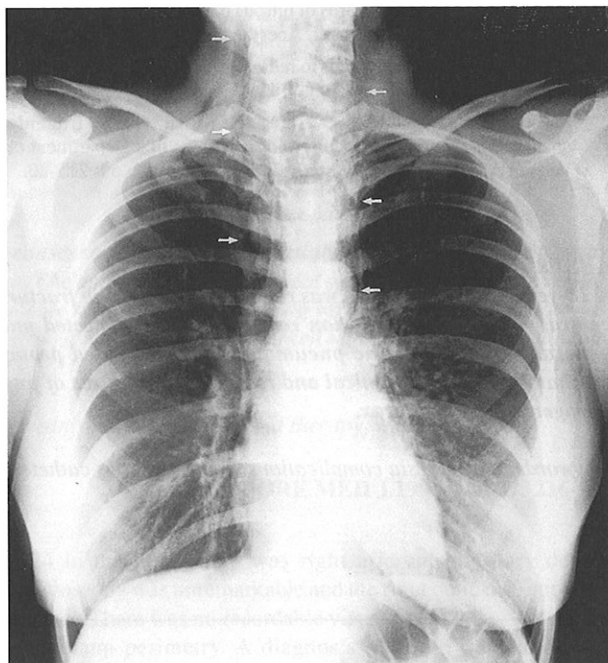
presence of a sharply defined white line, representing the visceral pleura, with a zone devoid of lung markings between this line and the adjacent chest wall, caused by air within the pleural cavity. In an erect chest radiograph, a small pneumothorax is usually seen at the apical region (Fig 3). Small pneumothoraces may be difficult to detect on supine AP radiographs, as air collects anteriorly and medially. Techniques which may help improve visualisation of pneumothoraces include use of a bright light during viewing, repeating a radiograph with the patient in expiration and obtaining a radiograph in a lateral decubitus position (with abnormal side uppermost). A pneumothorax may develop secondary to pneumomediastinum, which is demonstrated as translucent streaks of air outlining the great vessels and other mediastinal structures (Fig 4). A tension pneumothorax occurs as a result of increased intrapleural pressure due to a valvular mechanism by which air enters into, but does not leave, the pleural space during respiration. The resultant massive displacement of the mediastinum contralaterally may lead to acute cardio-respiratory embarrassment<sup>(7)</sup> (Fig 5).

A small (less than 20%) asymptomatic pneumothorax following minor pleural trauma in an awake, spontaneously breathing patient may be treated conservatively with close observation. On the other hand, the treatment of tension pneumothorax is immediate tube thoracostomy at the superior border of the rib at either the second intercostal space in the mid-clavicular line or the fifth intercostal space in the mid-axillary line. Delay of more than 30 minutes increases patient mortality significantly<sup>(8)</sup>. The insertion of a large bore needle or catheter is useful for diagnosis and acute relief. The patient may also benefit from administration of 100% oxygen and intravascular volume expansion. In such circumstances, immediate treatment of a suspected pneumothorax takes precedence over radiographic confirmation.

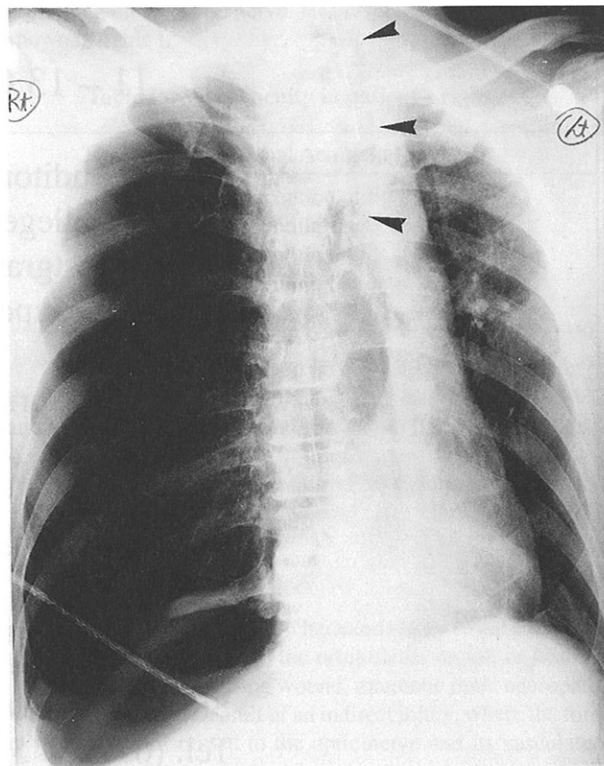
**Fig 3 – Erect chest radiograph shows a small right apical pneumothorax (arrowheads), made more obvious by some old tuberculous calcification (arrows) in the lung apex.**



**Fig 4 – Pneumomediastinum and subcutaneous emphysema are demonstrated as streaky translucent areas (arrows) in the mediastinal edges and soft tissues of neck, respectively.**



**Fig 5 – Patient with right tension pneumothorax. The right hemithorax is largely devoid of lung markings. The ipsilateral hemidiaphragm is depressed. The mediastinum, including the trachea (arrowheads), is markedly displaced contralaterally.**



## REFERENCES

1. Denlinger JK. Pneumothorax. In: Orkin FK, Cooperman LH, eds. Complications in anesthesia. Philadelphia: JB Lippincott, 1983: 173-82.
2. Eger EI, Saidman LJ. Hazards of nitrous oxide anaesthesia in bowel obstruction and pneumothorax. Anesthesiology 1965; 26: 61-5.
3. Chapman S, Nakielny R. Aids to radiological differential diagnosis. 2nd ed. London: Baillière Tindall, 1990: 125.
4. Sassoon CS, Light RW, O'Hara VS, Moritz TE. Iatrogenic pneumothorax: etiology and morbidity. Results of a Department of Veteran Affairs cooperative study. Respiration 1992; 59: 215-20.
5. Sznajder JJ, Zveibil FR, Bitterman H, Weiner P, Bursztein S. Central vein catheterisation: Failure and complication rates by three percutaneous approaches. Arch Intern Med 1986; 146: 259-61.
6. Despars JA, Sassoon CS, Light RW. Significance of iatrogenic pneumothoraces. Chest 1994; 105: 1147-50.
7. Rubens MB. The pleura-collapse and consolidation. In: Sutton D, editor. A textbook of radiology and imaging. 4th ed. Edinburgh: Churchill-Livingstone, 1987: 398-401.
8. Steier M, Ching N, Roberts EB, Nealon TF Jr. Pneumothorax complicating continuous ventilatory support. J Thorax Cardiovasc Surg 1974; 67: 17-23.

## ABSTRACT

*A 28-year-old Chinese man was resuscitated following fractures to his left humerus and pelvis. Multiple attempts at internal jugular central venous catheterisation resulted in an undetected pneumothorax, which became clinically apparent during induction of general anaesthesia. The pneumothorax was treated promptly and the patient made a successful recovery post-surgery. The mechanisms, causes, clinical and radiological features of pneumothorax are discussed, with emphasis on anaesthetically - related iatrogenic pneumothorax.*

*Keywords: anaesthesia complications, central venous catheterisation, pleural disease, pneumothorax, positive pressure ventilation*

## 5TH WORKSHOP ON MEDICAL WRITING & EDITING

organised by the Annals, Academy of Medicine, Singapore

11 – 13 October 1996

Venues: 1) Auditorium  
College of Medicine Building  
2) Postgraduate Medical Institute  
Singapore General Hospital

For further information, please contact:

The Secretariat  
5th Workshop on Medical Writing & Editing  
c/o The Annals  
Academy of Medicine, Singapore  
16 College Road  
Singapore 169854  
Tel: (65) 224 5166  
Fax: (65) 225 5155