

SIMULTANEOUS OPEN DISLOCATIONS OF THE INTERPHALANGEAL AND METACARPO-PHALANGEAL JOINTS IN A THUMB - A CASE REPORT

J C H Lee, H F See, C O Low

ABSTRACT

Simultaneous dislocations of the interphalangeal and metacarpo-phalangeal joints are rare. Most of the previous reports in the literature concerned closed injuries which were not associated with neurovascular involvement and were easily reduced and had favourable outcomes. They were also mainly due to a dorsally directed force on a hyperextended digit. We report a case of this rare injury due to a torsion force in a power drill accident resulting in an open injury with neurovascular damage and gangrene of the thumb distal to the wound despite re-vascularisation attempts.

Keywords: simultaneous open dislocations, thumb, interphalangeal, metacarpo-phalangeal, neurovascular impairment

SINGAPORE MED J 1996; Vol 37: 318-319

INTRODUCTION

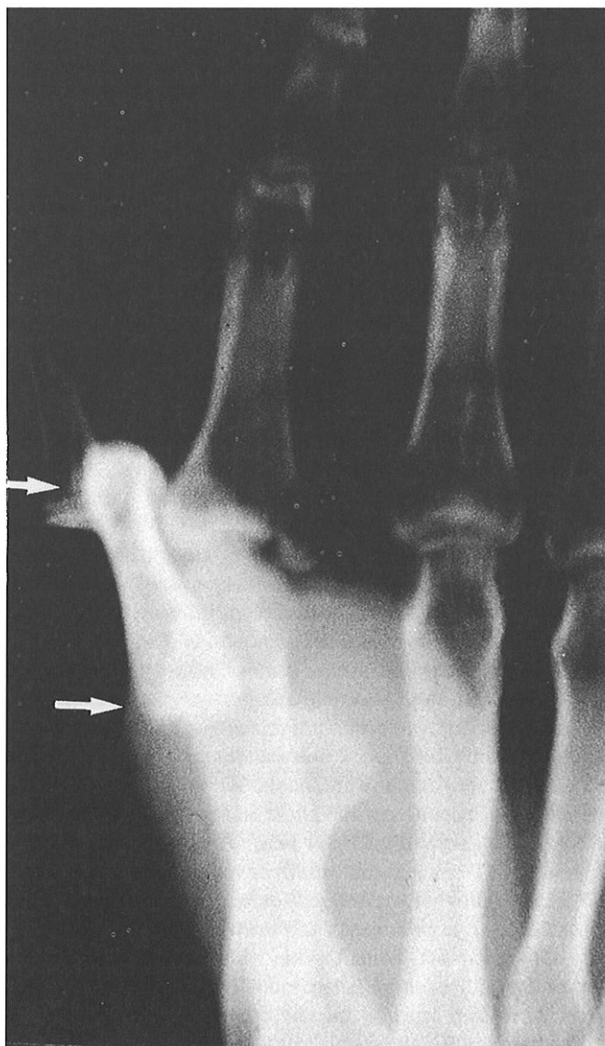
Several cases of simultaneous dislocations of the interphalangeal joints^(1,2), the interphalangeal and carpometacarpal joints^(3,4) and interphalangeal and metacarpo-phalangeal joints⁽⁵⁻⁷⁾ were reported in the literature. Most of the cases reported had no circulatory or neurological damage and were closed injuries. We report a case of a simultaneous open dislocations of the interphalangeal and metacarpo-phalangeal joints of the thumb with associated injury to the digital nerve and vessels.

CASE REPORT

A 33-year-old right-handed construction labourer from Malaysia sustained open dislocations of the interphalangeal joint and the metacarpo-phalangeal joint of the right thumb when it was violently twisted after being caught by a power drill. Examination under a brachial block showed an almost circumferential degloved wound at the level of the interphalangeal joint with a small isthmus of skin bridge left on the dorsal aspect of the right thumb. The interphalangeal joint was completely dislocated and the distal phalanx was held by the intact flexor pollicis longus and extensor pollicis longus tendons. Both the collateral ligaments as well as the volar plate were torn. The proximal limit of the laceration was over the metacarpo-phalangeal joint which was also dislocated with associated tears in the radial collateral ligament. The X-ray taken on admission is shown (Fig 1).

The right thumb was explored and the dislocations reduced. The interphalangeal joint was stabilised with two K wires. The digital nerve, artery and vein on the radial side were repaired under the microscope. On the ulnar side, the digital vein and

Fig 1 – The X-ray of the patient's right hand at the time of admission. The white arrows show the simultaneous dorsal dislocations of the interphalangeal and metacarpo-phalangeal joints of the right thumb in a step-ladder fashion.



nerve were also repaired. At the metacarpo-phalangeal joint level, the radial collateral ligament and capsule were repaired. The capillary return was good and a stab in the right thumb pulp

Department of Orthopaedic Surgery
Toa Payoh Hospital
3 Toa Payoh Rise
Singapore 298102

J C H Lee, M Med, FRCS (Edin), FICS
Consultant

H F See, M Med, FAMS, FRCS (Edin)
Senior Consultant

C O Low, M Med, FAMS, FRCS (Glas)
Consultant

Correspondence to: Dr J C H Lee
6 Napier Road #09-15
Gleneagles Medical Centre
Singapore 258499

showed good free blood flow. Post-operatively, the patient was put on intravenous molecular dextran. Eight hours post-surgery, the pulp of the right thumb was noted to be cyanosed distal to the inter-phalangeal joint level. Re-exploration of the thumb showed thrombosis of the digital veins. The thrombosed segments were resected and vein grafts interposed. Immediately following the procedure, the thumb looked less cyanosed. Intravenous molecular dextran was continued and the circulation monitored. Within six hours following the second surgery, the thumb distal to the interphalangeal joint turned black and was not viable. Amputation of the thumb at the level of the interphalangeal joint was then offered to the patient. The plan was to reconstruct the right thumb at a later time. The patient however declined the offer and requested to be discharged against medical advice and returned to Malaysia.

DISCUSSION

Simultaneous dislocation of more than one joint in a finger is rare. There were previous reports of simultaneous dislocations of the interphalangeal and metacarpo-phalangeal joints of the thumb by Nathan et al⁽¹⁾, Weseley⁽⁷⁾, Levy⁽⁶⁾, Cleak⁽⁵⁾, Wee et al⁽⁴⁾ and Hindley⁽²⁾. These reports with exception of Cleak⁽⁵⁾, dealt with closed dislocations. With the exception of Wee⁽⁴⁾, most authors reported easy reduction of the dislocations and satisfactory outcomes. There were no neurovascular impairment in their cases. In our case, there was a near amputation at the level of the interphalangeal level with both digital neurovascular bundles cut. The mechanism of injury was that of a torsional force which almost avulsed the distal portion of the thumb. There may have been intimal damage to the vessels beyond that which was clinically evident and this may account for the failure of the microsurgical repair.

The generally accepted mechanism of similar cases in the literature had been described by Nathan et al⁽¹⁾ and Ikpeme⁽³⁾. They postulated a force directed from the volar to dorsal side in a finger which was essentially extended. The resulting hyperextension force caused the simultaneous dislocations of the adjacent joints. Another reason postulated for the

predominantly dorsal dislocation was the weaker anatomical structures dorsally. In our case, the mechanism is unusual as it was a torsional force. The position of the thumb when it contacted the drill bit, the strength of the grip, the weight of the power drill and its speed at the time of the accident probably have a role in deciding the final extent of injury and the presence of any simultaneous joint dislocation.

This case illustrates the possibility of neurovascular injury in the rare simultaneous dislocations of the interphalangeal and metacarpo-phalangeal joints of the thumb and the possible unfavourable outcome if the mechanism of injury is a torsional force and the injury is an open one.

ACKNOWLEDGEMENT

No benefits in any form have been received or will be received from a commercial party related directly or indirectly to the subject of this article.

REFERENCES

1. Nathan FF, Schlein AP. Multiple dislocations of a single finger. *The Hand* 1975; 5: 52-4.
2. Hindley CJ. Triple dislocations in the index finger. *J Trauma* 1989; 29: 122-4.
3. Ikpeme JO. Dislocation of both interphalangeal joints of one finger. *Injury* 1977; 9: 68-70.
4. Wee JTK, Chandra D, Satku K. Simultaneous dislocations of the interphalangeal and carpometacarpal joints of the thumb: a case report. *J Hand Surg* 1988; 13B: 224-6.
5. Cleak DK. Simultaneous dislocation of the interphalangeal and metacarpo-phalangeal joints in a thumb. *The Hand* 1981; 13: 167-8.
6. Levy IM, Liberty S. Simultaneous dislocation of the interphalangeal and metacarpo-phalangeal joints of the thumb. *J Hand Surg* 1979; 4: 489-90.
7. Weseley MS, Barenfeld PA, Eisenstein AL. Simultaneous dorsal dislocation of both interphalangeal joints in a finger. *J Bone Joint Surg* 1978; 60A: 1142.