

CASE REPORTS AND MINI REVIEW OF BEE STINGS OF THE CORNEA

G Chuah, E Law, W K Chan, C L Ang

ABSTRACT

Bee stings of the eye are not uncommon. Quite a few clinical case reports⁽¹⁻³⁾ have documented the various ocular reactions to the venom of the bee stings, which may range from mild conjunctivitis to sudden loss of vision. This report presents 2 patients who suffered bee stings to the cornea and their different outcomes. The properties of bee venom as well as the treatment of various possible complications are also discussed.

Keywords: bee stings, corneal oedema, mellitin, topical steroid preparations, topical antibiotics

SINGAPORE MED J 1996; Vol 37: 389-391

CASE REPORTS

Case 1

A 26-year-old Indian man was riding his motorcycle when a bee stung his right eye. He was seen at the Accident and Emergency Department for the complaint of severe pain in his right eye. No other significant history of note was elicited.

Clinical examination showed a visual acuity of 6/60 (20/200) in the right eye and 6/9 (20/30) in the left eye.

The eye with the bee sting had the following findings: there was severe corneal oedema and radiating Descemet folds from the site of the sting. The sting penetrated the cornea and protruded into the anterior chamber. There were no keratic precipitates on the endothelial surface. There were 3+ cells in the anterior chamber.

A first attempt was made to remove the sting using the slit lamp but it was only partially removed. A further attempt was made under local anaesthesia using the operating microscope in the operating theatre to remove the sting with minimal damage to the eye but it was only partially successful, leaving behind a small fragment. The patient was admitted and started on gutt chloramphenicol, gutt indomethacin and tab chlorpheniramine.

The next day, a hypopyon was seen and a swab were taken for culture and sensitivity in the event of secondary infection.

Gutt gentamicin and gutt cefazoline three hourly were then started. Subsequently, the hypopyon decreased and iris atrophy and depigmentation was noted inferiorly (Fig 2). Topical steroids were started as the condition was improving and on the fifth day after admission, the hypopyon had disappeared and the corneal oedema had decreased. He was discharged one week after admission and his visual acuity had improved to 6/24 (20/80) in the right eye.

Singapore National Eye Centre
Third Hospital Avenue
Singapore 168751

G Chuah, MBBS, FRCS (Edin), M Med (Ophth)
Registrar

E Law, M Med (Ophth), FRCS (Edin)
Former Ophthalmology Trainee

W K Chan, MBBS, MMed (Ophth), FRCS (Edin)
Consultant

C L Ang, MBBS, FRCS (Glas), FCOphth
Consultant and Head

Correspondence to: Dr G Chuah
Department of Ophthalmology
National University Hospital
5 Lower Kent Ridge Road
Singapore 119074

Fig 1 – Slit lamp photograph showing bee sting embedded in cornea with corneal oedema and radiating Descemet folds.

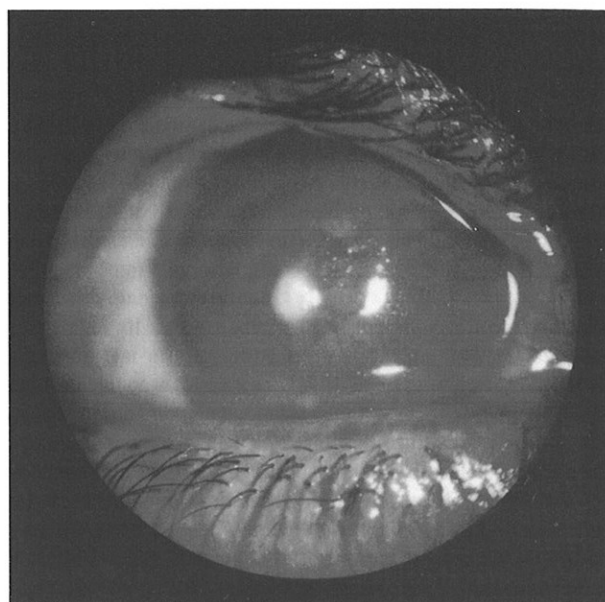


Fig 2 – Slit lamp photograph showing inferior iris depigmentation and atrophy.

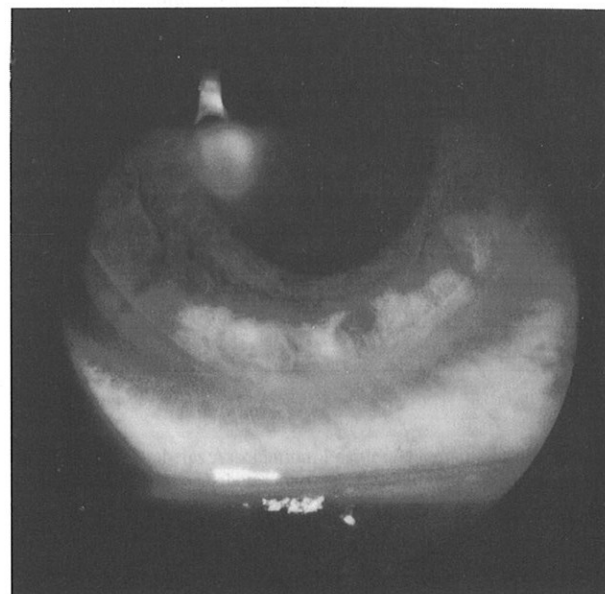
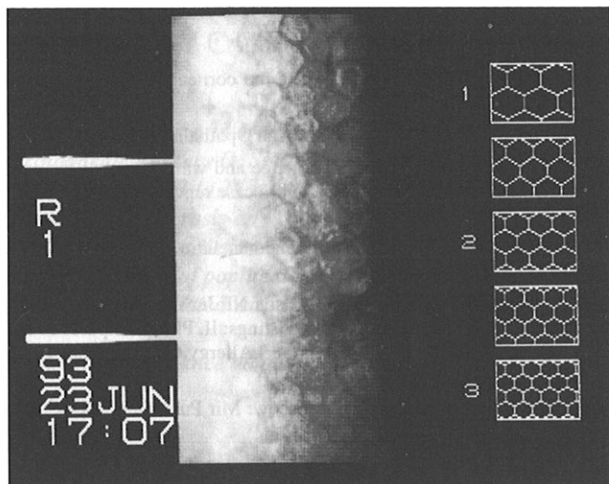


Fig 3 – Endothelial cell count showing polymegathism and polymorphism of the endothelium following the bee sting injury



An endothelial cell count done eleven days after admission showed 700 cells/mm², polymorphism and polymegathism (Fig 3). The other eye had a cell count of 2800 cells/mm².

A repeat endothelial cell count done sixty days after admission showed an increase to 1300 cells/mm² in the right eye.

Subsequently, on follow-up eight months later, he complained of decreased vision in the right eye for three days. Clinical examination showed the remnant sting in the cornea, mild epithelial oedema, fine keratic precipitates and 1+ cells in the anterior chamber. Intraocular pressures in the right eye was 16 mmHg and he was started on topical antibiotics and topical steroids. He is still presently on follow-up for this uveitis.

Case 2

A 47-year-old Chinese man had a bee sting in his right eye and was seen by a private ophthalmologist who tried but failed to extract the sting. He was subsequently referred to the Eye Department for further management.

At the time of examination he showed a visual acuity of Counting Fingers 3 feet in the right eye and 6/6 (20/20) in the left.

The main findings in the right eye were as follows: The cornea was oedematous with a localised abscess at the bee sting site. There were numerous Descemet folds. However, the sting did not enter the anterior chamber and no anterior chamber activity was seen.

The sting was removed with a 27 gauge needle under topical anaesthesia and the patient was admitted for further management. A swab was taken for bacteriological cultures and the patient was given a subconjunctival injection of gentamicin 20 mg and started on gutt gentamicin, gutt chloramphenicol and occ polymycin.

In the ward, his condition improved and the corneal abscess became localised. The corneal oedema had also decreased and he was discharged seven days after admission with gutt gentamicin and gutt chloramphenicol three hourly, occ polymycin om and gutt homatrophine 2% bd. His visual acuity in the right eye was 6/60 (20/200) at the time of discharge.

He was started on gutt betnesol qds seventeen days later and the visual acuity and corneal oedema improved further. Three months after admission, the corneal oedema had resolved and he had a visual acuity of 6/12 in the right eye.

DISCUSSION

Research has shown that bee stings are modified ovipositors (egg laying organs of female bees) and are situated posteriorly on the body of the bee. Bees use the sting only as a defensive weapon to inject the venom into the tissues of the victim and leave the sting behind in the process. The sting is usually withdrawn into the abdomen when not in use.

Bee venoms are similar to snake venoms, having both neurotoxic and haemolytic properties⁽¹⁾. The main toxin in bee venom is mellitin⁽⁴⁾, a strongly basic compound with strong surface activity. It is believed that its haemolytic effect is due to its effect on increasing permeability in erythrocytes and other cells. Three other polypeptide toxins (apamin, mast cell degranulating peptide and minimine) have also been identified, with apamin being mainly neurotoxic⁽¹⁾ (uncoordinated movements, spasms, convulsions have been reported). Other compounds such as biogenic amines (histamine and dopamine) and enzymes (phospholipase A⁽⁵⁾, phospholipase B and hyaluronidase) have also been discovered in bee venom⁽⁶⁾.

The other chemical properties of bee venom are as follows:

- a. Clear liquid with a specific gravity of 1.1313.
- b. Acidic reaction⁽⁸⁾.
- c. Aromatic odour and a bitter taste⁽⁶⁾.

As a result of the above compounds in bee venom, severe toxic and allergic reactions may occur. The severe eye pain after the bee sting is caused by a sudden release of highly concentrated biogenic amines, such as histamine, in the venom. It was proposed by Smolin and Wong⁽¹⁾ that the conjunctival injection, conjunctival chemosis and corneal oedema may be a Type 1 hypersensitivity reaction (mediated by IgE) to the high molecular weight enzymes in the venom. Hyphaema may be due to the indirect haemolytic effect of phospholipase A, direct haemolytic effect of the byproduct lysolecithin and inhibition of tissue thromboplastin by phospholipase A. Hyaluronidase, hemolitin, minimine and other amines of the venom may cause degeneration and lysis of the chromophores of anterior iris layers, leading to iris depigmentation⁽⁷⁾. This has been reported and was also seen in our first patient.

Clinical features reported include:

1. Severe pain
2. Periorbital oedema
3. External ophthalmoplegia
4. Conjunctival chemosis and injection
5. Corneal oedema
6. Striate keratopathy with radiating Descemet folds
7. Hyphaema
8. Iritis with severe reactions causing a hypopyon
9. Iris depigmentation causing Heterochromia iridis⁽²⁾
10. Sector iridoplegia which if severe, may lead to internal ophthalmoplegia⁽²⁾
11. Cataractous change in the lens^(2,3)
12. Subluxed lens
13. Retrobulbar neuritis^(9,10)
14. Optic papillitis^(9,10)
15. Papilloedema^(9,10)
16. Optic atrophy^(9,10)

Some of the above features were seen in the two patients described.

Management of patients with insect stings of the cornea (bee stings, wasp stings) can be divided into acute and long term measures.

The acute measures include:

1. Suppression of the inflammation induced by the venom. This

is usually done with topical steroid preparations.

2. Prevention of secondary infection with the use of topical antibiotics.
3. Oral anti-histamines to counteract some of the biogenic amine activity of the venom.
4. In severe iritis with resulting hypopyon in the anterior chamber, paracentesis may be attempted, especially if the sting has penetrated into the anterior chamber. This is to remove some of the venom from the anterior chamber. However, the risk of introducing infection must be balanced against the possible benefits that can be achieved.
5. Surgical removal of the sting may be difficult as it may be deeply impacted into the cornea. Injudicious and awkward attempts at its removal may cause more harm than if it was left alone. Complications such as flat anterior chamber and endophthalmitis may occur and if the risk of removing the sting outweighs the possible benefits (as is the situation in most cases), surgical intervention is not advisable.

The long term management includes the following:

1. Refractive correction. The corneal scar from the sting may induce corneal astigmatism. This should be corrected for with the appropriate visual aids (glasses / soft contact lenses if the astigmatism is not severe, hard contact lenses if the astigmatism is severe).
2. Penetrating keratoplasty. A therapeutic corneal graft may be required if the corneal scar lies directly on the visual axis, causing poor visual acuity or if corneal decompensation occurs as a result of endothelial cell injury.
3. Cataract surgery. This may be required if the injury results in cataractous change in the lens. The surgery may be

especially difficult if the cornea is also hazy and the lens is subluxed, requiring both a penetrating keratoplasty and cataract removal at the same time.

REFERENCES

1. Smolin G, Wong I. Bee sting of the cornea: case reports. *Ann Ophthalmol* 1982; 14: 342-3.
2. Singh G. Bee sting of the cornea. *Ann Ophthalmol* 1984; 16: 320-2.
3. Gilboa M, Gdal-On M, Zonis S. Bee and wasp stings of the eye: Retained intralenticular wasp sting-a case report. *Br J Ophthalmol* 1977; 61: 662-4.
4. Mackler BF, Kreil G. Honey bee venom mellitin. *Inflammation* 1977; 2: 55-65.
5. Sobotka AK, Franklin RM, Adkinson NF Jr, Valentine M, Baer H, Lichtenstein LM. Allergy to insect stings: II. Phospholipase A – the major allergen in honeybee venom. *J Allergy Clin Immunol* 1976; 57: 29-40.
6. Ioyrish N. Bees and people. Moscow: Mir Publishers. 1974: 141-50.
7. Young CA. Bee sting of the cornea: Case report. *Am J Ophthalmol* 1931; 14: 208-16.
8. Hoffman DR, Shioman WH. Allergens in bee venom. *J Allergy Clin Immunol* 1976; 58: 551-62.
9. Goldstein NP, Rucker CW, Klass DW. Encephalopathy and papilloedema after bee sting. *JAMA* 1964; 188: 1083-4.
10. Goldstein NP, Rucker CW, Woltman HW. Neuritis occurring after insect stings. *JAMA* 1960; 173: 1727-30.
11. Walsh FB, Hoyt WF. *Clinical neuro-ophthalmology*, ed 3. Baltimore: Williams & Wilkins Co, 1969: 2718-9.
12. Grant WM. *Toxicology of the eye*. Springfield Ill: Charles C Thomas Publisher, 1962: 63-5.