

SAFETY AND EFFICACY OF PERCUTANEOUS INOUE-BALLOON MITRAL COMMISSUROTOMY

W Gao, K W Lau, Z P Ding, T H Koh, J S Ardian, P P Goh, S Quek, A Ng, A Johan

ABSTRACT

Background: Although percutaneous transvenous mitral commissurotomy (PTMC) is currently accepted as the first-line treatment modality for selected patients with mitral stenosis, technical failures and the potential risk of inadvertent cardiac perforation with tamponade, resultant severe mitral regurgitation and death associated with the procedure continue to be important issues of concern.

Objectives: The purpose of this study was to assess the safety profile and acute results of Inoue-balloon PTMC in a consecutive series of 50 patients with symptomatic significant mitral stenosis who underwent the procedure between January 1993 and August 1994.

Results: PTMC was successfully completed in all patients without encountering cardiac perforation, cardioembolism, severe (\geq grade 3+) angiographic mitral regurgitation or death. The mitral valve area increased from $0.8 \pm 0.2 \text{ cm}^2$ to $1.7 \pm 0.4 \text{ cm}^2$ ($p=0.0001$) as assessed echocardiographically. Optimal results defined as a valve area improvement of $\geq 50\%$ and/or a final valve area of $\geq 1.5 \text{ cm}^2$ without significant mitral regurgitation (≥ 2 grade increase in mitral regurgitation or a final regurgitation $\geq 3+$) was obtained in 94% of patients.

Conclusion: We confirm that Inoue-balloon PTMC is a safe and highly effective procedure as reflected by the absence of cardiac perforation, cardioembolism, severe mitral regurgitation or death and the excellent enlargement in mitral valve area. Furthermore, in our study the clinical restenosis rate was low with the majority of patients maintaining their improved functional status over a 14-month follow-up period.

Keywords: balloon valvuloplasty, cardiac perforation, mitral stenosis, mitral regurgitation

SINGAPORE MED J 1996; Vol 37: 357-361

INTRODUCTION

Although percutaneous transvenous mitral commissurotomy (PTMC) has been shown to yield excellent short- and mid-term results in terms of valve area enlargement⁽¹⁻⁸⁾, it continues to be plagued by three major technical problems. First, current PTMC approach mandates the need to puncture the inter-atrial septum prior to advancing the Inoue-balloon assembly across the mitral valve. In inexperienced hands⁽⁹⁾ and in the presence of gross anatomic distortions such as aneurysmal left atrium⁽¹⁰⁾ or inter-atrial septum⁽¹¹⁾ and kyphoscoliosis⁽¹²⁾, the risk of inadvertent perforation of neighbouring cardiac structures with resultant

cardiac tamponade and death is accentuated. In contrast, this risk is markedly reduced when transseptal puncture is performed by skilled operators^(1,2,7,10).

Second, after having obtained transseptal access, there remains the need to manipulate the Inoue-balloon across the stenosed mitral valve. Although the learning curve for this part of the procedure is steeper and hence, easier to acquire than that of the double-balloon technique, failure to accomplish this has been noted in up to 9% of Inoue-balloon PTMC^(1,13).

Lastly, perhaps one of the most dreaded complications of PTMC is that of the occurrence of severe mitral regurgitation which has been reported in about 3% to 8% of procedures in large series (range, 0% to 39%)^(1,2,7,13-15). Various predictors of this particular procedure-related outcome have been reported; they include the use of oversized balloons and the presence of adverse valve morphologies, particularly extensive subvalvular disease^(1,15,16). Accordingly, this study specifically examined our success (and failure), acute complication rate, and short-term results of PTMC using the Inoue-balloon technique.

METHODS

Study Patients

Between January 1993 and August 1994, PTMC was performed in 50 consecutive patients (33 females and 17 males) with a mean age of 47 ± 11 years (range 29 to 67 years). The inclusion criteria were symptomatic moderate-to-severe mitral stenosis with \leq grade 2/4 mitral regurgitation, no evidence of thrombus within the left atrial cavity or attached to the atrial septum, and informed consent. The presence of a non-protruding, non-mobile left atrial appendage thrombus was not considered a contraindication to the procedure.

Chronic atrial fibrillation was detected in 56% of patients. There were 10 patients with restenosis after previous surgical commissurotomy. One patient was in NYHA functional class I, 26 in class II, 21 in class III and 2 in class IV. Grades 1/4 and 2/4 angiographic mitral regurgitation were detected in 22 and 11 patients respectively, whereas 17 patients did not display any pre-existing mitral regurgitation (Fig 1). The subcategoric and

Singapore Heart Centre
Singapore General Hospital
Mistri Wing
Third Hospital Avenue
Singapore 169608

W Gao, MD
Visiting Interventional Fellow

K W Lau, MBBS, M Med, FACC
Consultant

Z P Ding, MBBS, M Med
Consultant

T H Koh, MBBS, M Med
Consultant

J S Ardian, MD
Visiting Cardiology Fellow

P P Goh, MBBS, MRCP
Registrar

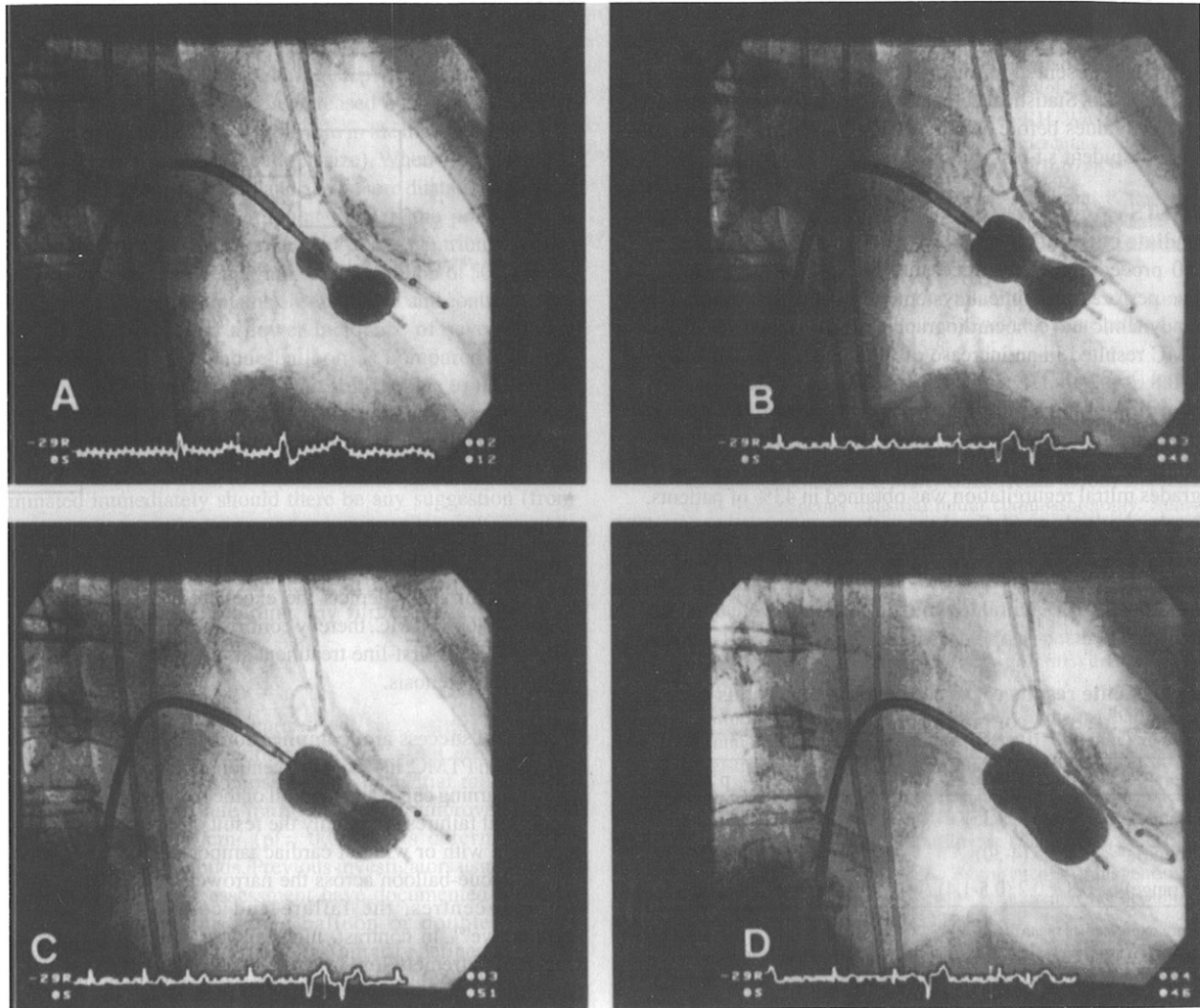
S Quek, MBBS, M Med
Consultant

A Ng, MBBS, M Med
Consultant

A Johan, MBBS, FRACP
Consultant

Correspondence to: Dr K W Lau

Fig 1 - Technique of anchoring the Inoue-balloon at the mitral valve. (A). The distal balloon is partially inflated and gently “floated” across the stenosed mitral valve. To ensure the smooth execution of this step, an optimal transseptal puncture site and catheter trajectory is vital [details in⁽¹⁰⁾]. Once the mitral valve is crossed, an “accordion” manoeuvre (simultaneous advancement and withdrawal of the balloon catheter and stylet in opposite directions) is performed to ascertain the balloon is free within the left ventricular cavity and not entrapped in the subvalvular apparatus; this minimises the risk of chordal rupture (with resultant severe mitral regurgitation) during full balloon inflation. The catheter with the partially inflated distal balloon is then pulled back to the mitral valve. **(B).** The proximal balloon segment is inflated, thereby anchoring the mid-balloon segment (waist) at the mitral valve. The balloon waist is subsequently inflated, splitting the fused commissures. **(C & D).** The above sequence of steps is repeated with the balloon inflated at incremental sizes until satisfactory haemodynamic results and/or complete obliteration of the waist of the appropriate-sized balloon catheter is obtained (stepwise dilatation method). In **(C)**, note the slight indentation on the inferior surface of the distal balloon due to subvalvular disease.



overall mitral echo-scores are as follows (scoring system described below): mobility = 1.7 ± 0.6 , thickness = 2.0 ± 0.3 , calcification = 1.5 ± 0.7 , subvalvular = 2.3 ± 0.9 , and overall = 7.4 ± 1.6 .

Echocardiography

Patients routinely underwent a comprehensive transthoracic 2-dimensional echocardiographic and Doppler evaluation before and soon after PTMC. Using a 4-point semiquantitative scoring system (1 to 4, with higher scores representing more severe disease) devised by Wilkins et al⁽¹⁷⁾, the total echo-score was obtained by adding the score for each of the following 4 individual morphologic features which include leaflet mobility, thickness, calcification and subvalvular disease. The mean mitral valve area before and after PTMC was estimated using continuous wave Doppler mitral velocity profile and by direct planimetry. Transoesophageal echocardiography was routinely

performed in all patients 1 or 2 days prior to PTMC to exclude the presence of left atrial thrombus.

Percutaneous transvenous mitral commissurotomy technique

The 1-stage diagnostic and interventional procedure was executed as described in detail previously^(2,8). One of the authors (KWL) was an operator in all the procedures. Briefly, after diagnostic right and left heart catheterisation, atrial transseptal access was obtained⁽¹⁰⁾. PTMC was performed using an appropriate-sized Inoue balloon catheter (Toray Industries, Japan) determined from the height of the patient and the stepwise dilatation technique^(8,15) (Fig 1). The reference balloon size was determined from the height of the patient using the balloon sizing method previously described by Hung and Lau⁽⁸⁾. After each dilatation, the left atrial pressure was determined using the Inoue catheter and the left ventricular pressure with a 7 F pigtail catheter to assess the mitral valve gradient. To avoid the creation of severe mitral

regurgitation, the procedure was terminated once a satisfactory haemodynamic result was obtained, when the transmitral gradient failed to decrease despite a few more dilatations using larger balloon sizes or when significant mitral regurgitation was suspected from the left atrial pressure (manifested as lack of reduction or increase in the mean left atrial pressure and accentuated left atrial v waves or if necessary, a confirmatory left ventriculogram during the procedure) and from auscultation performed after each valve dilatation. Left ventriculography was routinely performed immediately before and after PTMC to determine the change in the severity of mitral regurgitation graded according to Sellers' criteria⁽¹⁸⁾.

Statistical analysis

All data are presented as mean \pm standard deviation unless otherwise stated. Statistical comparisons between continuous and categorical values before and after PTMC were analysed using the paired Student's t-test and chi-squared test, respectively.

RESULTS

Immediate outcome

All 50 procedures were successfully completed without any cardiac perforation, clinical systemic embolism or death. The haemodynamic and echocardiographic results are listed in Table I. PTMC resulted in an increase of the mean mitral valve area from 0.8 ± 0.2 to 1.7 ± 0.4 cm² ($p=0.0001$) as assessed by echocardiographic methods in parallel with a substantial reduction in both the left atrial pressure and transmitral gradient. An increase in mitral valve area $\geq 100\%$ without an increase of ≥ 2 grades mitral regurgitation was obtained in 43% of patients. Optimal valvuloplasty (defined as a valve area improvement of $\geq 50\%$ and/or a final valve area of ≥ 1.5 cm² without an associated increase of ≥ 2 grades mitral regurgitation or a final mitral regurgitation of $\geq 3+$ mitral regurgitation) results were obtained in 94% of patients.

Table I – Acute results of percutaneous transvenous mitral commissurotomy

	Pre-PTMC	Post-PTMC	p value*
LAP (range)	22 \pm 6 (11-35)	18 \pm 5 (3-30)	0.0001
MG (range)	14 \pm 5 (4-30)	5 \pm 2 (0-11)	0.0001
MVA (range)	0.8 \pm 0.2 (0.5-1.4)	1.7 \pm 0.4 (0.9-2.6)	0.0001

Values are expressed as mean \pm SD

LAP, mean left atrial pressure (mmHg); MG, transmitral gradient (mmHg); MVA, mitral valve area (cm²) determined by echocardiographic methods;

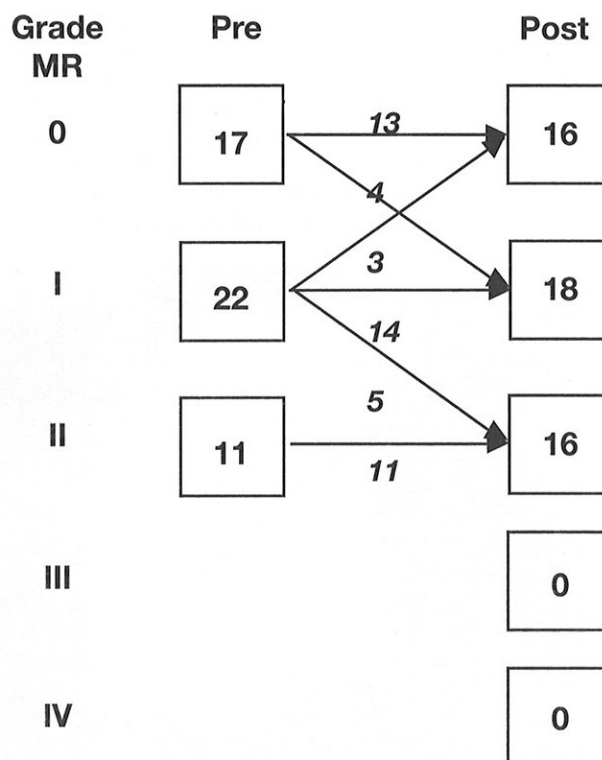
*for comparison between pre- and post-PTMC results

The severity of mitral regurgitation did not change or actually decreased by 1 grade in 41 patients (82%). An increase in ≥ 1 grade angiographic mitral regurgitation post-PTMC was identified in 9 patients (18%) with no patient experiencing a 2-grade increase in mitral regurgitation, a final $\geq 3+$ grade mitral regurgitation or required emergency mitral valve surgery in our series (Fig 2).

Follow-up clinical status

At a mean follow-up of 14 months, 88% of patients were in NYHA class I, 5% in class II, and 7% in class III and IV. Repeat PTMC and mitral valve replacement were required in 1 and 2 patients, respectively, for mitral restenosis associated with functional deterioration. All 3 patients had adverse valve characteristics, particularly the presence of significant valvular calcification. Symptomatic benefit in terms of an improvement in functional class of ≥ 1 grade or maintained NYHA class I after PTMC was recorded in 93% of patients after PTMC.

Fig 2 – Angiographic mitral regurgitation before and after percutaneous transvenous mitral commissurotomy



DISCUSSION

The present study depicts the excellent acute outcomes after Inoue-balloon PTMC, thereby confirming the safety and efficacy of PTMC as a first-line treatment strategy for selected patients with mitral stenosis.

Technical success and complications

Success in PTMC, like any interventional procedure, is associated with a learning curve and the skill of the interventionalist^(1,2,6,7,9,19). Technical failures are mainly the result of erroneous transseptal puncture with or without cardiac tamponade, or failed passage of the Inoue-balloon across the narrowed mitral valve. In low-volume centres, the failure and complication rates are prohibitive⁽⁹⁾. In contrast, high-volume skilled operators have reported extremely low failure and complication rates^(1,10). The excellent technical success rate of 100% in this study is ascribable to the fact that the main operators in this study have acquired their transseptal and PTMC skill prior to the study and thus, were beyond the learning curve. Furthermore, we have adhered closely to the transseptal and Inoue-balloon techniques described in detail elsewhere^(10,20) and which we have found invaluable in enhancing the success rate and reducing the complications of PTMC.

Another dreaded complication of PTMC is the creation of severe mitral regurgitation which remains the Achilles' heel of PTMC. In contrast to mild regurgitation which occurs in about 20% to 80% of patients⁽¹⁾, is usually secondary to commissural splitting and inadequate leaflet coaptation⁽²¹⁾ and of no clinical relevance [with the majority frequently resolving within a few months after the procedure⁽¹⁾], severe mitral regurgitation is commonly due to avulsion of leaflets or subvalvular structures, and may mandate mitral valve replacement^(21,22). Fortunately, in the present series, no procedure resulted in severe mitral regurgitation. Possible explanations for this excellent outcome include our selection of patients and our balloon sizing approach.

First, cognizant of the close relation between the extent of valve disease and the risk of resultant severe mitral regurgitation after PTMC⁽¹⁾, we largely excluded patients with strongly adverse valve characteristics in the present study as is reflected by the overall low echo-scores and the inclusion of only a small number of patients with heavily calcified valves.

Second, to avoid this disastrous complication, we applied the balloon sizing method advocated by Hung and co-workers^(8,15) and Inoue's stepwise dilatation method⁽²³⁾ for the performance of PTMC in valves with adverse anatomy, especially those with fluoroscopically visible dense calcification and/or extensive subvalvular disease detected by echocardiography or by balloon compression sign^(2,15). Briefly, in this method, the first balloon inflation is at 4 mm less than the estimated reference balloon size. In subsequent inflations during stepwise dilatation of the mitral valve, the balloon size is increased by 1 mm in the low intra-balloon pressure zone and 0.5 mm in the high pressure zone (within 2 mm of the nominal balloon size). When the transmitral gradient is reduced by one-half and a few more dilatation attempts can no longer reduce the gradient further, the procedure is terminated. This cautious approach may have contributed to the absence of severe mitral regurgitation in our cohort of 50 patients.

Finally, although it remains observational and controversial, some reports have cited a lower incidence of severe mitral regurgitation with the Inoue-balloon as compared with the double-balloon technique^(8,14,24). This may be due to the unique geometry of the Inoue-balloon and its potential for stepwise dilatation and haemodynamic measurements after each inflation-deflation cycle, which in turn allows the procedure to be terminated immediately should there be any suggestion (from auscultation, left atrial haemodynamics, echocardiographic assessment or if necessary, left ventriculography during the procedure) of a new or increase in the grade of mitral regurgitation, thereby avoiding any further exacerbation in regurgitation.

Mitral valve enlargement

In this study, PTMC when carried out successfully produced dramatic immediate reduction in the left atrial pressure and transmitral gradient, accompanied by substantial mitral valve enlargement. The absolute mitral valve area improved by 0.9 cm² from 0.8 to 1.7 cm² ($p = 0.0001$) as determined by echocardiographic methods. Previous investigators using similar methods of valve area assessment have documented identical results with either the Inoue-balloon or double-balloon technique^(1,25,26). Optimal dilatation, arbitrarily defined as $\geq 50\%$ increase in the mitral valve area and/or a final valve area of ≥ 1.5 cm² without an increase of ≥ 2 grades mitral regurgitation, was obtained in 94% of patients, of which about half of them attained $\geq 100\%$ gain in mitral valve area. Although not examined in this study, in our previous analysis of numerous baseline clinical, echocardiographic, haemodynamic and procedural parameters in a multivariate model, we have found no reliable independent predictor of optimal or suboptimal valvuloplasty outcome^(7,27).

CONCLUSION

Our study confirms that PTMC should be the first-choice treatment strategy for selected patients with symptomatic mitral stenosis. In our cohort of 50 patients, we demonstrated that the technique was safe and efficacious in enlarging the mitral valve orifice: the failure rate and the incidence of suboptimal results were both low. Importantly, we did not observe any cardiac perforation, cardioembolism, severe mitral regurgitation, emergency surgery or death in our study. However, in valves with adverse anatomy, particularly the presence of extensive

calcification, where we have observed a greatly increased likelihood of restenosis, we currently advocate mitral valve replacement as the treatment of choice. In such a situation, PTMC should only be attempted if the patient refuses surgery.

ACKNOWLEDGEMENT

The authors are grateful to the staff of the Cardiovascular Laboratory/Department of Cardiology, Cardiothoracic Surgeons and Sim LL for their support, and Dr Hung JS for sharing his enthusiasm for research, and his knowledge and words of encouragement.

REFERENCES

1. Lau KW, Ding ZP, Hung JS. Percutaneous balloon mitral commissurotomy: An update. *J Invas Cardiol* 1994; 6: 145-53.
2. Hung JS, Chern MS, Wu JJ, Fu M, Yeh KH, Wu YC, et al. Short- and long-term results of catheter balloon percutaneous transvenous mitral commissurotomy. *Am J Cardiol* 1991; 67: 854-62.
3. Desideri A, Vanderperren O, Serra A, Barraud P, Petitclerc R, Lesperance J, et al. Long-term (9 to 33 months) echocardiographic follow-up after successful percutaneous mitral commissurotomy. *Am J Cardiol* 1992; 69: 1602-6.
4. Chen CR, Cheng TO, Chen JY, Zhou YL, Mei J, Ma TZ. Long-term results of percutaneous mitral valve with the Inoue balloon catheter. *Am J Cardiol* 1992; 70: 1445-8.
5. Park SJ, Kim JJ, Park SW, Song JK, Doo YC, Lee STK. Immediate and one-year results of percutaneous mitral balloon valvuloplasty using Inoue and double-balloon techniques. *Am J Cardiol* 1993; 71: 938-43.
6. Arora R, Gurcharan SK, Murty GSR, Trehan V, Jolly N, Mohan JC, et al. Percutaneous transatrial mitral commissurotomy: Immediate and intermediate results. *J Am Coll Cardiol* 1994; 23: 1327-32.
7. Lau KW, Lee CY, Ding ZP, Tan A, Chan C, Quek S, et al. Acute outcome of percutaneous Inoue-balloon mitral commissurotomy. *J Heart Valve Dis* 1994; 3: 588-93.
8. Lau KW, Hung JS. A simple balloon sizing method in Inoue-balloon percutaneous transvenous mitral commissurotomy. *Cathet Cardiovasc Diagn* 1994; 33: 120-9.
9. Complications and mortality of percutaneous balloon mitral commissurotomy. A report from NHLBI Balloon Valvuloplasty Registry. *Circulation* 1992; 85: 2014-24.
10. Hung JS. Atrial septal puncture technique in percutaneous mitral commissurotomy. Mitral valvuloplasty using the Inoue balloon catheter technique. *Cathet Cardiovasc Diagn* 1992; 26: 275-84.
11. Lau KW, Ding ZP, Johan A. Percutaneous transvenous mitral valvuloplasty in the presence of atrial septal aneurysm. *Cathet Cardiovasc Diagn* 1994; 31: 337-40.
12. Ramasamy D, Zambahari R, Fu M, Yeh KH, Hung JS. Percutaneous transvenous mitral commissurotomy in patients with severe kyphoscoliosis. *Cathet Cardiovasc Diagn* 1993; 30: 40-4.
13. Rihal CS, Holmes DR. Percutaneous balloon mitral valvuloplasty: Issues involved in comparing techniques. *Cathet Cardiovasc Diagn* 1994; Suppl 2: 35-41.
14. Vahanian A, Cormier B, Lung B. Percutaneous transvenous mitral valvuloplasty using the Inoue balloon: International experience. *Cathet Cardiovasc Diagn* 1994; Suppl 2: 8-15.
15. Lau KW, Hung JS, Ding ZP, Johan A. Controversies in balloon mitral valvuloplasty: The when (timing for intervention), what (choice of valve) and how (selection of technique). *Cathet Cardiovasc Diagn* 1995; 35: 91-100.
16. Lau KW, Hung JS. "Balloon impasse": A marker for severe mitral subvalvular disease and a predictor of mitral regurgitation in Inoue balloon percutaneous transvenous mitral commissurotomy. *Cathet Cardiovasc Diagn* 1995; 35: 310-9.
17. Wilkins GT, Weyman AE, Abascal VM, Block PC, Palacios I. Percutaneous balloon dilatation of the mitral valve: An analysis of echocardiographic variables related to outcome and the mechanism of dilatation. *Br Heart J* 1988; 60: 299-308.
18. Sellers RD, Levy MJ, Amplatz K, Lillehei CW. Left retrograde cardioangiography in acquired cardiac disease: technic, indications

- and interpretations in 700 cases. *Am J Cardiol* 1964; 14: 437-47.
19. Tuzcu EM, Block PC, Palacios IF. Comparison of early versus late experience with percutaneous mitral balloon valvuloplasty. *J Am Coll Cardiol* 1991; 17: 1121-4.
 20. Inoue K, Hung JS. Percutaneous transvenous mitral commissurotomy (PTMC): the Far East experience. In: Topol EJ, ed. *Textbook of Interventional Cardiology*. 1st edition. Philadelphia: WB Saunders Co. 1990: 887-99.
 21. Essop MR, Wisenbaugh T, Skoularigis J, Middlemost S, Sareli P. Mitral regurgitation following mitral balloon valvotomy. Differing mechanisms for severe vs mild-to-moderate lesions. *Circulation* 1991; 84: 1669-79.
 22. Herrmann HC, Lima JAC, Feldman T, Chrishom R, Isner J, O'Neill W, et al, for the North American Inoue Balloon Investigators. Mechanisms and outcomes of severe mitral regurgitation after Inoue balloon valvuloplasty. *J Am Coll Cardiol* 1993; 22: 783-9.
 23. Inoue K, Owaki T, Nakamura T, Kitamura F, Miyamoto N. Clinical application of transvenous mitral commissurotomy by a new balloon catheter. *J Thorac Cardiovasc Surg* 1984; 87: 394-402.
 24. Abdullah M, Halim M, Rajendran V, Sawyer W, Al Zaibag M. Comparison between single (Inoue) and double balloon mitral valvuloplasty: Immediate and short-term results. *Am Heart J* 1992; 123: 1581-8.
 25. Davidson CJ, Bashore TM, Mickel M, Davis K, for the NHLBI Balloon Valvuloplasty Registry Participants. Balloon mitral commissurotomy after surgical commissurotomy. *Circulation* 1992; 86: 91-9.
 26. Ruiz CE, Zhang HP, Gamra H, Allen JW, Lau FYK. Late clinical and echocardiographic follow up after percutaneous balloon dilatation of the mitral valve. *Br Heart J* 1994; 71: 454-8.
 27. Lau KW, Gao W, Ding ZP, Hung JS. Immediate and long-term results of percutaneous Inoue balloon mitral commissurotomy with the use of a simple height-derived balloon sizing method for the stepwise dilation technique. *Mayo Clin Proc* 1996; 71: 556-63.

OFFERING 3 ATTRACTIVE CAR FINANCING SCHEMES UPFRONT...

FLAT RATE

FLEXI DRIVE

FLEXI MAX

Car financing has never been so easy and so versatile. You can choose from our 3 types of financing schemes.

FLAT RATE

Competitive rates and fixed monthly repayments which make it easier to plan your cash flow. Rebate for early settlement is calculated using the Rule of 78 method (this applies also to hire purchase agreements which are not under the Hire Purchase Act).

FLEXI-DRIVE

Interest is on monthly rest basis. You can make partial or full capital repayment at no additional cost.

FLEXIMAX

It lets you switch between fixed and floating rates to your advantage. You can start with a fixed rate and lock in the interest rate for an initial period of up to 6 years and still enjoy a repayment term of up to 7 years; OR You can start with a floating rate for an initial period of up to 6 years with a 7-year repayment term. At the end of the initial period, you can opt for either fixed or floating rate for the remaining repayment period. Interest is on monthly rest basis.

For more details on the car financing that suits you best, call our Toll-free Hotline at **1800-223-0110** or visit any of our branches today.

* *FlexiMax & Flexi-Drive are applicable only for cars priced above \$55,000 (excluding COE).*
 ** *For used cars, age plus repayment period shall not exceed 10 years.*

MAKING IT WITH YOU
DBS FINANCE

Head Office: 112 Robinson Road, DBS Finance Building, Singapore 068902 Tel: 223 0355
 • **Bukit Batok Branch** Tel: 565 9085 • **Clementi Branch** Tel: 777 0894
 • **Jalan Besar Branch** Tel: 291 1888 • **Katong Branch** Tel: 345 4155
 • **New Bridge Road Branch** Tel: 225 3300 • **Yishun Branch** Tel: 752 4988
 • **Lending Point Marina Square Branch** Tel: 337 7893

AP 0334