TWO-DIMENSIONAL AND DOPPLER ECHOCARDIOGRAPHIC ABNORMALITIES IN IDIOPATHIC DILATATION OF THE PULMONARY ARTERY

B L Chia, B K Ee

ABSTRACT

Although idiopathic dilatation of the pulmonary artery is uncommon, it requires to be distinguished from other important congenital heart diseases for which it may be confused clinically. We describe the two-dimensional (2D) and Doppler echocardiographic findings in two patients with this condition. Enlargement of the main pulmonary artery and right ventricle was demonstrated in both patients using 2D echocardiography. Pulmonary regurgitation was confirmed in Case 1 by both pulsed-Doppler echocardiographic and Doppler colour flow imaging studies and in Case 2 by microbubbles (which were generated from saline-injection into a peripheral vein) oscillating up and down across the pulmonary valve in systole and diastole respectively.

Keywords: *echocardiography, idiopathic, dilatation, pulmonary artery*

SINGAPORE MED J 1996; Vol 37: 378-379

INTRODUCTION

Although idiopathic dilatation of the pulmonary artery (IDPA) is uncommon, it is important to recognise this condition because it has an excellent prognosis compared to other conditions such as congenital pulmonary valve anomalies and pulmonary hypertension for which it may be mistaken clinically. In recent years, it has been well established that two-dimensional echocardiography (2D echo) is extremely useful for the diagnosis of the great majority of simple and complex congenital heart diseases. However, echocardiographic findings have rarely been reported in patients with IDPA[1].

CASE REPORTS

Case 1

A 22-year-old asymptomatic man was referred for evaluation because of a cardiac murmur. On auscultation of the heart, a soft mid systolic murmur and a crescendo-decrescendo early diastolic murmur were heard at the left sternal edge. There was no clinical evidence of pulmonary hypertension. The blood pressure reading was 130/80 mmHg. The chest X-ray showed a dilated pulmonary artery, a normal-sized heart and no pulmonary plethora. The 12 lead ECG showed incomplete right bundle branch block but without any evidence of right ventricular hypertrophy. The patient was diagnosed as having IDPA.

Two-dimensional echocardiography was then performed. The pulmonary artery was dilated and measured about 4 cm in diameter (Fig 1). The right ventricle was mildly dilated. No other abnormalities were detected. Specifically, the pulmonary valve was morphologically normal and there was no evidence of an intracardiac shunt such as an atrial septal defect (ASD), ventricular septal defect (VSD) or patent ductus arteriosus (PDA). M-mode evaluation of the pulmonary valve showed no evidence of pulmonary hypertension. Pulsed-Doppler echocardiography was then performed and it showed diastolic turbulence at the right ventricular outflow tract below the pulmonary valve indicating pulmonary regurgitation. Doppler colour flow imaging showed a diastolic jet emanating from the pulmonary valve to

Fig 1 – (Case 1). Short axis view showing dilated pulmonary artery (PA) which measures about 4 cm in diameter. Ao = aorta.

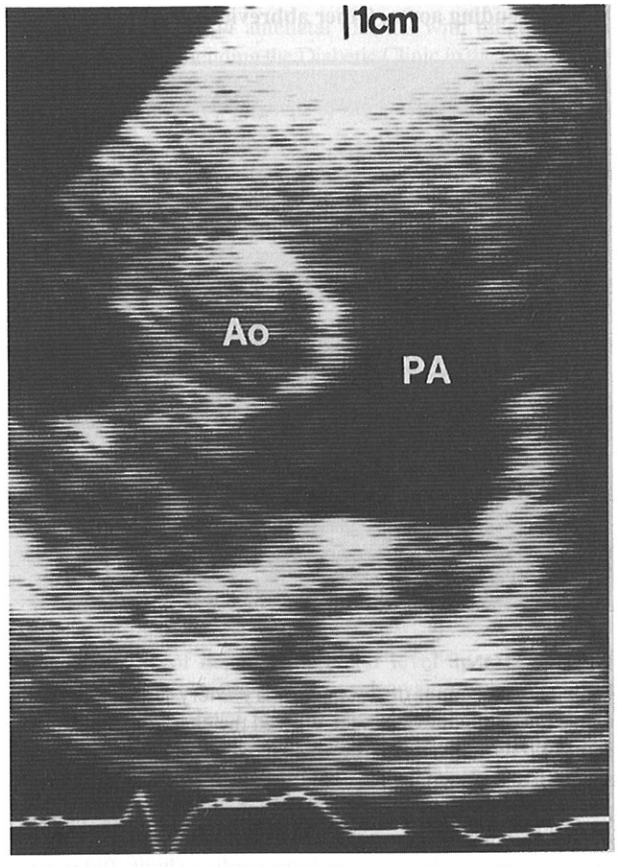

Cardiac Department
National University Hospital
5 Lower Kent Ridge Road
Singapore 119074

B L Chia, MBBS, FRACP, FACC
Professor and Chief

6 Napier Road #03-05
Gleneagles Medical Centre
Singapore 258499

B K Ee, MBBS, FRCP, FACC
Consultant Cardiologist

Correspondence to: Prof B L Chia

the right ventricular outflow tract. The length of the jet was about 3 cm.

Case 2

A 12-year-old asymptomatic girl was referred for a cardiac murmur. Examination of the heart revealed an ejection systolic click, a soft ejection systolic murmur and a crescendo-decrescendo early diastolic murmur at the third and fourth left intercostal spaces just lateral to the sternal edge. There was no clinical evidence of pulmonary hypertension. The chest X-ray showed a dilated pulmonary artery and no other abnormalities. The 12 lead ECG was normal. A diagnosis of IDPA was made clinically.

Two-dimensional echocardiographic examination showed a dilated pulmonary artery (about 4 cm in diameter) (Fig 2) and a mildly enlarged right ventricle and right atrium. There were no other abnormalities. Specifically, there was no evidence of an ASD, VSD or PDA. The pulmonary valve was morphologically normal and it did not show any evidence of pulmonary hypertension on the M-mode examination. Saline was then injected into a peripheral vein. The microbubbles which were generated oscillated up and down across the pulmonary valve during ventricular systole and diastole respectively indicating pulmonary regurgitation (Fig 3).

Fig 2 - (Case 2). Short axis view showing dilatation of the main pulmonary artery (4 cm in diameter). DA = descending aorta. Other abbreviations as in Fig 1.

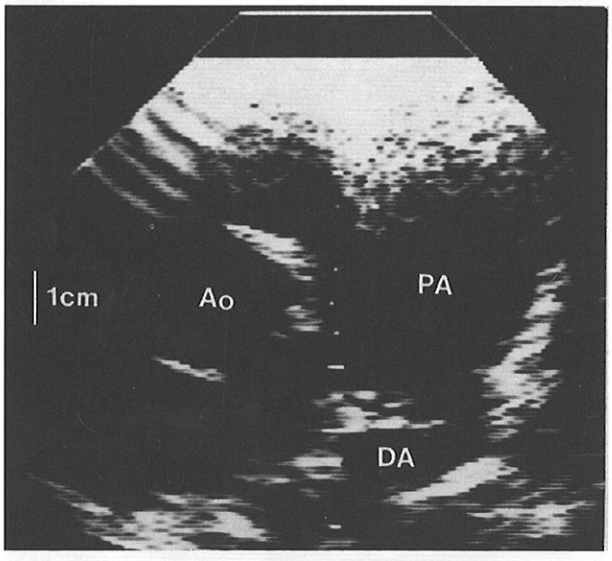

DISCUSSION

Idiopathic dilatation of the pulmonary artery is an uncommon condition. Both our two cases showed the characteristic clinical signs of IDPA. Two-dimensional echocardiographic examination showed that the main pulmonary artery was dilated in both patients. In addition, both cases also showed a mildly enlarged right ventricle. All the other cardiac structures were normal and there was no evidence of an intra-cardiac shunt. Pulmonary regurgitation was confirmed in Case 1 by both pulsed-Doppler echocardiographic and Doppler colour flow imaging studies. Although a diastolic jet can be seen in a large number of normal subjects using Doppler colour flow imaging technique, the length of the jet usually does not exceed 1 cm. In Case 1, the length of the jet was about 3 cm and this was regarded as representing organic pulmonary regurgitation. In Case 2, pulmonary regurgitation was demonstrated by saline injection into a peripheral vein resulting in microbubbles oscillating up and down across the pulmonary valve.

Fig 3 – Short axis view showing microbubbles (which were generated from an intravenous injection of saline into a peripheral vein) in the right atrium (RA), right ventricular outflow tract (RVOT), main pulmonary artery (MPA) and the right pulmonary artery (RPA). In real time, the microbubbles can be seen to oscillate up and down across the pulmonary valve in systole and diastole respectively, indicating pulmonary regurgitation. Ao = aorta, LA = left atrium.

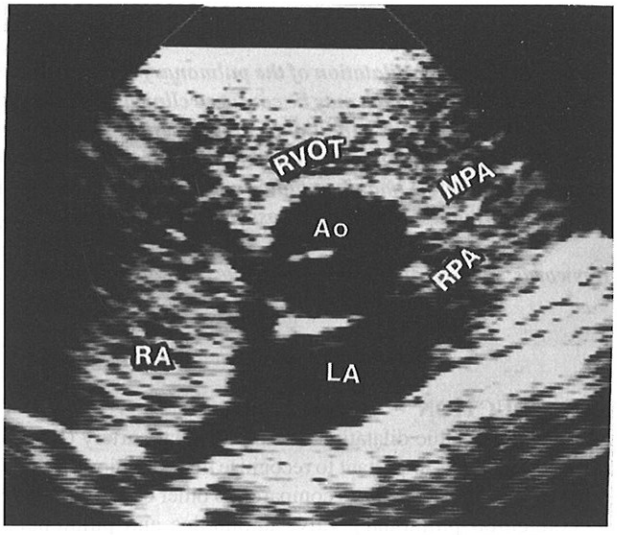

From the above observations, it is reasonable to conclude that two-dimensional, M-mode and Doppler echocardiographic examination is a useful tool for the diagnosis of IDPA. The echocardiographic findings suggesting this condition are: (1) an enlarged pulmonary artery, (2) an enlarged right ventricle, the degree of enlargement depending on the severity of pulmonary regurgitation, (3) pulmonary regurgitation which can be detected by pulsed-Doppler echocardiography and Doppler colour flow imaging, and (4) an absence of any evidence of pulmonary hypertension (using M-mode echocardiography) or other cardiac abnormalities.

Finally, using Doppler echocardiography, it is possible to exclude pulmonary hypertension by estimating the actual systolic pressure of the pulmonary artery, if the patient has tricuspid regurgitation but no pulmonary valvular stenosis. This is done first by determining the peak velocity and the systolic pressure gradient across the tricuspid valve and also by clinically measuring the jugular venous pulse pressure. From the data obtained and using a very simple formula, the pulmonary artery systolic pressure can be calculated. However, this was not done in our 2 patients.

References

1. Asayama J, Matsuma T, Endo N, Watanabe T, Matsukubo H, Furukawa K, et al. Echocardiographic findings of idiopathic dilatation of the pulmonary artery. Chest, 1977; 71: 671-3.
2. Silove ED, DeGiovanni JV, Shiu MF, Yi MM. Diagnosis of right ventricular outflow obstruction in infants by cross-sectional echocardiography. Br Heart J 1983; 50: 416-20.
3. Johnson GL, Kwan OL, Handshoe S, Noonan JA, De Maria AN. Accuracy of combined two-dimensional echocardiography and continuous wave Doppler recording in the estimation of pressure gradient in right ventricular outlet obstruction. J Am Coll Cardiol 1984; 3: 1013-8.