

INTRACRANIAL GERMINOMA METASTASIZING VIA A VENTRICULO-PERITONEAL SHUNT

K T Wong, K B H Koh, S H Lee, C P Chee

ABSTRACT

Primary germinomas of the central nervous system carry a good prognosis because of their radiosensitivity. Recurrences are rare and extraneural metastases are even more unusual. One of the possible routes of extraneural spread is via ventriculo-peritoneal shunts which may be required to reduce intracranial pressure. One such case of germinoma metastasizing via a ventriculo-peritoneal shunt is reported. Patients with intracranial germinomas and ventriculo-peritoneal shunts should have close surveillance of their abdomens and may require systemic chemotherapy.

Keywords: intracranial germinoma, metastasis

SINGAPORE MED J 1996; Vol 37: 441-442

INTRODUCTION

Primary germinomas of the central nervous system are rare tumours occurring mainly in the suprasellar and pineal region. These tumours are usually treated by radiotherapy because they are very radiosensitive, but they may require additional procedures like ventricular shunting for obstructive hydrocephalus. Spread of these tumours via ventriculo-peritoneal shunts is unusual. We report a case of a suprasellar germinoma with shunt metastasis.

CASE REPORT

A 23-year-old Chinese male was referred to our hospital for major depression. He was noticed to be depressed and withdrawn, lethargic and forgetful for a period of six months by his family. We found him to be withdrawn, unwilling to communicate and preoccupied with his own thoughts. He was mildly ataxic and had a slightly restricted upward gaze. There were no other neurological signs or papilloedema. A CT-scan of his brain revealed a suprasellar mass (Fig 1) which extended around his lateral ventricles causing hydrocephalus (Fig 2). Bilateral ventriculo-peritoneal Hakim shunts with a Y-connector were inserted and the tumour was biopsied. Histologically, the tumour was composed of regular polygonal cells rich in glycogen. A diagnosis of germinoma was made and the patient then underwent a course of radiotherapy to the brain. He received a total of 5000cGy. Neurologically, he improved and a repeat CT-scan after 3 months showed mild cerebral atrophy with no evidence of residual tumour.

He was readmitted 4 months later for an acute abdomen and underwent a laparotomy which revealed an acute gangrenous cholecystitis. A cholecystectomy was performed and he recovered uneventfully.

The patient presented again 13 months after the initial

Fig 1 – CT scan showing tumour in suprasellar region.

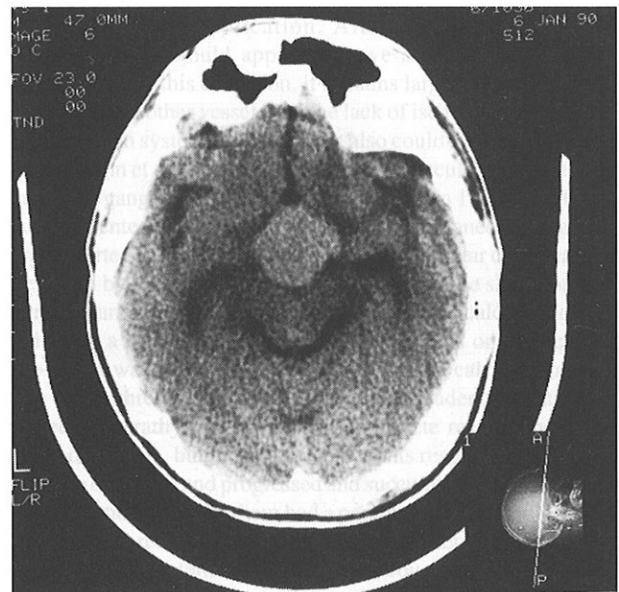
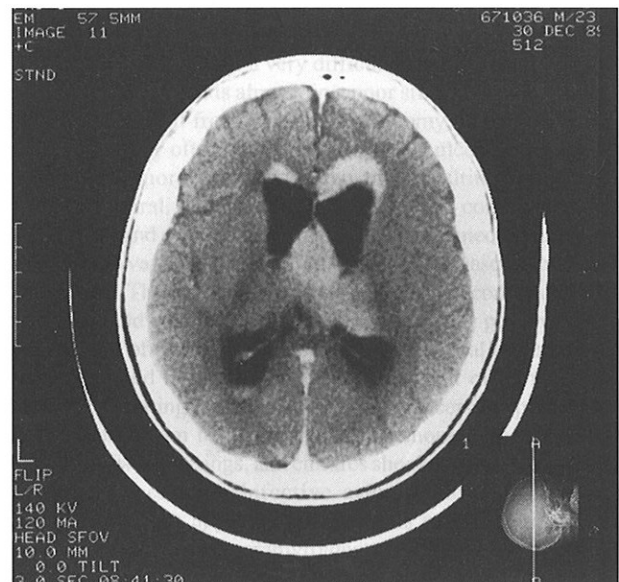


Fig 2 – CT scan showing extension of tumour around ventricles with obstructive hydrocephalus.



Department of Pathology
University Hospital
Lembah Pantai
59100 Kuala Lumpur
Malaysia

K T Wong, MRCP (Path)

Department of Surgery
University Hospital

K B H Koh, FRCS (Edin)

S H Lee, FRCS (Edin)

C P Chee, FRCS (Edin)

Correspondence to: Dr K T Wong

Fig 3 – CT scan of abdomen showing intraperitoneal metastasis (arrow)

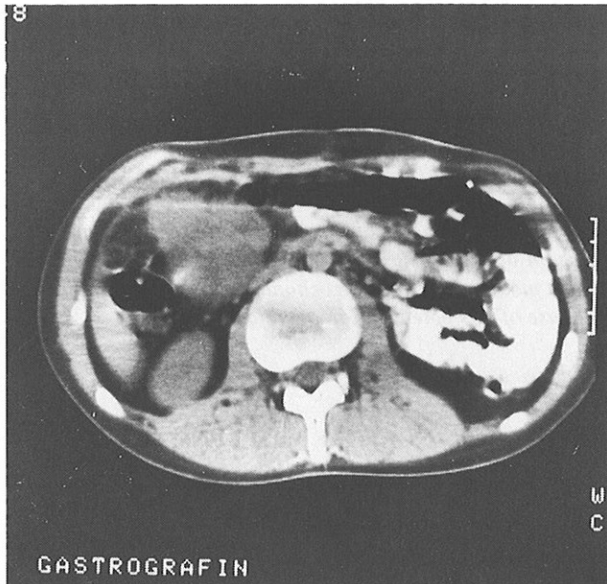
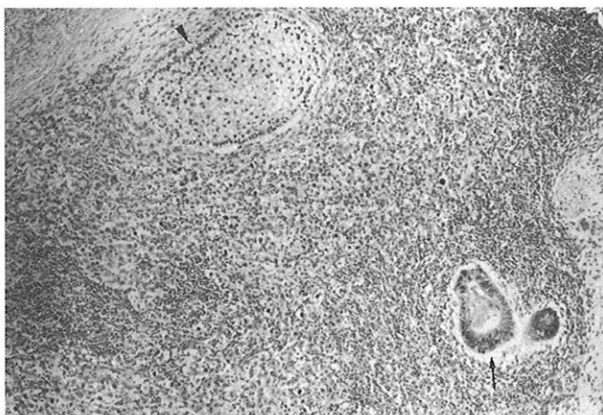


Fig 4 – Immature cartilage (arrowhead) and epithelial elements (arrow) in the background of germinoma cells. (H&E x 20).



admission with pain and a mass in the right hypochondrium. A CT-scan confirmed the presence of an intraperitoneal tumour just deep to the anterior abdominal wall (Fig 3). He underwent a laparotomy and a large vascular tumour was found in the right hypochondrium adherent to the transverse mesocolon and omentum. The end of the ventriculo-peritoneal shunt was lying adjacent to it. There were no other deposits. The tumour was excised. It measured 12x9x7cm and had a variegated cut surface with areas of haemorrhage. Histological examination showed a mixed germ cell tumour consisting of an immature teratoma, embryonal carcinoma and germinoma (Fig 4).

Post-operatively, the patient developed intestinal obstruction with vomiting. A re-laparotomy was performed on the ninth post-operative day but unfortunately, he aspirated just prior to surgery. Intestinal adhesions to the tumour bed were found and lysed but the patient succumbed to aspiration pneumonia 2 days later.

DISCUSSION

Primary central nervous system germinoma are radiosensitive tumours and are known to be cured by radiotherapy with long term survivals and very low recurrence rates. Most of these

recurrences are intracranial and extraneural metastases are rare. One of the routes of extraneural spread is via a ventriculo-peritoneal shunt.

Metastases of intracranial tumours through ventriculo-peritoneal shunts are very rare. This was first described by Wolf in 1954 in a patient with glioblastoma⁽¹⁾ and subsequently has been reported mainly with medulloblastomas⁽²⁾ which also has a predisposition to disseminate via the cerebrospinal fluid. Only a few reports of intracranial germinomas spreading to the peritoneal cavity via ventriculo-peritoneal shunts have been reported⁽³⁻¹⁰⁾. These patients usually present with abdominal masses which represent metastatic germinoma and may either be single or multiple throughout the peritoneal cavity. In many patients as in ours, the primary tumour had completely regressed following radiotherapy and it is unfortunate that the ventriculo-peritoneal shunt had opened up a new channel for tumour spread. This phenomenon of tumour embolism via the ventriculo-peritoneal shunt seems to be a characteristic of tumours which shed cells into the cerebrospinal fluid like medulloblastomas.

The incorporation of microfilters into the shunts may prevent this phenomenon and should be investigated further^(2,11,12). In view of this complication, all patients with intracranial tumours who require shunts should be forewarned of the possibility of shunt metastases. Regular imaging of the abdomen may be useful in detecting early metastases. In addition, it has been suggested that chemotherapy should be given to patients with germinoma who also have a ventriculo-peritoneal shunt because of the risk of extraneural metastases⁽¹³⁾.

REFERENCES

1. Wolf A, Cowen D, Stewart WB. Glioblastoma with extraneural metastases by way of ventriculo-pleural anastomosis. *Trans Am Neurol Assoc* 1954; 79: 140-2.
2. Hoffman HJ, Hendrick EB, Humphreys RP. Metastasis via ventriculo-peritoneal shunt in patients with medulloblastoma. *J Neurosurg* 1976; 44: 562-6.
3. Salazar OM, Castro-Vita H, Bakos RS, Feldstein ML, Keller B, Rubon P. Radiation therapy for tumours of the pineal region. *Int J Radiat Oncol Biol Phys* 1979; 5: 491-9.
4. Triolo PJ, Schulz EE. Metastatic germinoma (pinealoma) via a ventriculo-peritoneal shunt. *Am J Radiol* 1980; 135: 854-5.
5. Wood BP, Haller JO, Berdon WE, Lin SR. Shunt metastases of pineal tumours presenting as a pelvic mass. *Pediatr Radiol* 1979; 8: 108-9.
6. Kun LE, Tang TT, Sty JR, Camitta BM. Primary cerebral germinoma and ventriculo-peritoneal shunt metastasis. *Cancer* 1981; 48: 213-6.
7. Haimovic IC, Sharer L, Hyman RA, Beresford HR. Metastasis of intracranial germinoma through a ventriculo-peritoneal shunt. *Cancer* 1981; 48: 1033-6.
8. Talamo TS, Mendelow H. Primary intracranial germinoma with massive ventriculo-peritoneal shunt metastases. *J Surg Oncol* 1985; 28: 39-41.
9. Neuwelt EA, Glasberg M, Frenkel E, Clark WK. Malignant pineal region tumours. A clinico-pathological study. *J Neurosurg* 1979; 51: 597-607.
10. Ung AO, Triscott JA, Leditschke JF, Smith JA. Metastasis of pineal germinoma via ventriculoperitoneal shunt. *Aust N Z J Surg* 1993; 63: 409-12.
11. Campbell AN, Chan HLS, Becker E, et al. Extracranial metastases in childhood intracranial tumour. *Cancer* 1984; 53: 974-81.
12. Park TS, Hoffman JJ, Hendrick EB, Humphreys RLP, Becker LE. Medulloblastoma: clinical presentation and management. *J Neurosurg* 1983; 58: 543-52.
13. Ono N, Isobe I, Uki J, Kurihara H, Shimizu T, Kohno K. Recurrence of primary intracranial germinomas after complete response with radiotherapy: recurrence patterns and therapy. *Neurosurg* 1994; 35: 615-21.