

FATAL LACTIC ACIDOSIS FROM IMPORTED PHENFORMIN - REPORT OF TWO CASES

K G Yeoh, K O Lee, J S Cheah

ABSTRACT

This report describes two diabetic patients who presented with severe lactic acidosis. Both patients had been taking a medicine (phenformin) which they had obtained from China, and which has been withdrawn from Singapore since 1977. Both cases were admitted with severe metabolic acidosis and were treated with intravenous sodium bicarbonate and intensive care support with unsuccessful outcomes.

Keywords: diabetes mellitus, lactic acidosis, phenformin

SINGAPORE MED J 1996; Vol 37: 482-484

INTRODUCTION

The clinical picture of severe metabolic acidosis without ketosis in phenformin-treated diabetics was first described in 1959 by Walker and Linton⁽¹⁾. The accumulation of lactic acid was soon recognised as the cause of the acidosis, and by 1977 the increasing number of reported cases of lactic acidosis in phenformin-treated diabetics⁽²⁾ led to the withdrawal of phenformin from the market in the USA⁽³⁾, the UK and many countries including Singapore. However, the drug is still produced and available in some countries, including China. We report 2 cases of phenformin-induced lactic acidosis in Singapore who had obtained the drug from China.

CASE REPORTS

Patient A

An 80-year-old Chinese man with long-standing non-insulin dependent diabetes mellitus, hypertension and ischaemic heart disease was admitted to hospital in June 1990 for confusion, restlessness, dyspnoea and vomiting of a few hours duration. Clinical examination revealed a confused patient with marked dehydration and Kussmaul's respiration. The pulse rate was 120 beats per minute, the blood pressure was 150/74 mmHg, cardiac examination was normal and the lungs were clear except for scattered bilateral rhonchi. The patient was disorientated in person, time and place and he was mentally confused. Fundoscopy revealed no papilloedema and no focal neurological signs were found. Initial investigations showed a trace of ketones in the urine and a severe metabolic acidosis (pH 6.82, base excess -33.0 mmol/L, standard bicarbonate 1.8 mmol/L, PaO₂ 119.8 mmHg, PaCO₂ 11.7 mmHg, oxygen saturation 98%). The serum urea was 16.4 mmol/L, sodium 149 mmol/L, potassium 6.1 mmol/L, chloride 108 mmol/L, glucose 2.6 mmol/L, creatinine 553 µmol/L and the calculated anion gap was 45 mmol/L. The haemoglobin was 12.6 g/dL, total white count 27.15 x 10⁹/L with 81% polymorphs and the platelet count was 352 x 10⁹/L.

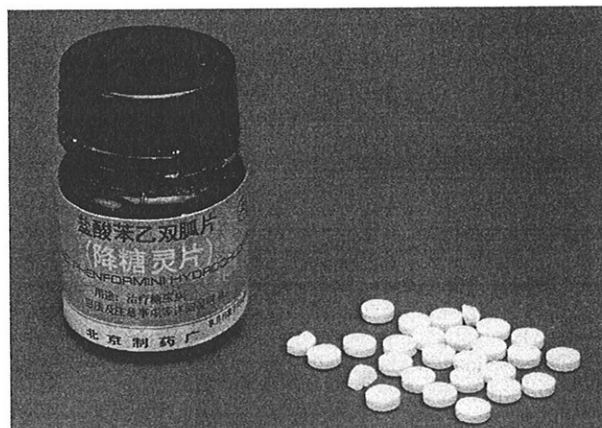
Specific questioning revealed that the patient had been taking an oral hypoglycaemic drug obtained from China for the past several weeks. A provisional diagnosis of lactic acidosis from biguanide ingestion was made and the relatives were asked to bring the medicine for identification, which was later shown to be phenformin (Fig 1). Subsequent investigations revealed the serum lactate level to be 23.7 mmol/L (normal range 0-2.5 mmol/L).

The patient was immediately started on vigorous intravenous rehydration, glucose and bicarbonate replacement with frequent checking of arterial blood gases. He was also started on empirical antibiotics in view of his ill condition and raised total white count after blood and urine cultures were taken. Over a period of 13 hours, the patient received a total of 900 mL of 8.4% sodium bicarbonate solution (in addition to other intravenous fluids) with serial improvement of pH and standard bicarbonate from pH 6.928, base excess -27.2 and standard bicarbonate 3.3 mmol/L (10 hours after admission) to pH 7.091, base excess -19.6 and standard bicarbonate 10.5 mmol/L (13 hours after admission). Despite the apparent improvement in the acid-base status, the patient deteriorated, went into bradycardia 13 hours after admission and resuscitation was unsuccessful.

Patient B

A 76-year-old Chinese man with a 10-year history of non-insulin dependent diabetes mellitus had been taking a medicine obtained from China for the past one year. He was brought to hospital by relatives after having been generally unwell for the past three days. On admission, the patient was drowsy and restless, with severe dehydration and acidotic breathing. The pulse rate was

Fig 1 - Phenformin tablets and container



Department of Medicine
National University Hospital
5 Lower Kent Ridge Road
Singapore 119074

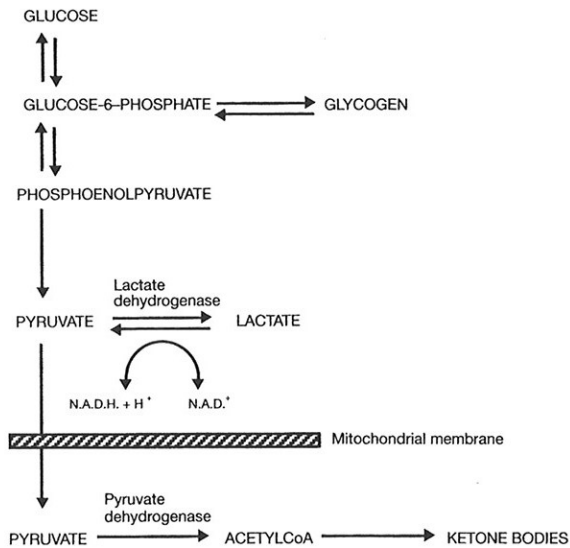
K G Yeoh, MBBS, M Med (Int Med)
Lecturer

K O Lee, MD, FRACP
Associate Professor

J S Cheah, MD, FRACP
Professor

Correspondence to: Dr K G Yeoh

Fig 2 – Lactate metabolism



110 beats per minute, the blood pressure was 100/60 mmHg and examination of the heart and lungs were normal. There were no focal neurological signs. Investigations showed no ketones in the urine and a severe metabolic acidosis (pH 6.68, base excess -37 mmol/L, standard bicarbonate 2.9 mmol/L, PaO₂ 146 mmHg, PaCO₂ 11.8 mmHg). The serum urea was 9.4 mmol/L, sodium 143 mmol/L, potassium 6.0 mmol/L, chloride 102 mmol/L, glucose 13.3 mmol/L, creatinine 351 μmol/L and the calculated anion gap was 44 mmol/L. The serum lactate level was 29 mmol/L. The haemoglobin was 12.1 g/dL, total white count 14.95 x 10⁹/L with 61% polymorphs and the platelet count was 208 x 10⁹/L.

The patient was immediately started on intravenous fluids and sodium bicarbonate which raised the pH to 7.263 with base excess -2.9 mmol/L and standard bicarbonate 22.4 mmol/L within two hours. Soon after however, the patient developed bradycardia and hypotension and succumbed despite emergency cardiac pacing and resuscitative measures. Subsequently, the family brought the medicine which he had been consuming during the past year and this was identical to the drug taken by Patient A.

DISCUSSION

Although serum levels of phenformin were not measured in either patient, phenformin was the most probable cause of lactic acidosis in both patients in the absence of shock (neither patient was hypotensive on admission), heart failure, septicaemia (both had leukocytosis but blood cultures were negative) or previously known renal or liver disease. However, the obtunded mental state of both patients precluded the taking of a direct history as to the dose of phenformin ingested or whether any other drugs had been taken.

Lactic acidosis is a well-known complication in diabetics treated with biguanides and it is associated with a mortality rate of more than 50%^(2,4). The high incidence of severe and often fatal lactic acidosis in phenformin-treated diabetics had led to the withdrawal of phenformin in many countries. However, as demonstrated by the above two cases, the possibility of lactic acidosis must still be considered in patients with metabolic acidosis and a widened anion gap which is not attributable to ketoacidosis, uraemia, alcohol intake or other common causes, and it is necessary to specifically ask if the patient had been taking any oral hypoglycaemic drug from overseas sources.

One previous local case of lactic acidosis in a non-diabetic woman which resulted from ingestion of phenformin was

reported in this journal in 1986⁽⁵⁾. Following the report, a search of Chinese medicine shops revealed that many of these shops had stocks of the drug. Moreover, the drug is often unwittingly brought back from China as was the case for both our patients. Therefore the education of elderly Chinese diabetics is important, especially at outpatient and Diabetic Society levels.

The traditional recommended treatment of lactic acidosis, besides correction of the underlying cause, has been intravenous sodium bicarbonate⁽⁶⁻¹⁰⁾. The rationale of alkali therapy is to counteract the adverse haemodynamic effects of severe acidosis: decreased cardiac contractility and cardiac output, hypotension, decreased hepatic and renal blood flow, bradycardia and increased susceptibility to ventricular arrhythmias. Recently, however, several authors have questioned the efficacy of such therapy, arguing that high dose bicarbonate therapy has not been demonstrated to unequivocally improve survival and may actually worsen morbidity and mortality by causing paradoxical intracellular acidification, acidification of spinal fluid, increasing carbon dioxide production and increasing lactic acid production^(4,11,12). In animals with biguanide-induced lactic acidosis, sodium bicarbonate has been shown to cause increasing lactic acidemia, a fall in intracellular pH of liver and erythrocytes, and cardiovascular collapse^(13,14).

Other authors hold the view that alkali therapy is necessary to mitigate the potentially fatal effects of severe acidosis, allowing time to correct the root cause of acidosis⁽¹⁵⁻¹⁷⁾.

Alternative therapies which have been tried include tromethamine, dichloroacetate and dialysis. The alkali tromethamine (THAM) has been used successfully in the treatment of phenformin-induced lactic acidosis⁽¹⁸⁾. It holds promise as an alternate form of alkali therapy with the benefit of no additional sodium load and it has been shown in animal models to increase intracellular pH⁽¹⁹⁾ and to be positively inotropic to dog heart⁽²⁰⁾.

Dichloroacetate (DCA) reduces circulating lactate concentration by stimulating the activity of pyruvate dehydrogenase, the enzyme that catalyses the rate limiting step in the oxidation of lactate and pyruvate (Fig 2). DCA lowers plasma lactate levels in healthy human subjects and in diabetics^(21,22). It has been shown to prevent the development of phenformin-induced lactic acidosis⁽²³⁾ and to reverse established lactic acidosis in rats⁽²⁴⁾. In human studies, it has been successfully used to decrease hyperlactatemia from other causes such as sepsis, circulatory arrest, hypoperfusion and liver failure⁽²⁵⁾. However, DCA was tried unsuccessfully in a diabetic with severe buformin-induced lactic acidosis⁽²⁶⁾.

There have been several reports on the successful use of haemodialysis^(27,28) and peritoneal dialysis^(29,30) in the treatment of biguanide-induced lactic acidosis. Both are effective in removing lactate but it is uncertain whether biguanide drugs are removed by dialysis.

At present, the question of what constitutes optimal treatment in cases of biguanide-induced lactic acidosis remains unsettled. We believe that intravenous sodium bicarbonate is necessary to reverse acidosis, which otherwise has fatal effects on the heart, while the underlying cause is being corrected. If a patient does not respond to this therapy, the mortality rate is high and the use of dichloroacetate is reasonable.

Patient education at primary care and Diabetic Society levels is important to prevent inadvertent use of phenformin obtained from overseas sources.

REFERENCES

1. Walker RS, Linton AL. Phenethylbiguanide: A dangerous side-effect. *Br Med J* 1959; II: 1005-6.

2. Luft D, Schummeling RM, Eggstein M. Lactic acidosis in biguanide treated diabetics: A review of 330 cases. *Diabetologia* 1978; 14: 75-87.
3. Food and Drug Administration. Phenformin: removal from general market. *FDA Drug Bulletin* 1977; 7: 14-6.
4. Stacpoole PW. Lactic acidosis: The case against bicarbonate therapy (editorial). *Ann Intern Med* 1986; 105: 276-9.
5. Lim HS, Chew SK, Sin FL, Tan YT. Lactic acidosis from phenformin overdose - a case report. *Singapore Med J* 1986; 27: 336-40.
6. Levinsky NG. Acidosis and alkalosis. In: Wilson JD, Braunwald E, Isselbacher KJ, Petersdorf RG, Martin JB, Fauci AS, Root RK. eds. *Harrison's Principles of Internal Medicine*. 12th ed. USA: McGraw-Hill Inc, 1991: 291-3.
7. Cohen RD, Woods HF. Disturbances of acid-base homeostasis. In: Weatherall DJ, Ledingham JGG, Warrel DA. eds. *Oxford Textbook of Medicine*. Oxford: Oxford University Press, 1987: 9.173.
8. Cohen RD, Woods HF. Lactic acidosis revisited. *Diabetes* 1983; 32: 181-91.
9. Alberti KGMM, Natrass M. Lactic acidosis. *Lancet* 1977; ii: 25-8.
10. Olivia PB. Lactic acidosis. *Am J Med* 1970; 48: 208-25.
11. Jaeschke R. Bicarbonate in severe lactic acidosis. *Ann Intern Med* 1987; 107: 258-9.
12. Ryder RE. The danger of high dose sodium bicarbonate in biguanide-induced lactic acidosis. *Br J Clin Pract* 1987; 41(5): 730-7.
13. Graf H, Leach W, Arieff AI. Evidence for a detrimental effect of bicarbonate therapy in hypoxic lactic acidosis. *Science* 1985; 27: 745-56.
14. Arieff AI, Leach W, Park R, Lazarowitz VC. The systemic effects of Na HCO₃ in experimental lactic acidosis in dogs. *Am J Physiol* 1982; 242: F586-9.
15. Narins RG, Cohen JJ. Bicarbonate therapy in organic acidosis: the case for its continued use. *Ann Intern Med* 1987; 106: 615-8.
16. Narins RG, Cohen JJ. Bicarbonate therapy in severe acidosis. *Ann Intern Med* 1988; 108: 311.
17. Mizock BA. Controversies in lactic acidosis. *JAMA* 1987; 258: 497-501.
18. Westervelt FB Jr, Owen JA, Hornbaker JH, Rhodes AG. Severe lactic acidosis successfully treated with THAM and hemodialysis. *Clin Res Proc* 1965; 13: 55.
19. Robin ED, Wilson RJ, Brombery PA. Intracellular acid base relations and intracellular buffers. *Ann NY Acad Sci* 1961; 92: 539-47.
20. Ng ML, Levy MN, Zieske HA. Effects of changes of pH and of carbon dioxide tension on left ventricular performance. *Am J Physiol* 1967; 213(1): 115-20.
21. Wells PG, Moore GW, Rabin O, Wilkinson GR, Oates JA, Stacpoole PW. Metabolic effects and pharmacokinetics of intravenously administered dichloroacetate in humans. *Diabetologia* 1980; 19: 109-13.
22. Stacpoole PW, Moore GW, Kornhauser DM. Metabolic effects of dichloroacetate in patients with diabetes mellitus and hyperlipoproteinemia. *N Engl J Med* 1978; 298: 526-30.
23. Holloway PAH, Alberti KGMM. Phenformin-induced lactic acidosis: prevention by dichloroacetate. *Clin Sc Mol Med* 1976; 50: 33.
24. Holloway PAH, Alberti KGMM. Reversal of phenformin-induced hyperlactatemia by dichloroacetate in normal and diabetic rats. *Diabetologia* 1975; 11: 350-1.
25. Stacpoole PW, Lorenz AC, Thomas RG, Harman EM. Dichloroacetate in the treatment of lactic acidosis. *Ann Intern Med* 1988; 108: 58-63.
26. Irsigler K, Kasper L, Kritiz H. Dichloroacetate in biguanide-induced lactic acidosis. *Lancet* 1977; i:433.
27. Milisci RE, Decherd J, McFadden ER, Strader WJ, Nusynowitz ML. Phenformin-induced lactic acidosis: Recovery with massive bicarbonate therapy and hemodialysis. *Am J Med Sc* 1973; 265: 447-53.
28. Columbi A, Tholen H. Hemodialysis in the treatment of lactic acidosis associated with acute hepatic and renal failure. *Postgrad Med* 1971; 47: 628-31.
29. Hayat JC. The treatment of lactic acidosis in the diabetic patient by peritoneal dialysis using sodium acetate. A report of two cases. *Diabetologia* 1974; 10: 485-7.
30. Sheppard JM, Lawrence JR, Oon RCS, Thomas DW, Row PG, Wise PH. Lactic acidosis: Recovery associated with use of peritoneal dialysis. *Aust NZ J Med* 1972; iv: 389-92.