

SPINAL EPIDURAL NON-HODGKIN'S LYMPHOMA: CASE REPORTS OF THREE PATIENTS PRESENTING WITH SPINAL CORD COMPRESSION

C C T Lim, B K Chong

ABSTRACT

Spinal epidural non-Hodgkin's lymphoma is an uncommon lesion. In this report, we describe three patients with a clinical picture of acute spinal cord compression as the first presentation of malignant lymphoma. The diagnosis was not suspected pre-operatively, and plain radiographs of the spine were either normal or not specific. Neuroimaging showed evidence of extradural soft tissue mass crossing multiple vertebral segments. In the light of these radiological findings, non-Hodgkin's lymphoma should be a diagnostic consideration in the older patient without prior history of malignancy who presents with a prodrome of back pain followed by spinal cord compression.

Keywords: epidural, non-Hodgkin's lymphoma, spinal cord compression, spine radiograph, neuroimaging

SINGAPORE MED J 1996; Vol 37: 497-500

INTRODUCTION

Lymphoma involves the central nervous system in 5%-11% of cases, either at presentation of disease or during its course⁽¹⁻³⁾. The spinal epidural tissue is involved in 0.1%-3.3%. Several authors have described cord compression as the presenting symptom of malignant lymphoma. In one study, 85% of patients with non-Hodgkin's lymphoma presenting with spinal cord compression had been previously undiagnosed before the onset of compression symptoms⁽⁴⁾.

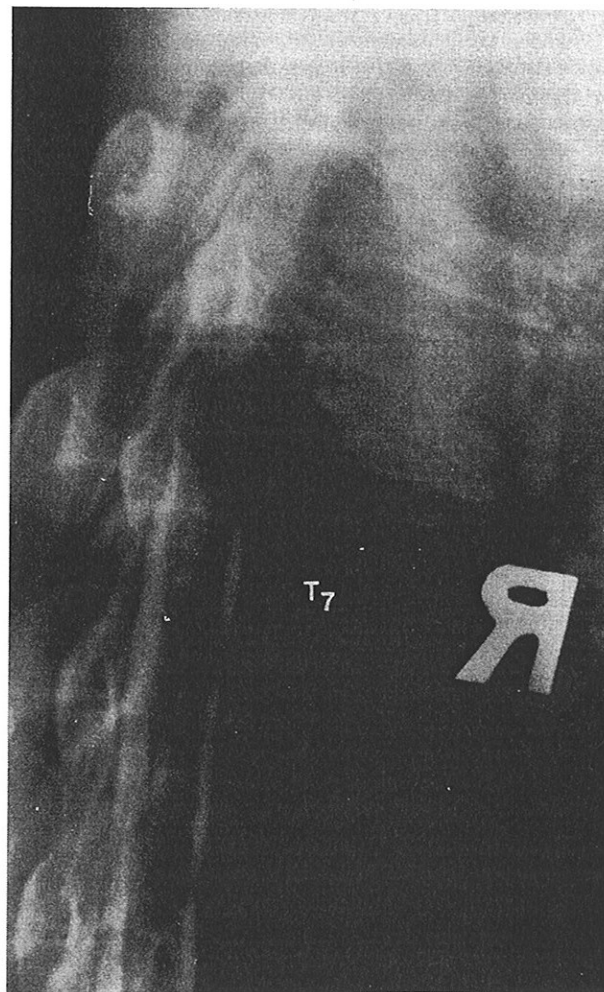
Non-Hodgkin's lymphoma of the nervous system can be either primary or metastatic⁽⁵⁾. There is considerable controversy surrounding the existence of primary spinal epidural non-Hodgkin's lymphoma, with some authors claiming that the disease is merely an extension of undetected retroperitoneal or vertebral body lymphoma^(6,7). The presence of unrecognised pre-existing disease despite clinical, laboratory and radiological evidence is possible⁽⁸⁾.

We report three patients who presented with acute spinal cord compression in the absence of clinical suspicion of lymphoma. The laminectomy biopsy specimen in each of the cases provided the first evidence of the patient's disease. To our knowledge, such cases have not been collected and described locally.

Case 1

A 59-year-old Chinese swimming pool maintenance man presented with weakness of both lower limbs for 3 days and a sensory level at T6-7. He also had muscle wasting and hyper-reflexia. The routine blood count and liver function tests were normal. Plain radiographs of the chest and lumbo-sacral spine were unremarkable. A myelogram demonstrated complete extradural block at T6-7 (Fig 1). Computed tomography performed the same day showed an extradural soft-tissue tumour

Fig 1 – Lateral myelogram of Case 1 showing complete extradural block at T6-7.



extending from T4-7 almost filling the entire spinal canal, including the recesses. It was encircling the cord and thecal sac almost completely at the level of T6 (Fig 2). There was no significant bony destruction seen and the paravertebral soft tissue was normal.

Decompression laminectomy was performed. A tumour

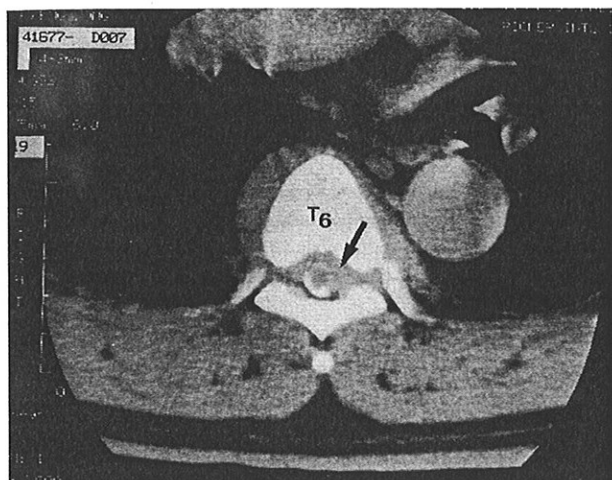
Department of Diagnostic Imaging
Tan Tock Seng Hospital
Moulmein Road
Singapore 308099

C C T Lim, MBBS, M Med, FRCR
Registrar

B K Chong, MBBS, FRCR
Senior Registrar

Correspondence to: Dr C C T Lim

Fig 2 – CT scan at T6 of Case 1 shows extradural soft-tissue tumour (arrow). There was no significant bony destruction.



pressing on the dura at T7 was found and as much as possible was excised. Histological examination revealed a low grade B cell lymphoma of the small cleaved cell type. Post-operatively, the patient's weakness improved with physiotherapy. He was treated with local radiotherapy (50 Gy) and a bone marrow aspirate and biopsy revealed no evidence of lymphocytic infiltration. CT of the abdomen and pelvis was also negative for lymphadenopathy. However, two months after diagnosis, he developed an abscess of the left leg that rapidly progressed to necrotising fasciitis, septicaemia and ARDS; and he succumbed after a short illness.

Case 2

An 82-year-old Chinese female presented with progressive bilateral lower limb weakness for one month associated with backache and recent urinary incontinence. She had suffered a compression fracture in her lumbar spine 3 years ago. She was found to have hyperreflexia and a sensory level at T7. There was no lymphadenopathy and the spleen and liver were not palpable. Her haemoglobin level was 10.2 g/dL and her ESR 92 mm. Plain radiographs of the thoraco-lumbar-sacral spine showed compression fractures of L2 and T9; the bones were osteopenic. Myelography revealed complete extra-dural block at the upper border of T10 (Fig 3 & 4). There was also slight indentation into the anterior aspect of the thecal sac at the level of L1-L2, not causing significant obstruction. Computed tomography of the T7-11 region after myelogram showed a soft tissue mass in the spinal canal that extended from the T7-8 intervertebral disc down to the level of the mid-body of T10 (Fig 5). The lesion was posterior and extended to either side of the thecal sac, displacing the cord anteriorly. It appeared to permeate and fill up the lateral recesses as well, particularly at T8-9 vertebrae. There was no definite evidence of bony erosion seen. CT of the L2 region merely showed compression fracture and disc degeneration with no significant indentation on the thecal sac.

Decompression laminectomy was performed from T5-10. An intra-spinal extradural soft tissue mass was found surrounding the cord from T5-10. Both tumour tissue and bone were sent for histological section which showed high-grade non-Hodgkin's lymphoma, diffuse large cell type. Post-operatively, the patient received local irradiation but developed new signs and symptoms of intra-spinal pathology. Radiotherapy was discontinued and she deteriorated rapidly and passed away within a month of surgery.

Fig 3 – AP myelogram of Case 2 shows complete extra-dural block at T10.

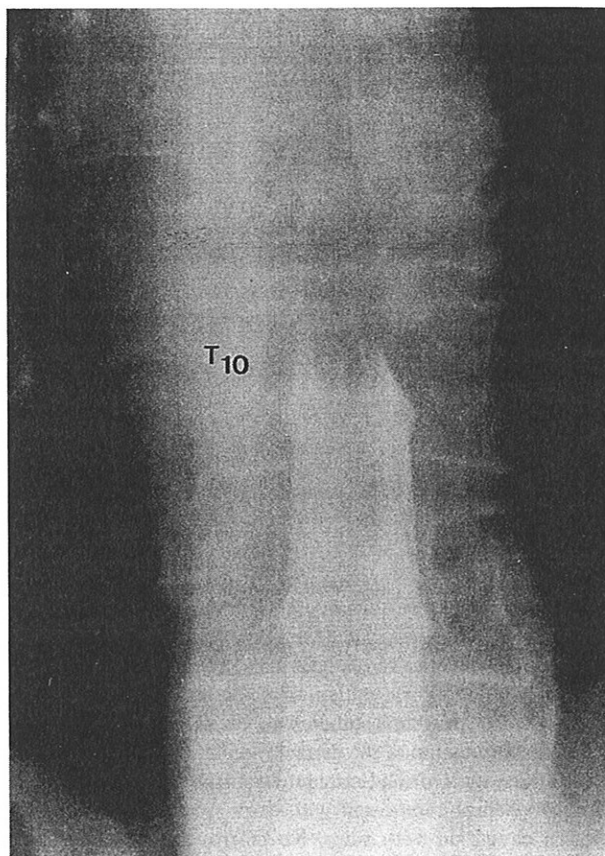


Fig 4 – Lateral myelogram of Case 2. T9 vertebral body is wedged.

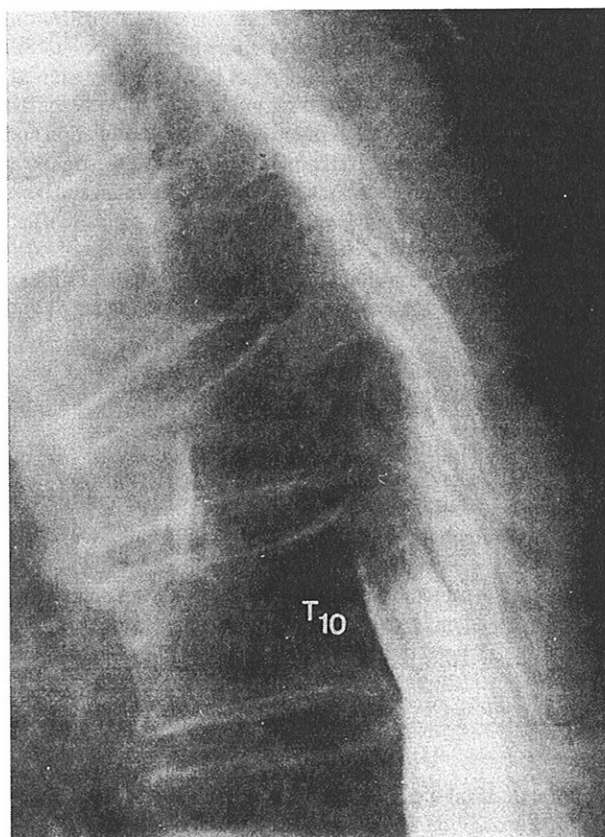
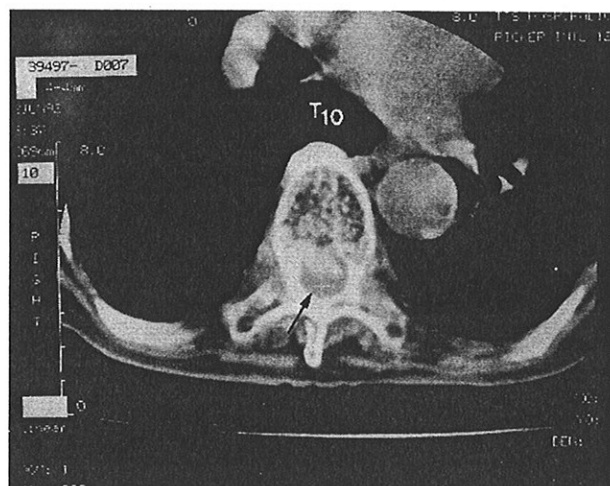


Fig 5 – CT scan of Case 2 at T10 showing a posterior extra-theal soft tissue mass displacing the cord anteriorly (arrow). Again note the absence of bony destruction.



Case 3

A 12-year-old Chinese boy presented with lower limb weakness over 4 weeks with associated backache. He had brisk reflexes and a sensory level at T5 on the left and T6 on the right. His Hb was 11.1 g/dL. A chest radiograph showed paraspinal masses from T4-8 but the mediastinum was not widened. Spinal MRI showed compression of the thoracic spinal cord from T1-10 by a posteriorly located solid extradural soft-tissue mass. There was a para-vertebral component with extra-spinal spread into the pleural cavity on both sides. No marrow involvement was demonstrated, and no mediastinal lymphadenopathy was detected.

Thoracotomy and laminectomy of T1 to T9 was performed. At surgery, infiltrative extradural tumour was found extending from T1-9. There was also posterior chest wall infiltration bilaterally along intercostal spaces and ribs from apex to 8th intercostal space. The tumour could not be completely excised. Histological section revealed high grade lymphoma Stage III EA. Post-operatively, he was given craniospinal irradiation and chemotherapy (UKALL 10 regime) for 2 years. Investigations including radionuclide bone scan, peripheral blood film and bone marrow aspirates were negative. Post-operatively, the patient had some residual thoracic scoliosis and Horner's syndrome. He also suffered episodes of cardiomyopathy and recurrent herpes zoster and sinusitis, but is otherwise well 4 years after diagnosis and surgery.

DISCUSSION

Clinical Presentation

All three patients presented with a short duration of lower limb weakness and sensory level suggesting spinal cord compression. In other series, pain was the most common initial symptom. Lower limb weakness, a discrete sensory level, hyperreflexia, and urinary symptoms were also present to varying degrees^(4,8). The site of the lymphoma in all our cases was the thoracic spine, which was in agreement with most reports^(4,9-12). Our patients had no significant past history of note and, except for slightly low haemoglobin levels in Cases 2 and 3, no suspicion of occult malignancy.

Diagnostic Imaging

With the exception of Case 2, who had collapse of T9 and L2 vertebral bodies in the presence of osteopenia, the others had

normal plain radiographs of the spine. The CT myelogram, when done, was invariably abnormal. This correlated well with the observation that normal radiograph with neuroimaging consistent with an epidural lesion in an elderly patient with back pain and no known cancer is more suggestive of primary lymphoma than metastatic disease⁽⁸⁾.

Myelography when done, was adequate in all cases to demonstrate the site and the extradural situation of the obstruction, but was not specific in determining the cause, except that it was not due to vertebral collapse. Cross sectional imaging like post-myelogram CT and MRI were advantageous in confirming the extradural tumour mass extending across several vertebral bodies, often with a widely compressive mass effect⁽¹³⁾. The advanced imaging modalities were also capable of imaging the paraspinal soft tissues.

Although the conclusive diagnosis of lymphoma was not obtained pre-operatively in any of the cases, the absence of bony destruction and the presence of extensive extradural soft tissues, did narrow down the list of differentials to a few infiltrative diseases capable of extending longitudinally within the spinal canal.

In Case 3, the chest radiograph was abnormal, raising the suspicion of posterior mediastinal tumour. A non-invasive investigation was selected, by-passing a lumbar puncture and its attendant complications. MRI with its greater anatomic detail and soft tissue contrast provides more information about bone and soft tissue involvement, and is more useful than conventional myelography⁽¹⁴⁾. Sagittal and axial sections should contribute in demonstrating the sites of cord compression and the extent of involvement of the vertebrae and paravertebral soft tissues.

However, MRI is less optimal than CT for the assessment of intrinsic bony abnormalities. Furthermore, the long acquisition time may lead to image degradation from patient motion, and pain relief may become necessary for MRI protocols in the imaging of patients with cord compression⁽¹⁴⁾.

Management

Although some authors support treatment of lymphomatous cord compression with spinal irradiation alone^(15,16), our patients underwent surgical intervention before diagnosis. Subsequently, all were sent for radiotherapy, with Case 2 discontinuing, presumably because of disseminated lymphoma. Successful treatment by chemotherapy has been reported⁽¹⁷⁾, but the role of chemotherapy in primary spinal epidural lymphoma is unresolved.

Prognosis

Compared to metastatic carcinoma with extradural cord compression, the outlook for functional recovery and life expectancy is relatively good in patients with lymphoma^(18,19). The prognosis is poorer for more aggressive tumour types^(2,3,9). Both Cases 2 and 3 had high grade lymphoma, but Case 3 was the only survivor after 1 year, although this probably has more to do with his age; patients over 40 having a poorer prognosis^(3,18).

CONCLUSIONS

Non-Hodgkin's lymphoma is an uncommon lesion causing spinal cord compression symptoms. It should be a diagnostic consideration when the following characteristics are present:

- 1) in the older patient with a syndrome of spinal cord compression, particularly in the thoracic spine, manifested by a prodrome of back pain, followed by acute neurological deterioration;
- 2) no prior history of cancer;
- 3) normal bones in plain spine radiographs;
- 4) neuroimaging consistent with an extradural compressive

lesion, especially if involving contiguous levels.

As more patients are studied with MRI, it should undoubtedly assume a greater role in the evaluation of acute cord compression. Its superior contrast resolution may also have a role in determining whether these patients truly have isolated disease within the epidural space.

REFERENCES

1. Herman TS, Hammond N, Jones SE, Butler JJ, Byrne GE, McKelvey EM. Involvement of the central nervous system by non-Hodgkin's lymphoma. *Cancer* 1979; 43: 390-7.
2. Levitt LJ, Dawson CM, Rosenthal DS, Maloney WC. CNS involvement in the non-Hodgkin's lymphomas. *Cancer* 1980; 45: 545-52.
3. Mackintosh FR, Colby TV, Podolsky WJ, Burke JS, Hoppe RT, Rosenfelt FP, et al. Central nervous system involvement in Non-Hodgkin's lymphoma: An analysis of 105 cases. *Cancer* 1982; 49: 586-95.
4. Haddad P, Thael JF, Kiely JM, Harrison EG, Miller RH. Lymphomas of the spinal epidural space. *Cancer* 1976; 38: 1862-6.
5. O'Neill BP, Illig JJ. Primary central nervous system lymphoma. *Mayo Clin Proc* 1989; 64: 1005-20.
6. Cayla J, Rondier J, Pradat P, Hanau J. Compression medullaire revelatrice d'un lymphome nodulaire epidural. *Ann Med Interne* 1989; 130: 467-74.
7. Homma S, Asano K, Fukui T, Shimbo T, Yamada T, Sato T. Spinal cord compression by primary epidural non-Hodgkin's lymphoma. *Rinsho Ketsueki* 1989; 30: 840-4.
8. Lyons M, O'Neill BP, Marsh WR, Kurtin PJ. Primary spinal epidural Non-Hodgkin's lymphoma: Report of eight patients and review of literature. *Neurosurgery* 1992; 30: 675-80.
9. Epelbaum R, Haim N, Ben-Shahar M, Ben-Arie Y, Feinsod M, Cohen Y. Non-Hodgkin's lymphoma presenting with spinal epidural involvement. *Cancer* 1986; 58: 2120-4.
10. Friedman M, Kim TH, Panahon AM. Spinal cord compression in malignant lymphoma: treatment and results. *Cancer* 1976; 37: 1485-91.
11. Grant JW, Kaech D, Jones DB. Spinal cord compression as first presentation of lymphoma - a review of 15 cases. *Histopathology* 1986; 10: 1191-202.
12. O'Brien AAJ, Daly PA, Breslin BK. Spinal cord and cauda equinal compression by non-Hodgkin's lymphoma. *Ir Med J* 1986; 79: 103-5.
13. Zimmerman RA, Bilaniuk LT. Imaging in neuroradiology Part II. *RCNA* 1988; 26: 965-1009.
14. Holtas SL, Kido DK, Simon JH. MR imaging of spinal lymphoma. *J Comput Assist Tomogr* 1986; 10: 111-5.
15. Gilbert RW, Kim JH, Psoner JB. Epidural spinal cord compression from metastatic tumour: Diagnosis and treatment. *Ann Neurol* 1978; 3: 40-51.
16. Young RF, Post EM, King GA. Treatment of spinal epidural metastases. Randomised prospective comparison of laminectomy and radiotherapy. *J Neurosurg* 1980; 53: 741-8.
17. Oviatt DL, Kirshner HS, Stein RS. Successful chemotherapeutic treatment of epidural compression in non-Hodgkin's lymphoma. *Cancer* 1982; 49: 2446-8.
18. Mullins GM, Flynn JPG, El-Mahdi AM, McQueen JD, Owens AH. Malignant lymphoma of the spinal epidural space. *Ann Intern Med* 1971; 74: 416-23.
19. Bucy PC, Jerva MJ. Primary epidural spinal lymphomasarcoma. *J Neurosurg* 1962; 19: 142-52.