

LUXATION OF THE GLOBE AND CROUZON'S DISEASE – THE FIRST REPORTED CASE IN SINGAPORE

L Lim, P K Wong

ABSTRACT

A case of spontaneous luxation of the globe and Crouzon's disease is described. The luxation was reduced under general anaesthesia. Bilateral permanent tarsorrhaphies were performed to prevent further luxations and to decrease the lagophthalmos and corneal exposure. There was also mild bilateral optic atrophy and a left superior oblique palsy. The patient exhibited turriccephaly, maxillary hypoplasia and shallow orbits with proptosis. Major reconstructive surgery is not indicated as the patient is already 9 years old and has no mental impairment.

Keywords: Crouzon's disease, subluxated globe

SINGAPORE MED J 1996; Vol 37: 553-555

INTRODUCTION

Crouzon's disease is a form of craniosynostosis syndrome. It is inherited in an autosomal dominant manner with incomplete penetrance. The bony deformities include shallow orbits and proptosis. Rarely, the globe may spontaneously luxate anteriorly. We report one case of globe luxation and management.

CASE REPORT

A 9-year-old girl was seen in the Emergency Department of the National University Hospital on 3rd October 1991 for a luxated right globe which occurred spontaneously at home on the same day after she had rubbed her eyes. On examination, there was an anterior luxation of the right globe with conjunctival chemosis and blepharospasm (Fig 1). The pupillary reflexes were normal and the cornea was clear.

She had the following characteristic features of Crouzon's disease: turriccephaly, frontal protuberance, maxillary hypoplasia and proptosis.

Manual reduction which was attempted in the Emergency Room after intravenous injection of 3 mg of dornicum was unsuccessful due to inadequate sedation. The patient was then brought to the operating theatre and reduction of the right globe was performed under general anaesthesia. The lids were retracted and digital pressure was applied over the sclera. A temporary lateral tarsorrhaphy was also performed.

The next day, further tests showed a visual acuity of 6/6 in the right eye and 6/10 in the left. There was bilateral lagophthalmos. The right optic disc margins were blurred and there was mild pallor. There was also mild pallor in the left disc.

Cover tests showed an exophoria and left hyperphoria with good recovery. The exophoria measured 20 prism diopters for near and 8 prism diopters for distance (convergence insufficiency). She had poor convergence. The left hyperphoria measured 8 prism diopters. There was a left inferior oblique

Fig 1 – Subluxated right globe.

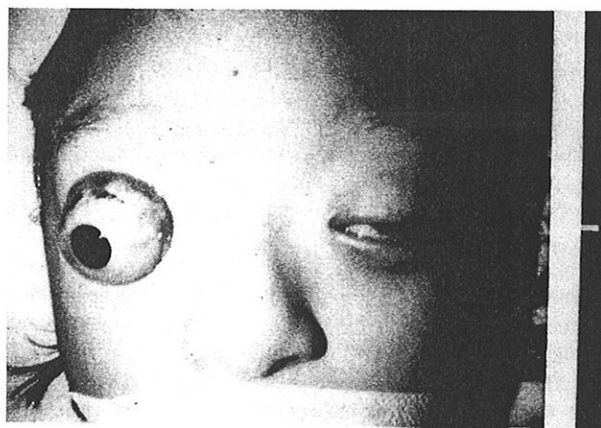
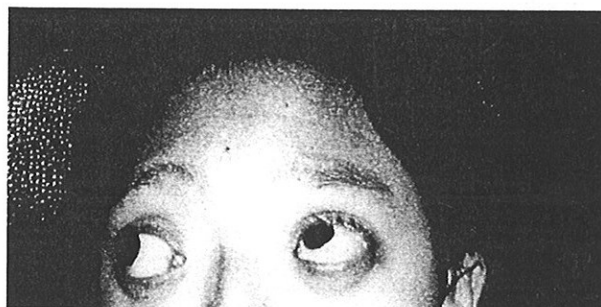

Fig 2 – Left inferior oblique overaction



overaction (Fig 2) and a right head tilt. There was a limitation in movement of the left eye on adduction and depression (Fig 3). The Frisby stereotest showed a gross stereopsis of 300 seconds.

Hertel's exophthalmometry readings were: 23 mm on the right and 20 mm on the left with a lateral intercanthal distance of 112 mm. Goldmann fields were normal. The Ishihara test was normal. However, the Farnsworth-Munsell 100 hue test showed mild blue-yellow deficiencies in both eyes. The Arden contrast sensitivity test was normal. Skull X-rays showed a premature fusion of the coronal and lambdoid sutures and turriccephaly with prominent convolutional markings (Fig 4).

She had previously been offered corrective surgery but that was refused by her parents. Her birth and development were normal. She had normal intelligence and was doing well in school. There was no family history of Crouzon's disease.

In view of her pale discs, she was referred to a neurosurgeon

Department of Ophthalmology
National University Hospital
5 Lower Kent Ridge Road
Singapore 119074

L Lim, M Med (Ophth), FRCS (Edin)
Registrar

P K Wong, M Med (Ophth), FRCS (Edin), FCOphth
Senior Registrar

Correspondence to: Dr L Lim
Singapore National Eye Centre
11 Third Hospital Avenue
Singapore 168751

Fig 3 – Left superior oblique underaction.

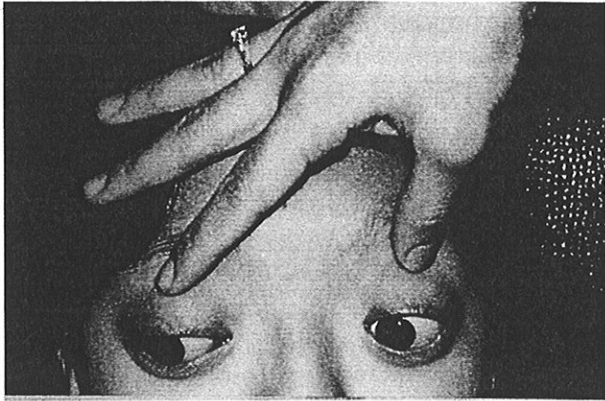
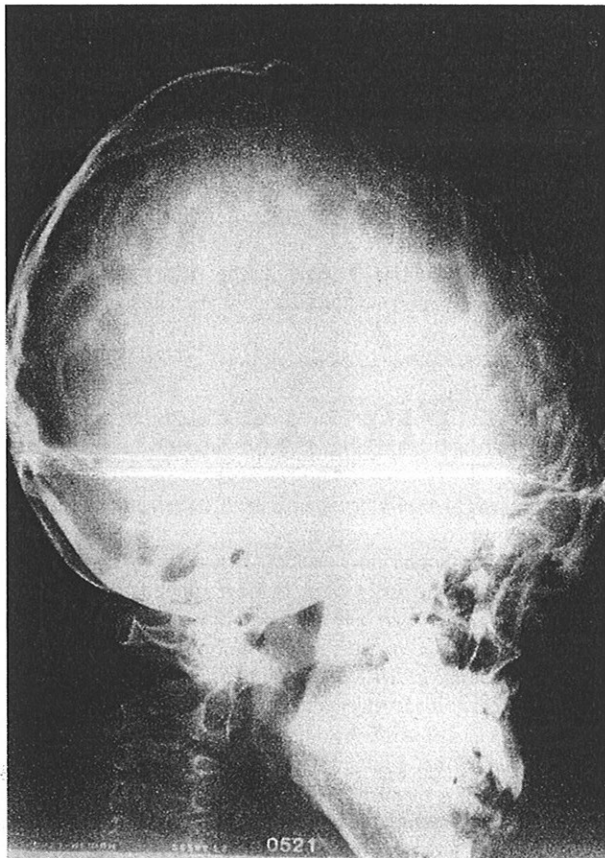


Fig 4 – Turricephaly and prominent convolutional markings.



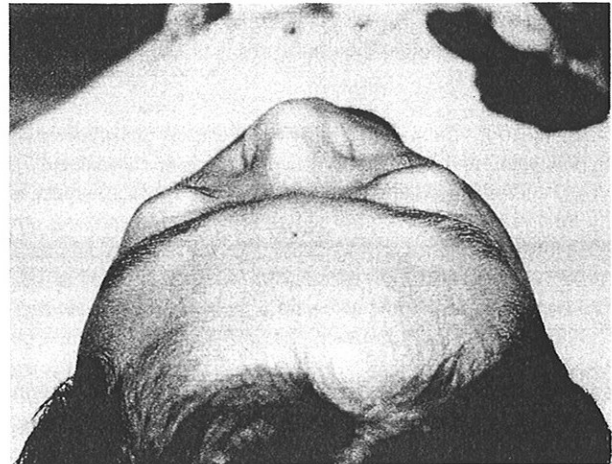
for further assessment. CT-scan of the head showed normal cerebral hemispheres, ventricles and subarachnoid cisterns. There was scalloping of the inner table of the skull vault.

Bilateral permanent lateral tarsorrhaphies were performed in November 1991. She has been well since.

DISCUSSION

Crouzon's disease is a form of craniosynostosis syndrome which is a congenital disorder affecting predominantly the bony development of the cranium and upper face. The pathogenesis of this syndrome is the failure in development of the primitive mesoderm from which skull bones arise⁽¹⁾ and a premature closure of one or more sutures which limits skull growth in the direction perpendicular to the suture (Virchow's law). As a result, more growth occurs in the unrestricted direction to reduce the compressive effect on the growing brain. Intracranial

Fig 5 – Left plagiocephaly



hypertension results when brain growth exceeds skull growth. In this case, there is premature fusion of the coronal and lambdoid sutures restricting skull growth in the anterior-posterior direction with a compensatory growth laterally and vertically resulting in turricephaly (a high and short head).

The ophthalmic features of Crouzon's disease are as follows:

1. Proptosis

This is due to shallow orbits and maxillary hypoplasia. The lowered and relatively posterior origin of the lower lid makes the sclera visible between the inferior limbus and the lid in the primary position. This also results in lagophthalmos and corneal exposure. Measurements of proptosis in studies did not exceed a mean of 20 mm with the Hertel exophthalmometer. Hence the proptosis may be apparent rather than real⁽²⁾. In this case, the readings were 23 mm on the right and 20 mm on the left. The greater reading on the right is probably due to orbital swelling as the above readings were taken soon after the luxation. Thus the measurements in this case would be consistent with previous studies.

Due to the above bony deformities, the globe is liable to spontaneous anterior luxation⁽¹⁾ which occurred in this case. General anaesthesia was required for manual reduction of the luxation. Bilateral permanent tarsorrhaphies were performed to prevent further globe luxation and to decrease the lagophthalmos and corneal exposure.

2. Visual Failure

Optic atrophy is relatively common in the craniosynostosis syndrome⁽²⁾. This may be secondary to raised intracranial pressure and papilloedema⁽³⁾. Other causes include stretching of the optic nerves due to abnormal skull and brain development and narrow optic canals^(3,4). In this case, although there is bilateral disc pallor, the visual acuity, Goldmann fields and contra-sensitivity are normal and the colour vision is only mildly impaired. Therefore, optic atrophy, if present, can only be mild.

3. Strabismus

Divergent deviation is common in Crouzon's disease and explanations include divergent orbital axes, short anterior-posterior orbital dimensions and hypertelorism⁽⁵⁾. Bagolini reported the occurrence of superior oblique palsy in plagiocephaly, that is premature fusion of the coronal sutures on one half of the skull. This is due to the decreased efficiency of the superior oblique muscle which results from the shortness of the orbital roof⁽⁶⁾. In this case, there is left plagiocephaly (Fig 5). The right head tilt, the left inferior oblique muscle overaction,

the limitation in movement of the left eye in adduction and depression and a positive Bielchowsky head tilt test to the left are indicative of a left superior oblique palsy and can be attributed to the shortness of the orbital roof.

4. Cosmesis

The indications for major reconstructive surgery are intracranial hypertension and mental impairment (which are associated⁽⁷⁾), visual complications and cosmesis. The best time for surgery is the first year of life⁽⁷⁾. As this patient is 9 years old and does not have mental impairment, major surgery is not warranted. Lateral tarsorrhaphy is a useful procedure to decrease lagophthalmos and corneal exposure and also would prevent further luxation.

CONCLUSION

Crouzon's disease is a craniostenosis with features of skull deformities; in this case, turricephaly, maxillary hypoplasia, shallow orbits with proptosis. In this case, the globe had spontaneously luxated and was reduced under general anaesthesia. Bilateral permanent tarsorrhaphies were performed to prevent further luxations and to decrease the lagophthalmos and corneal exposure. There was also mild bilateral optic atrophy

and a left superior oblique palsy. Major reconstructive surgery was not indicated as the patient was already 9 years old and had no mental impairment.

REFERENCES

1. Duke-Elder S, ed. Normal and abnormal development. Congenital deformities. In: System of Ophthalmology, Vol. III. Part 2. London: Henry Kimpton, 1964: 1037-57.
2. David Taylor. Craniofacial abnormalities. In: John Brazier, ed. Paediatric Ophthalmology. UK: Blackwell Scientific Publications Inc, 1990: 213-22.
3. Howell SC. The craniostenoses. *Am J Ophthalmol* 1954; 37: 359-79.
4. Blodi FC. Developmental abnormalities of the skull affecting the eye. *Arch Ophthalmol* 1957; 57: 593-610.
5. Dufier JL, Vinurel MC, Renier D, Marchac D. Les complications ophtalmologiques des craniofaciostenoses. A propos de 244 observations. *J Fr Ophthalmol* 1986; 9: 273-80.
6. Bagolini B, Campos E, Chiesi C. Plagiocephaly causing superior oblique deficiency and ocular torticollis. *Arch Ophthalmol* 1982; 100: 1093-6.
7. Marchac D, Renier D. Craniosynostosis. *World J Surgery* 1989 July-August; 13 (4): 358-65.