

# MALPOSITION OF A LONG CENTRAL VENOUS CATHETER IN THE RIGHT INFERIOR THYROID VEIN – A CASE REPORT

K S Ng, B T Teh, E P Y Siew, H K Leong

## ABSTRACT

*This case report hopes to bring to attention the possibility of malposition and ligation of a long central venous catheter in a central venous tributary in the course of major neck surgery. A 49-year-old gentleman underwent total laryngectomy and right radical neck dissection for laryngeal carcinoma. A long central venous catheter was inserted via the right basilic vein. This was subsequently found to have malpositioned into the right inferior thyroid vein and ligated. It required an exploration of the neck wound to remove the ligated catheter.*

**Keywords:** central venous catheter, malposition, laryngectomy, inferior thyroid vein, radical neck dissection.

SINGAPORE MED J 1996; Vol 37: 556-558

## INTRODUCTION

Central venous catheterisation through a peripheral arm vein is an acceptable technique. The most common malposition related to this technique is entrance into the internal jugular vein<sup>(1)</sup>. There has been no previous report of malposition in the inferior thyroid vein. We report a case of malposition of a long central venous catheter in the right inferior thyroid vein. This occurred during the anaesthetic management of a patient undergoing total laryngectomy and radical neck dissection. We discuss the possibility of an early diagnosis and the potential sequel of such a problem.

## CASE REPORT

A 49-year-old male patient was diagnosed to have laryngeal carcinoma in October 1992. He declined total laryngectomy then.

He was next seen at the Emergency Room in December 1992 for acute upper airway obstruction. Control of airway was established by emergency tracheostomy under local anaesthesia. He was subsequently worked up for elective total laryngectomy and right radical neck dissection two days later. As part of his pre-operative monitoring, the Anaesthesiology Registrar inserted a long central venous catheter (16GA 61cm Intracath with wire stylet, Deseret 38-3182-1) via the right basilic vein. Passage of the catheter was smooth and unimpeded. There was a good central venous pressure (CVP) wave-form and good venous return on aspiration. The rest of the general anaesthesia was unremarkable. During surgery, the CVP was read intermittently. Each time, a

good waveform was noted. In between readings, the catheter was connected to a slow continuous infusion of dextrose 5% solution to maintain its patency. No reading was taken after completion of the radical neck dissection.

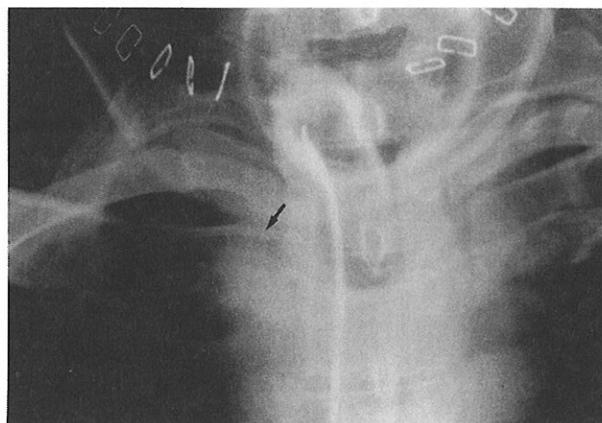
The patient was admitted to the Surgical Intensive Care Unit for observation after the operation. The CVP waveform was noted to be dampened. Aspiration of the catheter was negative. Attempt at flushing cautiously with one millilitre of normal saline met with slight resistance. The path of the catheter, as seen on a plain anterior-posterior chest radiograph (Fig 1), was suspicious for malposition. An attempt at removal of the catheter was unsuccessful; it could not be moved. The radiologist was consulted to help ascertain the position of the catheter. Radioopaque contrast injection through it, followed by a repeat chest radiograph (Fig 2) was done. Contrast was noted to extravasate into neck tissues and the radiologist was of the opinion that the catheter was out of the vein. Further attempts at manipulation and removal under fluoroscopy was unsuccessful.

Exploration of the neck was undertaken to remove the "entrapped" central venous catheter. It was found to be ligated and cut in the right inferior thyroid vein (Fig 3). The rest of the procedure was uneventful. In retrospect, the surgeon recalled having ligated and cut a rather "sclerotic" blood vessel.

## DISCUSSION

One of the common uses of central venous catheterisation is for monitoring filling pressures of the right heart<sup>(2)</sup>. There are many

Fig 1 – X-ray picture depicting path of central venous catheter (arrow).



Department of Anaesthesia  
National University Hospital  
5 Lower Kent Ridge Road  
Singapore 119074

K S Ng, MBBS, M Med, EDIC  
Consultant

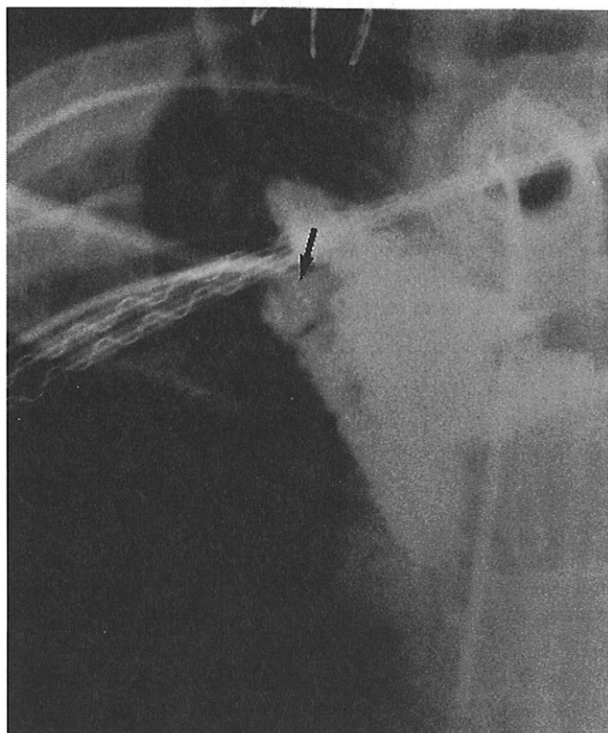B T Teh, MBBS, M Med  
Registrar

E P Y Siew, MBBS, FRCR  
Consultant

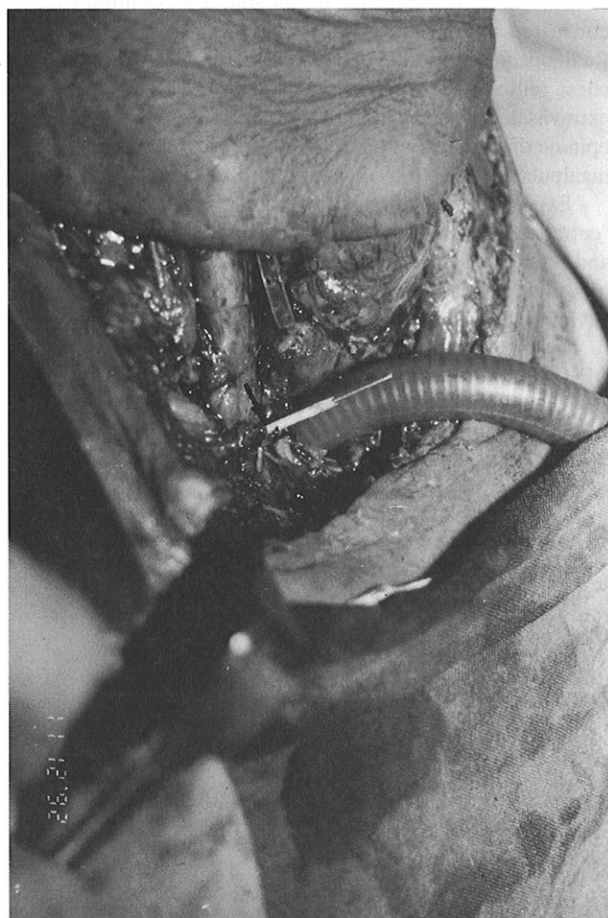H K Leong, MBBS, FRCS, FAMS  
Senior Lecturer and Consultant

Correspondence to: Dr K S Ng  
Department of Anaesthesia  
Toa Payoh Hospital

**Fig 2 – X-ray picture depicting extravasation of contrast injection through central venous catheter (arrow).**



**Fig 3 – Photograph showing transection of right inferior thyroid vein (arrow).**



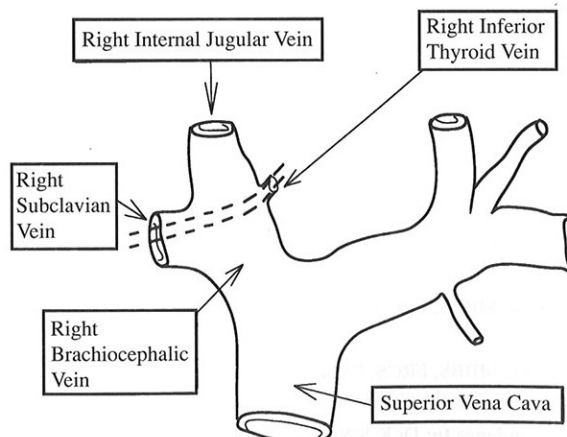
routes for percutaneous insertion of the central venous catheter. A fairly common complication is malposition of the catheter<sup>(3)</sup>. The probability of this occurring can be as high as 20% – 40% in the case of catheters inserted via a peripheral arm vein<sup>(1,4,5)</sup>. The most common site of malposition is at the entrance into the internal jugular vein<sup>(1)</sup>. Neck compression on the side of malposition will impede the flow in the vein. This will result in a rise of 10cm H<sub>2</sub>O or more in the CVP reading. Lumley and Russell reported that neck compression is a useful test for diagnosing this common complication<sup>(6)</sup>.

In this patient, perioperative monitoring of filling pressure was deemed necessary in view of the anticipated long duration of surgery and fairly extensive tissue dissection. The anaesthesiologist chose a long catheter through a peripheral arm vein, to avoid the field of surgery and to minimise the risk of a pneumothorax. On the basis of a good CVP waveform and good venous return, he assumed that the catheter was in a correct position. It has been suggested that clinical criteria may not be reliable enough for ascertaining satisfactory catheter tip position<sup>(1,7)</sup>. There was no radiological verification of correct placement in this patient until the postoperative period.

The course of the right inferior thyroid vein is as follows: "It passes obliquely downwards to the right, across the brachiocephalic artery to open into the right brachiocephalic vein, at its junction with the superior vena cava<sup>(8)</sup>. Anatomically, it appears easy enough for the catheter to advance into the right inferior thyroid vein at the time of insertion or anytime thereafter (Fig 4). The point of entry of the right inferior thyroid vein into the right brachiocephalic vein is intra-thoracic. We postulate that the central venous catheter was close to this point at the time of insertion. This will explain the presence of a CVP waveform then. Subsequently, the catheter must have migrated into the right inferior thyroid vein. Migration of central venous catheter after insertion has previously been reported<sup>(9)</sup>. This can be diagnosed by the dampening of the CVP waveform, since the vein is small and almost totally occluded by the 16GA catheter (Fig 3). The CVP waveform can also become flat if the catheter is ligated. The waveform was not monitored continuously, hence the failure to diagnose the problem until the postoperative period.

The other clue which would have made detection earlier was that the surgeon ligated a rather "sclerotic" vessel during neck dissection. This did not come about as the surgeon did not suspect a problem and also because malposition of central venous catheters causing problems during neck dissection, has rarely been reported previously. McGurk and Thomson reported a case

**Fig 4 – Anatomical sketch illustrating path of central venous catheter into right inferior thyroid vein.**



of catheter malposition in the left internal jugular vein during a left radical neck dissection<sup>(10)</sup>. In that case report, the sectioning of the catheter also went undetected till the time the patient left the operating room.

In this case, we acknowledge that the central venous catheter being inserted on the same side as the radical neck dissection would increase the probability of the catheter entering the field of surgery. It is to be noted, however, that insertion from the contralateral arm would not totally eliminate the probability of this occurrence. Central venous catheters have been reported to traverse the mid-line and enter a contralateral central vein<sup>(1)</sup>.

There were no untoward consequences from the catheter malposition. A potential early and dangerous post-operative problem would have been fluid infusion through the central line, resulting in subcutaneous collection, anatomical distortion and dislodgement of a recently inserted tracheostomy tube. Other potential problems include ineffective drug and fluid administration, and local infection.

Failing to remove the central venous catheter in the Intensive Care Unit, we decided to attempt removal under fluoroscopy. Successful removal would have averted the need for another anaesthesia and surgery. However, considering the subsequent finding that the catheter was ligated and cut in the right inferior thyroid vein, non-operative catheter removal would have resulted in an open venous stump. Ongoing blood loss, haematoma formation, anatomical distortion, dislodgement of fresh tracheostomy tube and infection would have been potential sequelae.

In conclusion, this case report aims to bring to attention the possibility of malposition and ligation of a long central venous catheter in the right inferior thyroid vein or any other central venous tributary. We reiterate the importance of radiological verification of CVP catheter position soon after insertion. Continuous or frequent intra-operative CVP waveform

monitoring is important for detecting catheter malposition or migration. Insertion of the catheter through the contralateral arm may help decrease the likelihood of entering the surgical field. In the setting of radical neck dissection, the potential for ligating and cutting the central venous catheter has to be kept in mind. Considering this case report, one has to be very careful in choosing non-operative removal of an entrapped CVP catheter under such circumstances.

#### REFERENCES

1. Langston CS. The aberrant central venous catheter and its complications. *Radiology* 1971; 100:55.
2. Sykes MK. Venous pressure as a clinical indication of adequacy of transfusion. *Ann R Coll Surg Engl* 1963; 33: 185-97.
3. Lee TL. Malposition of central venous catheter. *J Anesth* 1988; 2: 101-9.
4. Woods D, Lumley J, Russell WJ, Jack RD. The position of central venous catheters inserted through arm veins. A preliminary report. *Anaesth Intens Care* 1974; 1:43-7.
5. Ng WS, Rosen M. Positioning central venous catheters through the basilic vein. A comparison of catheters. *Br J Anaesth* 1973; 45: 1211-4.
6. Lumley J, Russell WJ. Insertion of central venous catheters through arm veins. *Anaesth Intens Care* 1975; 3: 101-4.
7. Johnston AOB, Clark RG. Malpositioning of central venous catheter. *Lancet* 1972; ii: 1395-7.
8. Williams PL, Warwick R, Dyson M, Bannister LH, eds. *Gray's Anatomy*. 37th Ed. Edinburgh London Melbourne and New York: Churchill Livingstone 1989: 808.
9. Vazquez RM, Brodski EG. Primary and secondary malposition of silicone central venous catheters. *Acta Anaesth Scand* 1985; Suppl 81: 22-5.
10. McGurk M, Thomson PJ. A central venous catheter complicating head and neck surgery. *Br J Oral Maxillofac Surg* 1991; 29: 388-91.