

VERRUCOUS CARCINOMA OF MAXILLARY ANTRUM

R Indudharan, P K Das, T Thida

ABSTRACT

Verrucous carcinoma of the paranasal sinuses is a rare malignant tumour. It occurs most frequently in the oral cavity and larynx. We present a case of extensive verrucous carcinoma of the maxillary sinus. This paper discusses the clinical and histological features and modes of treatment. All previous reports of verrucous carcinoma cases of paranasal sinuses are reviewed.

Keywords: verrucous carcinoma, paranasal sinus, radiotherapy

SINGAPORE MED J 1996; Vol 37: 559-561

INTRODUCTION

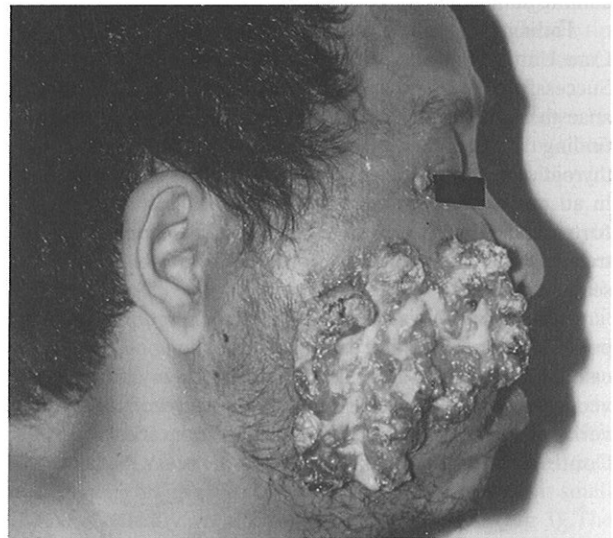
Verrucous carcinoma has always been a subject of controversy regarding clinical presentation, diagnosis and treatment ever since Ackerman described it in 1948⁽¹⁾. The commonest sites of involvement in the head and neck regions have been oral cavity and larynx where it represents 2%-9% and 2% respectively⁽²⁻⁷⁾. So far only 4 cases of verrucous carcinoma have been reported from the maxillary sinus^(4,5,7,8). Maxillary sinus tumours are often diagnosed late, but such an advanced case of verrucous carcinoma as is described here has not been reported before. Despite its highly malignant clinical appearance, the tumour is deceptively benign histologically and cytologically⁽⁹⁾.

CASE REPORT

A 35-year-old male Malay labourer presented with a large fungating ulcerated lesion on the right side of the face with trismus. He was apparently well till 14 months ago when he had right upper tooth ache for which he underwent a tooth extraction from right upper quadrant by a dentist. The tooth socket never healed and remained painful. He consulted a general practitioner and received conservative treatment. Six months later, he noticed a gradually increasing swelling on his right cheek for which he visited several general practitioners who treated him for abscess in the cheek, secondary to infected tooth socket. The patient also sought help from traditional healers; the nature of treatment offered by them is not clear. However, over a period of 5 months, the swelling ulcerated with purulent discharge. The patient continued with local GP management. Three months before admission, he noted difficulty in opening his mouth and one month before presentation, he started to have severe right-sided headache, which resulted in frequent insomnia.

On clinical examination, there was a fungating infected growth of approximately 10 x 10 cm involving the entire right cheek and right lateral orbital margin (Fig 1). The growth was protruding through a small dehiscence in the right gingivolabial

Fig 1 – Verrucous lesion fungating to the right cheek and lateral orbital margin from the right maxillary antrum.



sulcus and through the tooth socket of the second molar of the right upper quadrant. The hard palate appeared infiltrated and had crossed the midline. There was trismus and posterior rhinoscopy revealed right choana filled with mucopus. Movement of the eyes and vision were normal. A firm submandibular lymph node of 2 x 2 cm was palpable on the right side. Examinations of all other systems of the body were normal.

Culture of pus from the mass grew mixed gram negative organisms. X-ray of the paranasal sinuses showed an opaque right maxillary antrum with expansion of sinus and destruction of anterolateral wall. CT scan confirmed the X-ray findings and in addition, revealed destruction of floor and lateral margin of the right orbit and infiltration into the right superior nasal meatus, nasopharynx, infratemporal fossa, hard palate and right pterygopalatine space (Fig 2).

Histopathological examination of biopsy from the growth on the cheek and right gingivolabial sulcus showed a proliferative growth made up of stratified squamous epithelium with infiltration as cords of rete pegs containing keratin plugs into deeper tissue. There was minimum pleomorphism and mitosis with large number of chronic inflammatory cells under the surface layer (Fig 3). The histological diagnosis was verrucous carcinoma.

The tumour was staged as T4 N1 M0. Due to the extensive nature of the tumour, a total extended maxillectomy with possible orbital exenteration and post-operative radiotherapy was suggested. The patient was not willing to go for surgery since a cure could not be assured. Hence a palliative radiotherapy of 3,500 centigray in 12 sittings extended over a period of 2 weeks,

Department of Otorhinolaryngology
School of Medical Sciences
University of Science Malaysia
16150 Kubang Kerian
Kelantan, Malaysia

R Indudharan, DipNB (ORL), MS (ENT)
Lecturer

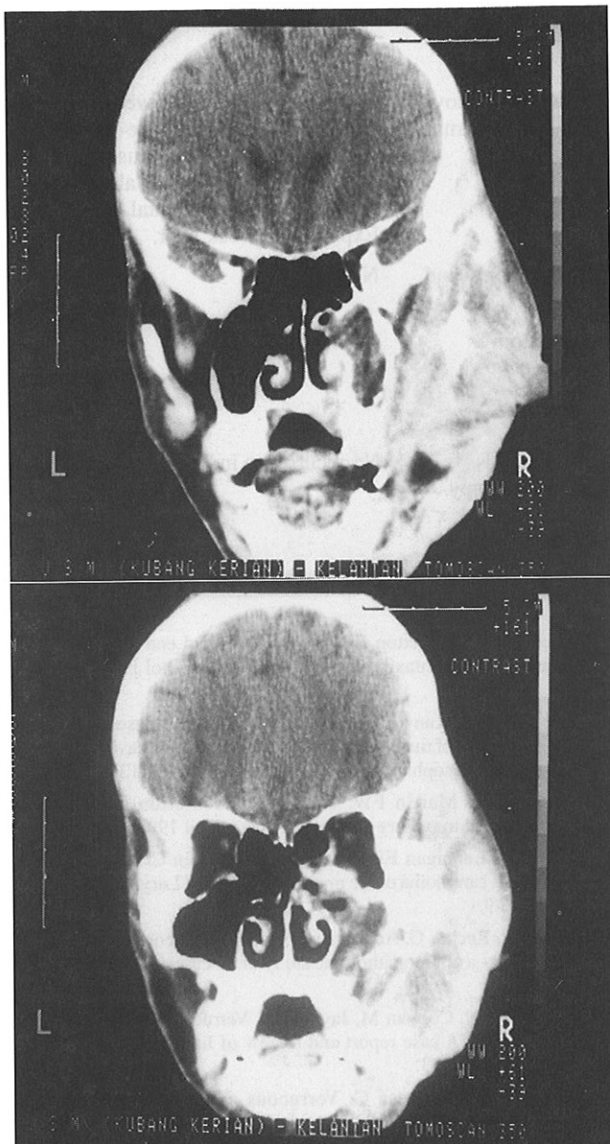
Department of Pathology
School of Medical Science
University of Science Malaysia

P K Das, MD
Professor

T Thida, MBBS
Medical Officer

Correspondence to: Dr R Indudharan

Fig 2 – CT scan showing growth involving the floor and lateral orbital margin, superior nasal meatus, nasopharynx, infratemporal fossa, hard palate and right pterygopalatine fossa.



followed by chemotherapy with 4 cycles of methotrexate 80 mg, every 2 weeks and 6 cycles of bleomycin 15 mg every 2 weeks was given. The response of the tumour to the treatment was dramatic. The growth reduced in size completely and the cheek healed. The submandibular lymph node disappeared and there was relief of headache and trismus. Though further surgery was suggested, the patient was not willing. The patient remains free from recurrence at the time of writing this report, which is twenty-eight months after chemotherapy (Fig 4).

DISCUSSION

Verrucous carcinoma is a highly differentiated, slow growing, locally aggressive tumour, occurring most commonly in the oral cavity and larynx in the head and neck regions. In paranasal sinuses, this tumour has been reported only four times (Table I) from the maxillary antrum^(4,5,7,8) and once from the frontal sinus⁽¹⁰⁾. This is the first time that such a case is reported from South East Asia. The present case reports rapid progression of a generally slow growing tumour. Unless there is close co-operation between the pathologist and the surgeon, and a high degree of suspicion is maintained, the lesion may be reported as benign in spite of

Fig 3 – Nests of well-differentiated squamous carcinoma having a verrucous profile typical of verrucous carcinoma (H&Ex100).

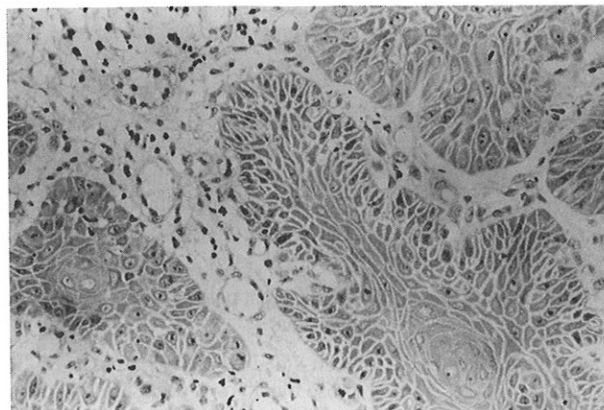
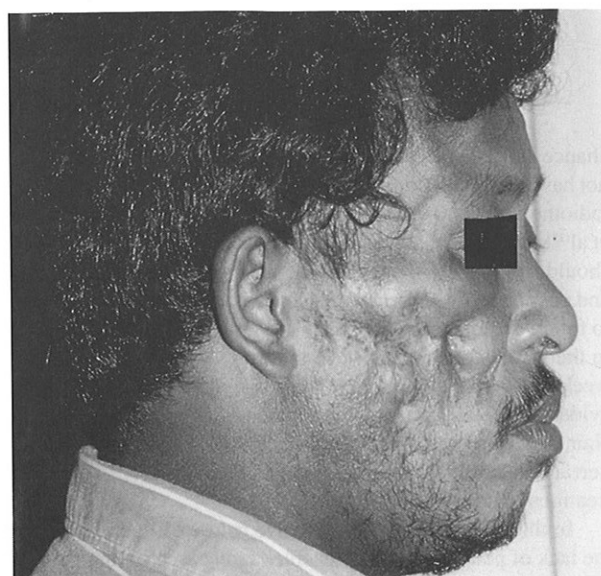

Fig 4 – Post-radio and chemotherapy response of the patient.



the aggressive and destructive clinical picture^(2,9). Ferlito et al Recher⁽⁹⁾ emphasised on the following classic description for diagnosis of verrucous carcinoma:

1. Fungating warty tumour.
2. Thickened club shaped, papillomatous projections which push rather than infiltrate into the underlying tissue.
3. Deeply projecting cleft-like spaces with degenerating keratin and later cystic degeneration of central portion of the filiform projections.
4. High degree of cellular differentiation with absence of features of malignancy.
5. Considerable inflammatory response in invaded tissues.
6. Rare regional lymph node and distant metastasis.

The main histopathological differential diagnosis of verrucous carcinoma is from leukoplakia, papilloma, pseudoepitheliomatous hyperplasia, verrucous hyperplasia and highly differentiated squamous cell carcinoma (grade one)⁽²⁾.

Treatment of verrucous carcinoma remains controversial. Kraus⁽¹¹⁾ et al reported that radiotherapy is ineffective for this tumour. Radiotherapy is reported to cause anaplastic change in the tumour within 6 months, making it more aggressive with

Table I – Verrucous carcinoma of paranasal sinuses (reported cases)

Reported by	Presentation	Treatment	Follow-up
Elliott et al ⁽⁴⁾	Dislodgement of denture with growth in hard palate	Infraorbital maxillectomy followed by radium mould with 4000rads in antrum of 0.5 cm.	No recurrence in 5 years
Newman et al ⁽¹⁰⁾	Blurred vision in right eye for 12 months. Proptosis and fullness below medial aspect of the superior orbital rim left side.	Osteoplastic flap and removal of growth with right external ethmoidectomy.	Right frontal abscess 3 weeks weeks postoperatively. Re-exploration of frontal sinus-extensive tumour in frontal sinus, epidural space and frontal lobe. Expired one week later.
Bacon et al ⁽⁵⁾	Polyp right nasal cavity for 10 years.	Right hemimaxillectomy and ethmoidectomy.	Not reported
Argawal et al ⁽⁷⁾	Left-sided nasal discharge, nose block, post-nasal drip, pain over left cheek - few months.	Total left maxillectomy	Not reported
Present case	Ulcerated lesion right cheek with trismus and right-sided headache.	Radiotherapy 3500 rads followed by chemotherapy. Methotrexate 80 mg/week x 4 cycles and Bleomycin 15 mg/week x 6 cycles	No recurrence in 28 months.

chance of distant metastasis^(12,13). However, Burns et al⁽¹⁴⁾ did not have a single example of anaplastic transformation following radiotherapy in 30 cases of oral verrucous carcinomas. Batsakis et al⁽¹⁵⁾ suggested that the selection of surgery over radiotherapy should be based on the recorded effectiveness of each modality and not on the phenomenon of anaplastic transformation reported to follow radiotherapy. Bar et al⁽¹⁶⁾ reported a case of this tumour in the larynx that responded to radical radiotherapy, though 10 weeks following radiotherapy macroscopic residual tumour was evident and total laryngectomy was considered. At the same time, Nair et al⁽¹⁷⁾ reported radiotherapy results of 52 cases of oral verrucous carcinoma to be comparable with that of surgical treatment of these tumours.

In the present case, the extensive nature of the tumour and the lack of patient consent prevented radical mutilating surgery that may appear to be the recourse for a slow growing, limited tumour. Radical surgery as the first choice of treatment for verrucous carcinoma has to be reviewed based on all the reports of clinical response to radiotherapy of this tumour. This case is reported to highlight the possible role of radiotherapy in verrucous carcinomas of the head and neck region and to bring to light the importance of the high degree of suspicion to be maintained in dental and general practice for diagnosing paranasal sinus tumours.

REFERENCES

- Ackerman LV. Verrucous carcinoma of the oral cavity. *Surgery* 1948; 23: 670-8.
- Schrader M, Laberke HG. Differential diagnosis of verrucous carcinoma in the oral cavity and larynx. *J Laryngol Otol* 1988; 102: 700-3.
- Maw AR, Cullen RJ, Bradfield JW. Verrucous carcinoma of the larynx. *Clin Otolaryngol* 1982; 7: 305-11.
- Elliot GB, Macdougall JA, Elliott JD. Problems of verrucous squamous carcinoma. *Ann Surg* 1973; 177: 21-9.
- Bacon MP, Chevretton EB, Slack RW, MacLeod TIF. Verrucous carcinoma of the maxillary antrum. *J Laryngol Otol* 1989; 103: 415-6.
- Campbell BH, Kun LE, Toohill RJ, Hanson GA, Hanson RM, Malin TC. Diagnosis of malignant lymphomas of the nasal cavity, paranasal sinuses and nasopharynx. *Laryngoscope* 1983; 93: 1276-80.
- Agrawal R, Martin FW. Unusual presentation of verrucous carcinoma of maxillary antrum. *J Otolaryngol* 1992; 21: 371-2.
- Daoud A, Lannigan FJ, Mc Glashan JA, Keen CE, Bowdler DA. Verrucous carcinoma of the maxillary antrum. *J Laryngol Otol* 1991; 105: 696-9.
- Ferlito A, Recher G. Ackerman's tumour (verrucous carcinoma) of the larynx - a clinicopathologic study of 77 cases. *Cancer* 1980; 46: 1617-30.
- Newman AN, Colman M, Jayich SA. Verrucous carcinoma of the frontal sinus: A case report and review of literature. *J Surg Oncol* 1983; 24: 298-303.
- Kraus FT, Perezmesa C. Verrucous carcinoma. Clinical and pathological study of 105 cases involving oral cavity larynx and genitalia. *Cancer* 1966; 19: 26-38.
- Fonts EA, Greenlaw RH, Rush BJ, Roven S. Verrucous squamous cell carcinoma of the oral cavity. *Cancer* 1969; 23: 152-60.
- Biller HF, Bergmann JA. Verrucous carcinoma of the larynx. *Laryngoscope* 1975; 85: 1698-700.
- Burns HP, van Nostrand AW, Palmer JA. Verrucous carcinoma of the oral cavity - management by radiotherapy and surgery. *Can J Surg* 1980; 23: 19-21.
- Batsakis JG, Hybels R, Crissman JD, Rice DH. The pathology of head and neck tumors: verrucous carcinoma, Part 15. *Head Neck Surg* 1982; 5: 29-38.
- Barr GS, Osborne J, Simpson JR. Late response of verrucous carcinoma of the larynx to radiotherapy. *J Laryngol Otol* 1988; 102: 276-9.
- Nair MK, Sankaranarayanan R, Padmanabhan TK, Madhu CS. Oral verrucous carcinoma. Treatment with radiotherapy. *Cancer* 1988; 61: 458-61.