

WILSON'S DISEASE PRESENTING AS HAEMOLYTIC ANAEMIA AND ITS SUCCESSFUL TREATMENT WITH PENICILLAMINE AND ZINC

H L Kong, I L E Yap, Y K Kueh

ABSTRACT

Haemolysis is an uncommon first manifestation of Wilson's disease. We describe a young woman who presented with episodic haemolysis and abnormal liver functions; the diagnosis of Wilson's disease was not made until nine months later. She responded well to a combination of penicillamine and zinc. This report underscores the importance of considering Wilson's disease as a cause in a patient with haemolysis of uncertain aetiology, since the disease can be successfully treated in the early stages. The mechanism of oxidative damage to erythrocytes by the excessive copper and the present role of zinc therapy are also discussed.

Keywords: cirrhosis, coagulopathy, oxidative damage, penicillamine, zinc

SINGAPORE MED J 1996; Vol 37: 670-672

INTRODUCTION

Wilson's disease usually presents with hepatic dysfunction or neuropsychiatric manifestations. The former tends to affect younger individuals, while the latter is more often seen among the older patients. Haemolysis is an unusual presenting problem, and the diagnosis of Wilson's disease is often not considered in this clinical setting. We describe a young woman with Wilson's disease who presented with unconjugated hyperbilirubinaemia from haemolysis. She was successfully treated with penicillamine and oral zinc. The pathogenesis underlying haemolysis in Wilson's disease and the mechanism of the action of zinc in the treatment of this disorder are also discussed.

CASE REPORT

A 25-year-old Chinese woman first presented to another hospital with jaundice, anaemia of 5.7 g/dL, and pedal oedema. Despite investigations, the cause was not immediately apparent and she was discharged with vitamins after blood transfusion. She was later readmitted to the same hospital with similar complaints, and was found to have haemolytic anaemia associated with coagulopathy and hypoalbuminaemia. She was treated with prednisolone, presumably for a possible underlying autoimmune aetiology. Without getting any improvement, the patient defaulted follow-up and sought the help of a Chinese physician instead; diuretics were prescribed. Nine months from the onset of symptoms, and having seen a number of physicians, she continued to be unwell. She then self-referred to our Hospital for another opinion.

Examination revealed a well-nourished young lady with stable vital parameters. The sclerae were icteric but she was neither pale nor febrile. There were no stigmata of chronic liver

disease, but ascites and pitting pedal oedema were prominent. Neurological and mental state examinations were normal. The cornea appeared normal clinically.

The admitting investigations revealed a state of compensated haemolysis: the haemoglobin was 12.6 g/dL, but there were macrocytosis, reticulocytosis (4.8%), elevated level of LDH (898 U/L), and an unconjugated hyperbilirubinaemia (35 µmol/L). In addition, severe liver dysfunction was clearly evident: the serum total protein and albumin levels were significantly reduced at 55 and 19 g/dL respectively, and the prothrombin time was elevated at 28.6 sec. The levels of the transaminases were minimally elevated and the conjugated bilirubin level was normal. Further investigations revealed hypocupraemia (1.7 mg/dL, the normal being 18-45), hypocupraemia (the total serum copper level was 4.2 µmol/L, the normal being 13-24) and an elevated level of 24-hour urinary copper excretion (3.6 µmol/day, the normal being 0.24-0.79); these results were consistent with a diagnosis of Wilson's disease. Slit-lamp examination confirmed the presence of bilateral Kayser-Fleischer rings. CT scan of the abdomen showed a cirrhotic liver which was studded with diffuse, nodular, high-density opacities, representing the excess copper which was deposited in the liver parenchyma; ascites was also noted (Fig 1). Liver biopsy was not attempted because of the presence of significant coagulopathy and ascites. We learned subsequently that her father was suffering from poorly-controlled, early-onset Parkinsonism and that one of her asymptomatic brothers who was screened was also found to have Wilson's disease with biopsy-proven liver cirrhosis.

She was started on D-penicillamine at 150 mg daily initially. As she tolerated the treatment well, the dose was progressively increased to 1.2 gm daily. Oral zinc at 50 mg thrice daily and pyridoxine 25 mg daily were also prescribed. Serial assessment of the liver function tests and coagulation profile revealed a definite, steady improvement with treatment (Fig 2). The 24-hour urinary copper excretion remained elevated, reflecting the ongoing mobilisation and excretion of the excess body store of copper. She became asymptomatic soon after the treatment was started, and required neither diuretic nor blood transfusion thereafter.

DISCUSSION

The diagnosis of Wilson's disease is often delayed. The major difficulty in establishing the diagnosis lies in the fact that this disorder is very uncommon, with a prevalence rate of 1 in 30,000 persons among the Caucasians; its prevalence rate is unknown here.

Department of Medicine
National University Hospital
5 Lower Kent Ridge Road
Singapore 119074

H L Kong, MBBS, MRCP (UK), M Med (Int Med)
Registrar

I L E Yap, MBBS, M Med (Int Med), FAMS
Visiting Consultant Gastroenterologist

Y K Kueh, FRCP (C)
Associate Professor

Correspondence to: Dr H L Kong

Fig 1 – CT scan of the abdomen demonstrating ascites and a cirrhotic liver diffusely studded with high-density nodularities.

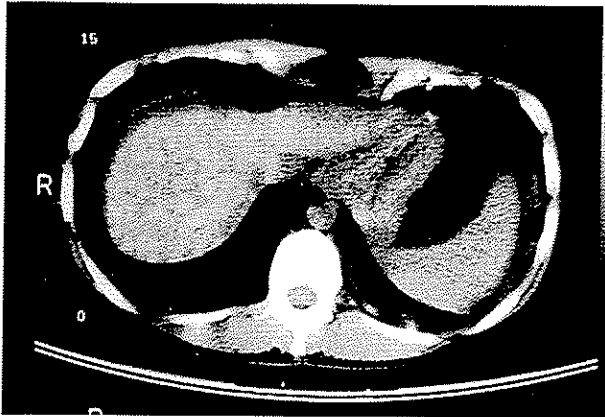
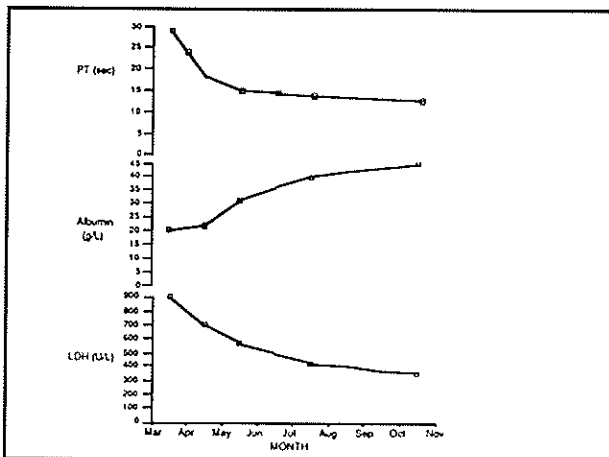


Fig 2 – Amelioration of haemolysis and improvement in liver functions as reflected by the normalisation of LDH and PT / albumin respectively following initiation of penicillamine and zinc treatment in March 94.



It is often the hepatologist or the neurologist who first makes the diagnosis of Wilson's disease, since clinical involvement of either of these two organ systems predominates. Indeed, Wilson originally described the disease in 1912 as a neurological disorder associated with liver cirrhosis⁽¹⁾. In a review of 17 local patients with Wilson's disease, Guan et al reported that all 13 symptomatic patients had either liver or neurological involvement⁽²⁾. However, Wilson's disease can sometimes present atypically, thereby delaying the diagnosis considerably. One such unusual mode of presentation is haemolytic anaemia.

While haemolytic anaemia occurs in up to 17% of patients at some point in time during the natural course of illness, it is uncommon as the initial presentation^(3,4). In the Mayo series of 58 patients reported by Dobyns et al, only one patient presented with haemolytic anaemia⁽⁵⁾. In the local series, Guan et al reported that 2 out of a total of 17 cases presented with haemolysis⁽²⁾. Although haemolysis could precede other symptoms of the disease by several years, it is more typically associated with Wilsonian fulminant hepatic failure. Sjovall and Wallgren first described haemolysis in Wilson's disease in 1934⁽⁶⁾. In 1967, McIntyre et al postulated a sudden flux of copper out of tissues

into the circulation, resulting in haemolysis⁽⁷⁾. The mechanism was thought to be similar to that producing the "enzootic" jaundice in sheep⁽⁸⁾, and to the haemolysis seen in acute copper intoxication in man.

We now know that haemolytic anaemia in Wilson's disease is intravascular, Coombs'-negative and sometimes associated with Heinz bodies⁽⁹⁾. Deiss and Dobyn explained that when the hepatic binding sites become saturated with copper, the excess copper is then released from the liver, probably gradually in the majority of patients. In a minority, however, the release of copper from the liver to the serum is abrupt, resulting in large amounts of copper being taken up by the erythrocytes; the ensuing intravascular haemolysis occurs as a consequence of oxidative damage to the red cells by the high intra-erythrocytic concentration of copper⁽¹⁰⁾.

Chelating agents have been the cornerstones in the treatment of Wilson's disease. The first of these agents was BAL (dimercaprol); it proved to be of limited clinical usefulness because of painful injections. The use of penicillamine as a chelating agent in the treatment of Wilson's disease was first described by Walshe in 1956⁽¹¹⁾. This drug, in a dosage of 1 to 2 gm daily, administered orally in divided doses before meals, has remained the therapeutic "gold standard" despite the common occurrence of adverse effects. Another FDA-approved chelating agent is trientine (short for triethylene tetramine). It serves as an alternative should the patient develop serious penicillamine toxicity. It has less cupriuretic effect than penicillamine, but its clinical effectiveness for maintenance treatment is comparable.

In contrast to chelating agents which lead to cupriuresis, zinc salts result in negative copper balance by cupricopresis. Zinc induces the synthesis of intestinal metallothionein, which is a 61-amino-acid polypeptide with a high cystein content. It acts as an intracellular ligand, binding to copper and other heavy metals^(12,13). Oral administration of zinc thus results in intestinal sequestration of copper and promotes faecal copper excretion. Zinc treatment for Wilson's disease was reported as early as 1961, by Schouwink⁽¹⁴⁾. However, this report went largely unnoticed until the late 70's when other workers, including Hoogenraad et al described the disappearance of Kayser-Fleischer rings and normalisation of liver copper concentrations in patients treated with zinc salts⁽¹⁵⁾. Zinc is often well tolerated, other than the occasional adverse effects of headache, abdominal cramps, gastric irritation and anorexia in patients receiving large doses. Indeed, the absence of major untoward effects in the use of zinc was mentioned more than a century ago by Herpin, who used high doses of zinc to treat epilepsy⁽¹⁶⁾. The excellent therapeutic ratio has led some authorities in Wilson's disease to believe that zinc treatment may eventually replace penicillamine as the long-term maintenance treatment⁽¹⁷⁾.

CONCLUSION

The protean clinical manifestations of Wilson's disease often delay the diagnosis. The spectrum of disorder is considerably more diverse than the earlier concept of the classical triad of basal ganglia disease, liver cirrhosis and Kayser-Fleischer rings. Haemolytic anaemia is a good example of an uncommon first presentation of Wilson's disease; the association between the two is not often thought of. We stress the need to check the liver function tests and the prothrombin time in young patients with haemolytic anaemia so as not to miss an underlying Wilson's disease. Despite its rarity, Wilson's disease should always be excluded, since early treatment before the onset of liver failure is clearly associated with a superior outcome.

REFERENCES

1. Wilson SAK. Progressive lenticular degeneration: a familial nervous disease associated with cirrhosis of the liver. *Brain* 1912; 34: 295-309.
2. Guan R, Yeo PPB, Ng HS, Chan HL, Gwee HM, Tan BY, et al. Wilson's disease revisited in the tropics. *Ann Acad Med Singapore* 1986; 15: 186-93.
3. Strickland GT, Leu ML. Wilson's disease: clinical and laboratory manifestations in 40 patients. *Medicine* 1975; 54: 113-34.
4. Hoagland HC, Goldstein NP. Hematological (cytopenic) manifestations of Wilson's disease (hepatolenticular degeneration). *Mayo Clin Proc* 1978; 53: 498-500.
5. Dobyns WB, Goldstein NP, Gordon H. Clinical spectrum of Wilson's disease (hepatolenticular degeneration). *Mayo Clin Proc* 1979; 54: 35-42.
6. Sjoval E, Wallgren A. Some aspects of hepatolenticular degeneration and its pathogenesis. *Acta Psychiatr Neurol* 1934; 9: 435-64.
7. McIntyre N, Clink HM, Levi AJ. Hemolytic anemia in Wilson's disease. *N Engl J Med* 1967; 276: 439-44.
8. Albiston HE, Bull LB, Dick AT, et al. A preliminary note on the aetiology of enzootic jaundice, toxæmic jaundice, or "yellows" of sheep in Australia. *Aust Vet J* 1940; 16: 233-43.
9. Goldman M, Ali Mahmoud. Wilson's disease presenting as Heinz-body hemolytic anemia. *Can Med Assoc J* 1991; 145: 971-2.
10. Deiss A, Lee GR, Cartwright GE. Hemolytic anemia in Wilson's disease. *Ann Intern Med* 1970; 73: 413-8.
11. Walshe JM. Wilson's disease: a new oral therapy. *Lancet* 1956; 1: 25-6.
12. Prasaad AS, Brewer GJ, Schoomaker EB, Rabbani P. Hypocupremia induced by zinc therapy in adults. *JAMA* 1978; 240: 2166-8.
13. Yuzbasiyan-Gurkan V, Grider A, Nostrant T, Cousins RJ, Brewer GJ. Treatment of Wilson's disease with zinc: X. Intestinal metallothionein induction. *J Lab Clin Med* 1992; 120: 380-6.
14. Schouwink G. De hepato-cerebrale degeneratie (met een onderzoek naar de zinkstofwisseling). Amsterdam: University of Amsterdam 1961. Thesis.
15. Hoogenraad TU, Van den Hamer CJA, Koevoet R, de Ruyter Korver EGWM. Oral zinc in Wilson's disease. *Lancet* 1978; ii: 1262.
16. Herpin T. Du pronostic et du traitement de l'épilepsie. Paris: Bailliere, 1852.
17. Feldman M. Zinc in the treatment of Wilson's disease: how it works. *Gastroenterology* 1993; 104: 1566-75.