

Bizarre ECG In Head Injury Mimicking Ventricular Tachycardia

Y K Loke, V M Lai, M H Tan, A Gunn

ABSTRACT

Bizarre electrocardiographic (ECG) changes were found in an 18-year-old girl who had a subdural haematoma following head trauma. The initial diagnosis was of ventricular tachycardia (VT) and she was treated with intravenous anti-arrhythmic drugs and electrical cardioversion, but to no effect. It was later concluded that the ECG appearances were not of a ventricular arrhythmia but were the result of the intracranial pathology. ECG abnormalities related to head injuries have been reported on many occasions, and our case report illustrates how this can create difficulties for the attending clinicians.

Keywords: head injury, electrocardiographic abnormalities

CASE REPORT

An 18-year-old girl who had sustained a minimal left subdural haematoma following a head injury was transferred to our Intensive Care Unit from another hospital. Initially, she had a Glasgow Coma Scale score of 8/15 but subsequently deteriorated and required endotracheal intubation and assisted ventilation. There was no past history of any cardiac disorder. On arrival in our unit, she was noted to have unreactive dilated pupils bilaterally, pulse rate 79 beats per minute and a blood pressure of 140/80 mmHg. Her Glasgow Coma Scale was 3/15 and she was mechanically ventilated with full cardiorespiratory monitoring. Chest radiographs showed a pneumomediastinum but there were no rib fractures or pneumothorax. Cardiac echocardiogram carried out on 2 occasions showed no gross abnormality or pericardial effusion.

On the following day, abnormalities were noted on the cardiac monitor and an ECG was carried out (Fig 1). The pulse rate had risen to 160 beats per minute but the blood pressure was stable at 103/67 mmHg. Her arterial blood gases were within normal limits and her serum potassium was 4.9 mmol/L. The attending physician felt that ventricular tachycardia was a likely diagnosis and commenced treatment. An initial 100 mg bolus of intravenous lignocaine was given with no effect, and this was followed by a further 50 mg. The patient was then put on continuous lignocaine infusion but despite all this, the ECG pattern persisted.

She was then treated with electrical cardioversion, with the following four shocks administered: 100J,

200J, 360J, 360J. Again, this failed to have any effect on the ECG pattern. Following that, it was thought that the potassium level of 4.9 mmol/L may have been a contributing factor, and this was treated with an insulin-dextrose bolus as well as a bolus of calcium lactate. Reduction of the serum potassium to 3.3 mmol/L was achieved with no bearing on the ECG pattern. As a final resort, intravenous amiodarone 150 mg was given over an hour but this also did not have any effect. No further attempts were then made to treat the ECG pattern.

A repeat ECG at 16 hours after the initial one (Fig 2) showed no significant evolutionary changes, although P waves were now clearly visible in the limb leads, thus enabling us to diagnose this as a sinus tachycardia. This tachycardia persisted with a well maintained blood pressure for a further 4 days before the patient succumbed to her intracranial pathology. Unfortunately, no post-mortem was carried out.

Our final conclusion was that bizarre ST segment and T wave changes coupled with a sinus tachycardia had deceived us into interpreting the ECG as a ventricular tachycardia (VT).

DISCUSSION

The significance of electrocardiographic (ECG) changes in relation to cerebral pathology can be difficult to interpret and may complicate the management of such cases. In 1954 Burch *et al*⁽¹⁾ described T wave and Q-T interval changes in a group of patients with cerebrovascular accidents. Subsequently, in 1960, Cropp and Manning's paper⁽²⁾ highlighted a case of subarachnoid haemorrhage where neurosurgical intervention was deferred due to the finding of ECG changes suggesting recent myocardial infarction. The patient subsequently died and at post-mortem, the heart and coronary arteries were found to be normal. The same paper further reviewed several similar cases of subarachnoid haemorrhage which developed ECG changes but had no cardiac pathology detected at autopsy. It was suggested by the authors that intracerebral damage at a particular site could lead to the development of abnormalities in the ECG. A recent review concluded that changes in the ST segment, T wave and U wave as well as prolongation of the Q-T interval were the commoner abnormalities found in relation to various types of intracranial pathology⁽³⁾.

Medical Unit
Hospital Kuala Terengganu
Jln Sultan Mahmud
20400 Kuala Terengganu
Terengganu, Malaysia

Y K Loke, MRCP
Clinical Specialist

V M Lai, M Med
Clinical Specialist

M H Tan, FRCP
Senior Consultant

Surgical Unit
Hospital Kuala Terengganu

A Gunn, FRCS
Clinical Specialist

Correspondence to:
Dr Y K Loke

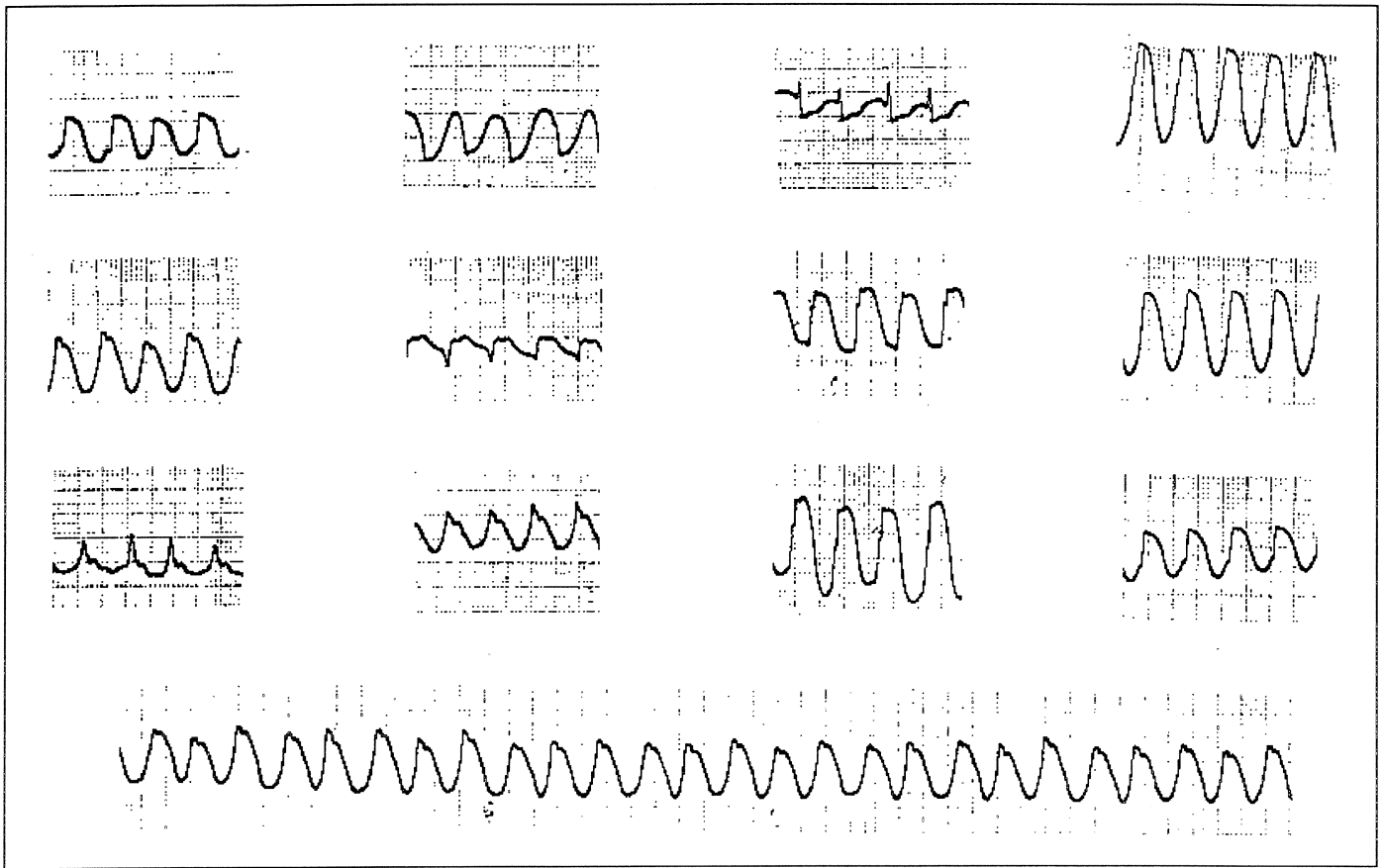


Fig 1 - Initial 12 lead ECG




Fig 2 - ECG repeated 16 hours later

However, one group who studied acute head injury patients suggested that the intracerebral injury alone could cause focal myocardial necrosis (by the intense sympathetic discharge from the nervous system), and that the evolving ECG changes could be due to this secondary cardiac damage⁽⁴⁾. In some instances, it also remains unclear whether a primary cardiac event was the cause of the intracerebral problem.

Our case report serves to highlight that the ECG changes related to intracranial pathology may not only mimic myocardial ischaemia, but can also take the appearance of a ventricular arrhythmia. We hope that the wider awareness of such ECG patterns will help clinicians in providing better care to this group of patients.

ACKNOWLEDGEMENTS

The authors wish to thank the Director General of the Ministry of Health, Malaysia for his kind permission in allowing the publication of this case.

REFERENCES

1. Burch GE, Meyers R, Abildskov JA. A new electrocardiographic pattern observed in cerebrovascular accidents. *Circulation* 1954; 9:719-23.
2. Cropp GJ, Manning GW. Electrocardiographic changes simulating myocardial ischaemia and infarction associated with spontaneous intracranial haemorrhage. *Circulation* 1960; 11: 25-38.
3. Oppenheimer SM, Cechetto DF, Hachinski VC. Cerebrogenic cardiac arrhythmias. *Arch Neurol* 1990; 47:513.
4. McLeod AA, Neil-Dwyer G, Meyer CHA, Richardson PL, Cruickshank J, Bartlett J. Cardiac sequelae of acute head injury. *Br Heart J* 1982; 47:221.

College of Family Physicians Singapore

6th Scientific Conference & 7th Meditech Exhibition

Date

24th - 25th May 1997

Venue

College of Medicine Building
16 College Road, Singapore 169854

Theme

Excellence in Family Medicine

REGISTRATION

Fees (Singapore Dollars)

Includes

- admission to all seminars, workshops and symposiums
- 2 teas, a lunch and a dinner at the conference venue
- 25th Anniversary 10 Course Chinese Dinner at the Shangri-La Hotel

Members of the College of Family Physicians Singapore	: S\$ 150 per registrant
Medical Officers in the Singapore Armed Forces & Ministry of Health	: S\$ 180 per registrant
Non-Members & Overseas Delegates	: S\$ 200 per registrant
For Spouse/partners & non-registrants, the 25th Anniversary Dinner is available at	: S\$ 70 per dinner

A free souvenir Stereophonic Stethoscope (worth S\$285 and yet to be launched in Singapore) will be given to each pre-registered delegate. Due to space constraints, registration is limited to 400 delegates.

On-site registration is available at S\$200 per registrant, but DOES NOT include the Shangri-La dinner and the stethoscope is subject to availability.

CLOSING DATE 10 MAY 1997

6 CME points will be accredited

ENQUIRIES : TEL 223 0606