

# The Spectrum of Cutaneous and Internal Malignancies in Chronic Arsenic Toxicity

S T Wong, H L Chan, S K Teo

## ABSTRACT

We report 3 patients of chronic arsenic poisoning with characteristic skin changes. All 3 patients had a past history of asthma and were treated with Traditional Chinese Medication. We believe that the Chinese medications were the source of arsenic poisoning. Two of the 3 patients also had internal malignancy. The association of arsenic with internal malignancy is reviewed.

**Keywords:** chronic arsenic poisoning, Traditional Chinese Medication, internal malignancies

## INTRODUCTION

For centuries, medicinal arsenic has been used extensively in the treatment of various ills eg. anaemia, epilepsy, asthma, psoriasis, syphilis and others. With the introduction of newer and more effective drugs, chronic arsenic poisoning is rarely seen nowadays. However, there are still patients who are able to obtain arsenic-containing medications surreptitiously through illegal sources.

### Case 1

A 48-year-old Chinese woman, a non-smoker with a history of asthma and schizophrenia, presented with complaints of shortness of breath of one month's duration. Her family members also gave a history that the patient was on follow-up for years with a private dermatologist for chronic arsenic poisoning with some skin problems. Clinical examinations revealed clubbing of the fingers and toes and a right-sided pleural effusion. There was no evidence of heart or renal failure. Multiple warty keratotic papules were seen distributed over both the palms and the fingers (Fig 1) with generalised hyperpigmentation and "raindrop" hypomelanosis over the left thigh. There were scars on her right palm from a previous excision of squamous cell carcinoma and basal cell carcinoma. Subsequent computer tomography (CT) scan of the thorax revealed a hypodense heterogenous mass in the right lower lobe of the lung with a small peripheral effusion. A CT guided percutaneous fine needle aspiration biopsy revealed malignant cells compatible with undifferentiated small cell carcinoma of the lung. She was subsequently staged and treated with chemotherapy (etoposide). She defaulted follow-up after receiving 3 cycles of treatment.

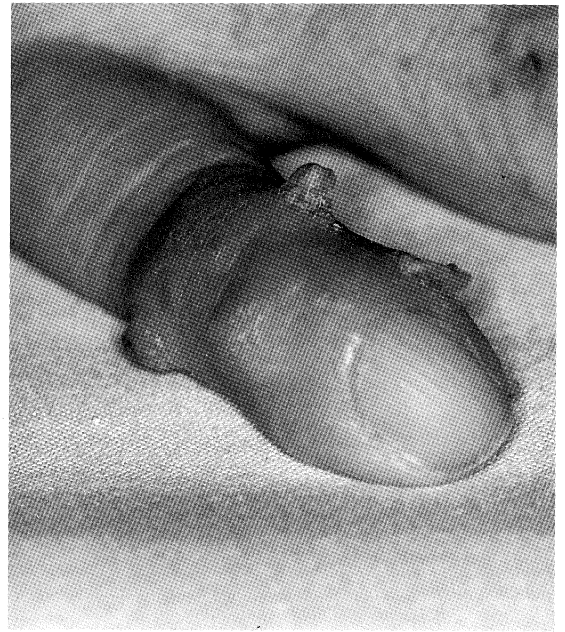

Fig 1 – Right hand: Firm keratotic papules on little finger (patient 1)

While she was in the hospital, her family members gave a history of the patient taking Traditional Chinese Medications for her asthma from age four years. She stopped taking the medications after it was banned by the government in her late twenties. She started having some skin problems at about the age of ten and she developed squamous cell carcinoma on her right palm, basal cell carcinoma on her right index finger and squamous cell carcinoma in-situ on her right little finger when she was forty. These were excised by the plastic surgeon and she was followed up thereafter by the dermatologist. Her urine arsenic level assayed during her present admission was  $4.13\mu\text{g}/100\text{mL}$  (normal range:  $< 30\mu\text{g}/100\text{mL}$ ).

### Case 2

A 50-year-old Chinese man with a history of asthma had a squamous cell carcinoma on his right calf excised two years ago. He presented with one week history of jaundice, tea-coloured urine and abdominal swelling. He used to smoke 40 cigarettes per day for more than 30 years, but stopped 4 years ago. Clinical examination revealed a very sick and hyperpigmented man with severe jaundice and gross ascites. Multiple liver nodules were seen on ultrasound scan of the liver. The hepatitis B antigen was negative and

Department of Medicine  
National University Hospital  
5 Lower Kent Ridge Road  
Singapore 119074

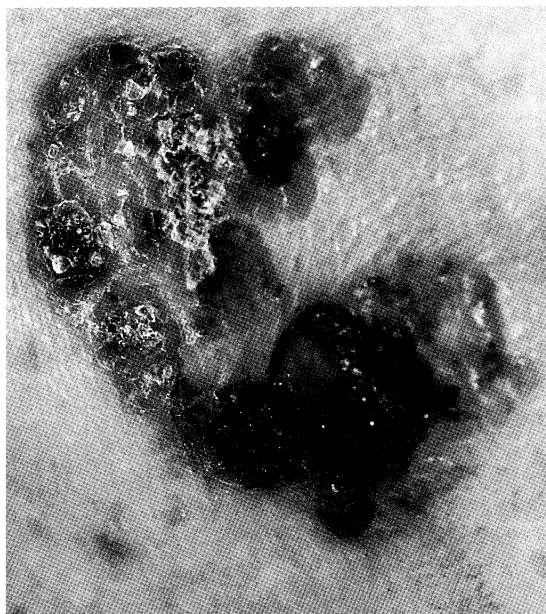
ST Wong, MBBS, MRCP  
Lecturer

H L Chan, MBBS,  
FRCP (Edin)  
Professor and Head

Department of Medicine  
Alexandra Hospital  
378 Alexandra Road  
Singapore 159964

S K Teo, FRCP (Edin), FAMS  
Consultant Physician

Correspondence to:  
Dr ST Wong



**Fig 2** – Left thigh: Bowen's disease (Biopsy proven in patient 2)

alphafetoprotein was  $1.1 \mu\text{g/L}$ . Chest X-rays revealed a 1.5 cm nodule in the right lung. Examination of the skin showed palmar and plantar keratoderma. In addition, there were multiple scattered warty lesions on both lower limbs and the back. There was a lesion characteristic of Bowen's disease (Fig 2) at the back of the left thigh. Upon direct questioning, the patient gave a history of taking *Sin Lak* pills over a 4–5 year period for the control of his asthmatic attacks 20 years ago. A diagnosis of metastatic liver disease with unknown primary was made. The possibility of primary angiosarcoma of the liver was also considered in view of the cutaneous evidence of chronic arsenic poisoning. A liver biopsy however, could not be performed because of severe coagulopathy. He deteriorated into hepatic encephalopathy shortly after admission. Despite aggressive medical treatment, he died 8 days after hospitalisation. His urine arsenic level was  $3.09 \mu\text{g}/100\text{mL}$ .

### Case 3

A 48-year-old Chinese store-keeper, with a past history of asthma, presented with 2 localised lesions of about a year's duration. The lesions were in the left hand and right gluteal region. It started small and progressively increased in size and eventually ulcerated. Clinical examination revealed a 3.2 by 3.3 cm indurated ulcer with everted edge at the junction between fourth and fifth finger of the left hand (Fig 3). The second lesion was a 6.3 by 7.0 cm fungating growth in the right gluteal region. There was no palpable regional lymphadenopathy. Again, there were multiple keratotic lesions scattered over the back of the trunk and the arms. Punch and subsequent excisional biopsies of the two ulcerative lesions confirmed poorly differentiated primary squamous cell carcinoma. Biopsies of the lesions on the back revealed keratosis with varying degree of cellular atypia ranging from mild to severe. Nine months after the excision, he was discovered to have palpable left axillary lymphadenopathy and excisional biopsy of the nodes revealed metastatic squamous cell

carcinoma. CT thorax and abdomen revealed no other lymph node involvement. He is currently on follow-up by the oncologist. As with the second patient, this patient gave a history of taking *Sin Lak* pills 20 years ago for his asthmatic problem. His urine arsenic level was  $3.69 \mu\text{g}/100 \text{mL}$ .

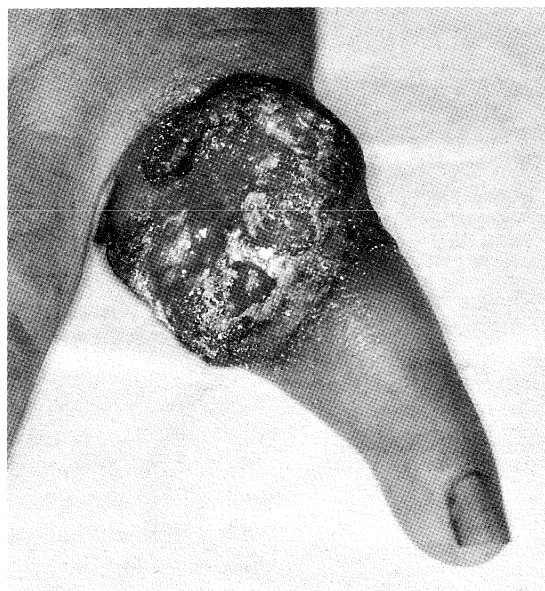### DISCUSSION

Between 1972 and 1973, 74 cases of arsenic poisoning by Chinese herbal medications were discovered in Singapore<sup>(1)</sup>. A total of 47 cases were due to ingestion of a popular *Sin Lak* anti-asthmatic pills that contained 12,000 ppm of inorganic arsenic sulphide manufactured by a Chinese *sinseh*. Together with *Sin Lak* pills, 28 other brands of Chinese herbal preparation containing high concentrations of inorganic arsenic were also discovered.

Arsenic poisoning was diagnosed based on the following criteria<sup>(2)</sup>:

- (a) a history of having exposed to some known/unknown preparations of Chinese herbal product
- (b) a picture of acute or chronic form of arsenic poisoning
- (c) biochemical evidence of the presence of arsenic in the tissue [ie. above 0.02 ppm ( $2 \mu\text{g}/100 \text{mL}$ ) in the blood, 0.01 ppm ( $1 \mu\text{g}/100 \text{mL}$ ) in the urine and/or 1.0 ppm in the hair and nails]

Based on the same criteria, the 3 patients reported here appear to be victims of chronic arsenic poisoning (Table I). Except for case 1 who was diagnosed to have arsenic poisoning 8 years ago, the other 2 cases have escaped detection for years and the diagnosis of arsenic poisoning was not made until they presented with advanced neoplastic disease. As can be seen in case 3, he was treated as a case of "infected warts" over his left hand when he first presented to a doctor. Even when the lesions had progressed to a fungating non-healing ulcer, the possibility of chronic arsenic poisoning was not suspected.



**Fig 3** – Left hand: Squamous cell carcinoma ulcerated with an everted edge (patient 3)

**Table I – Chronic arsenic toxicity: summary of patient characteristics**

<b>Patients</b>	<b>1</b>	<b>2</b>	<b>3</b>
History of asthma	Yes	Yes	Yes
Traditional Chinese Medication (TCM)	Yes (unknown preparation)	Sin Lak pills	Sin Lak pills
Estimated duration of TCM treatment (years)	20 – 30	4 – 5	2 – 3
Hyperpigmentation	Yes	Yes	No
“Arsenic” keratosis	Yes	Yes	Yes
Skin cancers	Yes	Yes	Yes (multiple)
Urine arsenic ( $\mu\text{g}/100\text{mL}$ )	4.13	3.09	3.69
Visceral neoplasm	Ca lung	Liver neoplasm (metastatic or angiosarcoma)	Nil

Ca – cancer

The diagnosis of chronic arsenic poisoning is not difficult provided one is familiar with the cutaneous manifestations and its association with some Traditional Chinese Medications exposure in the local context. Hyperpigmentation, keratotic papules and skin cancers are the most common manifestations of chronic arsenic poisoning<sup>(3)</sup>.

Hyperpigmentation is reported to be present in 89.7% of people in whom skin cancer developed after arsenic exposure. It is characteristically a diffused dark brown pigmentation, either generalised or confined to the face, trunk and extremities. The classical “raindrop” melanosis appears as multiple small rounded hypopigmented macules scattered within the hyperpigmented areas.

Keratotic papules are the second most common skin sign of chronic arsenic poisoning. Although typically found on the palms and soles, arsenic keratosis can also be found elsewhere. Although there are reports of cellular atypia at the base of these keratosis and their potential to evolve into squamous cell carcinoma, prophylactic removal of these keratosis has not been recommended.

Skin cancers are the most common arsenic-induced neoplasms. All three of our patients had skin cancers. They include Bowen’s disease, squamous cell carcinoma and basal cell carcinoma. Bowen’s disease is the most common form of skin cancer induced by arsenic. It is frequently seen in sun-protected areas. Basal cell carcinomas are frequently multiple and found in sun-protected areas as well. Squamous cell carcinoma, which can occur after a latency of 10 years, may develop de novo or may be the result of invasion at a site of previous Bowen’s disease. Early diagnosis and surgical intervention are important and have significant survival benefit for the patient.

As far back as 1879, we knew there might be an association between inhaled arsenic and lung cancer but the association of ingested arsenic and visceral cancer is much less clear. More recent studies in Taiwan and Japan have shown that there is indeed an association between ingested arsenic and internal cancers. Chiou et al<sup>(4)</sup> reported a dose-response

relationship between long-term arsenic exposure from drinking high-arsenic artesian well water and the incidence of lung cancer, bladder cancer, and cancers of all sites combined. Tsuda et al<sup>(5)</sup> reported that exposure to ingested arsenic significantly increased lung cancer deaths and all cancer deaths.

These 3 patients serve to highlight the skin signs of chronic arsenic poisoning and its association with skin and internal neoplasms. Hyperpigmentation, keratoses or even Bowen’s disease may easily be overlooked if we are not aware of their significance. Arsenical skin changes after exposure are also useful predictors of lung cancer development<sup>(5)</sup>. Recognising sign of chronic arsenic poisoning is not only important for long-term follow-up, it is also important for identifying route of exposure. *Sin Lak* pills have been banned, but one cannot be certain that other preparations with high arsenic content have been completely removed from the reach of the public, judging by the continuing popularity of Traditional Chinese Medication. With newly industrialising countries and expanding use of arsenic in industries like carpentry, electroplating and semi-conductor industries<sup>(6)</sup>, the possibility of chronic arsenic poisoning remains.

#### REFERENCES

1. Tay CH. Cutaneous manifestations of arsenic poisoning due to certain Chinese herbal medicine. *Aust J Derm* 1974; 15:121-31.
2. Tay CH, Seah CS. Arsenic poisoning from anti-asthmatic herbal preparations. *Med J Aust* 1975; 2:425-8.
3. Alain G, Tonsignant J, Rozenfarb E. Chronic arsenic toxicity. *Int J Dermatol* 1993; 32:899-901.
4. Chiou HY, Hsueh YM, Liaw KF, Horng SF, Chiang MH, Pu YS, et al. Incidence of internal cancers and ingested inorganic arsenic: a seven year follow-up study in Taiwan. *Cancer Res* 1995; 55(6):1296-300.
5. Tsuda T, Babazono A, Yamamoto E, Kurumatani N, Mino Y, Ogawa T, et al. Ingested arsenic and internal cancer: a historical cohort study followed for 33 years. *Am J Epidemiol* 1995; 141(3):198-209.
6. Maloney ME. Arsenic in Dermatology. *Derm Surg* 1996; 22:301-4.